



## PATIENT

Lacey Chunka

## SPECIES

Feline

## BREED

Domestic Shorthair

## SEX

Spayed female

## AGE

14 years

## WEIGHT

8 lbs

## INTERPRETED BY

Eric Lindquist, DMV  
DABVP, Cert. IVUSS

## IMAGING PERFORMED BY

Heather

## HOSPITAL NAME

Animal Care Center of  
Flanders

## REFERRING VET

Dr. Hallihan

## INVOICE

74956

## DATE

4/28/26

## PRESENTING CLINICAL SIGNS

History: new heart murmur - possible arrhythmia, may need surgery, grade 2/6 systolic murmur (new), possible arrhythmia ausculted  
methimazole transdermal 50mg/ml - 0.05 bid alternating ears  
Abnormal PE/Chem/CBC/UA Results: t4 was 6.1 pre-tx 3/22/26, now 3.2

## ULTRASONOGRAPHIC EXAMINATION OF THE HEART

The echocardiogram in this patient demonstrated normal **left atrial** size based on 3 separate LA measurements. The **mitral** valve was mildly thickened with mild mitral insufficiency. The **left ventricle** presented normal thicknesses with linear contour and was not dilated nor restricted. The **myocardium** presented normal echogenicity without subjective evidence of significant fibrotic or ischemic disease. **Contractility** of the ventricular walls was adequate and in normal range for this patient evidenced by the fractional shortening measurement and subjective evaluation of the different regions and angles of the myocardium. The **left ventricular outflow** tract demonstrated normal laminar flow and subjective structural integrity. The **right atrium** and auricle revealed normal size, structure and content. No evidence of masses was noted or chamber overload. **Tricuspid** insufficiency was noted and measured 1.5 m/sec. The **right ventricle** was of normal size (1/3 diameter of LV), chordae structure, myocardial echogenicity and thickness. **Pulmonic** tract assessment revealed normal valve structure, laminar flow, and diameter (approx. 1:1 pa/ao ratio). No visible **pericardial** or free pleura fluid was noted or extra cardiac pathology in the visible planes. The cranial **mediastinum and pericardial regions** were free of masses in the visible window.

FELINE CARDIAC PARAMETERS	BODY WEIGHT	HR (BPM)	IVSd (cm)	LVIDd (cm)	LVWd (cm)	FS (%)	EF (%)
NORMAL PARAMETER	-----	150-240	0.3-0.6	1.0-2.1	0.25-0.6	35-67	80-100
PATIENT	8 lbs	220	0.64	1.4	0.45	50	-
FELINE CARDIAC PARAMETERS	LA/AO (M-mode)	LA/AO HEART BASE (Sisson)	LAD LA MAX 4 Chamber	LVOT VEL. (m/s)	RVOT VEL. (m/s)	IVRT (m/)	
NORMAL PARAMETER	<1.5	1.6	0.7-1.7	<1.6	<1.3	40-60	
PATIENT	1.3	1.2	1.44	NM	1.1	NM	
Adapted from June Boon, Veterinary Echocardiography, 1998 Sisson D et al. JVIM 1991; 5: 232, Jacobs et al. Am J Vet Res 1985; 46:1705							

## ULTRASONOGRAPHIC FINDINGS

Minor mitral and tricuspid insufficiency.



## PATIENT

Lacey Chunka

## SPECIES

Feline

## BREED

Domestic Shorthair

## SEX

Spayed female

## AGE

14 years

## WEIGHT

8 lbs

## INTERPRETED BY

Eric Lindquist, DMV  
DABVP, Cert. IVUSS

## IMAGING PERFORMED BY

Heather

## HOSPITAL NAME

Animal Care Center of  
Flanders

## REFERRING VET

Dr. Hallihan

## INVOICE

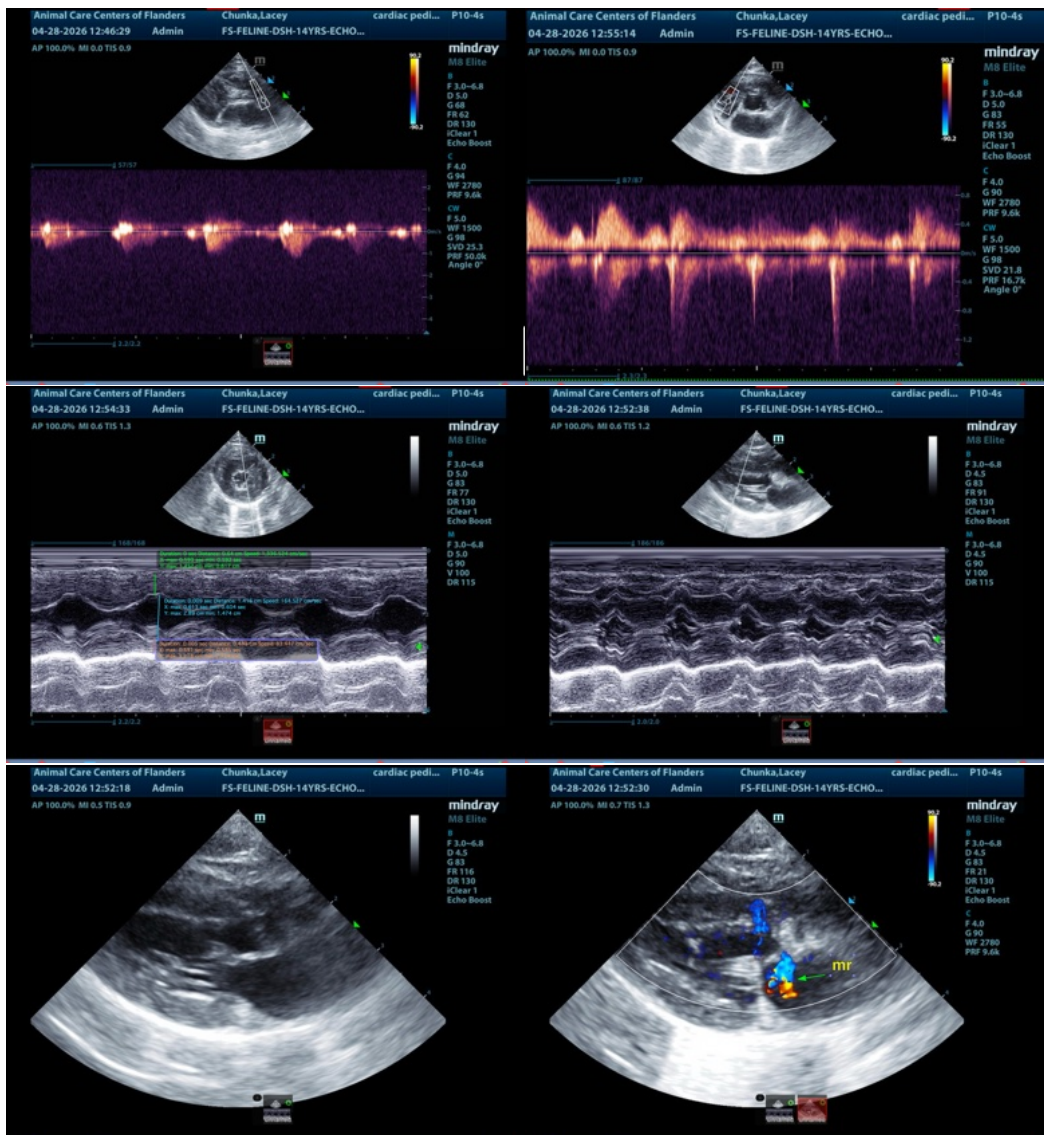
74956

## DATE

4/28/26

## INTERPRETATION OF THE FINDINGS & FURTHER RECOMMENDATIONS

Blood pressure measurements are recommended in this patient. No overt contraindication to anesthetic procedure.





## PATIENT

Lacey Chunka

## SPECIES

Feline

## BREED

Domestic Shorthair

## SEX

Spayed female

## AGE

14 years

## WEIGHT

8 lbs

## INTERPRETED BY

Eric Lindquist, DMV  
DABVP, Cert. IVUSS

## IMAGING PERFORMED BY

Heather

## HOSPITAL NAME

Animal Care Center of  
Flanders

## REFERRING VET

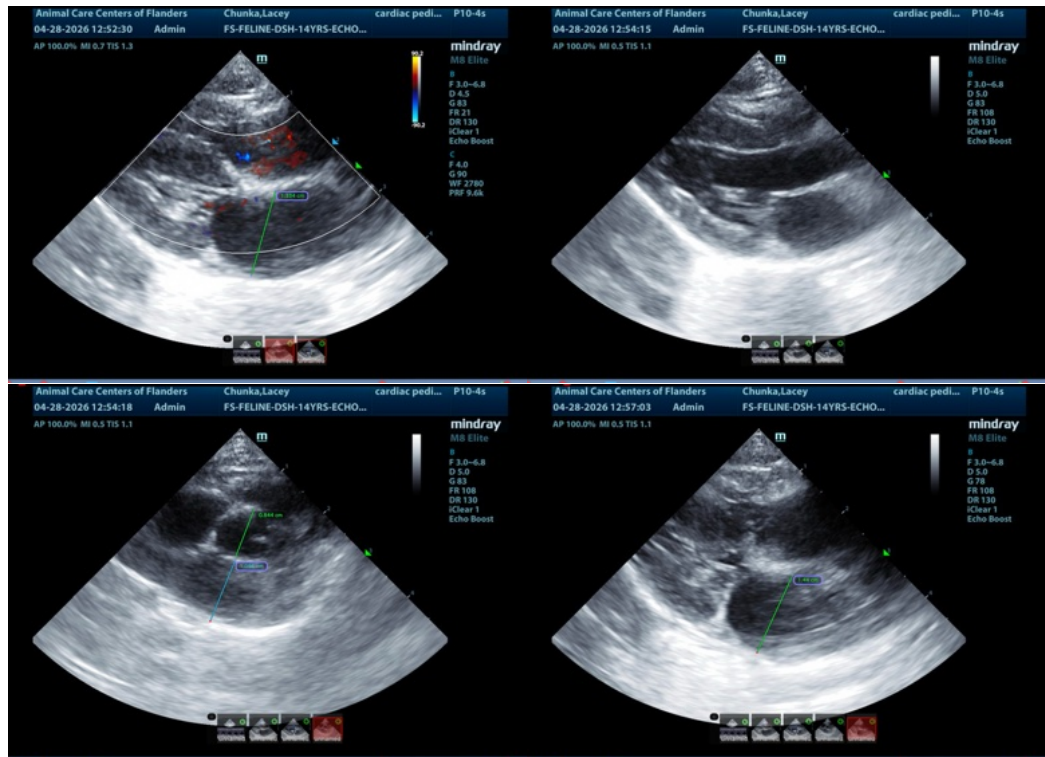
Dr. Hallihan

## INVOICE

74956

## DATE

4/28/26



The information and recommendations provided are based on the images presented by the referring veterinarian/sonographer. No evaluation can be communicated regarding pathology that was not visible in the image/video clips provided.

Thank you for this referral. If the clinical or image interpretation does not parallel your findings or if I can be of any further assistance please contact me.

Eric Lindquist, DMV, DABVP (CFM), Cert. IVUSS, CEO of SonoPath.com

[info@SonoPath.com](mailto:info@SonoPath.com)