



PATIENT

Kooky Khan

SPECIES

Feline

BREED

DSH

SEX

Spayed Female

AGE

13 Years

WEIGHT

10.3 lbs

INTERPRETED BY

Eric Lindquist, DMV,
DABVP (CFM), Cert.
IVUSS

IMAGING PERFORMED BY

Kerri Becker

HOSPITAL NAME

Packanack Animal
Hospital

REFERRING VET

Dr. Gonzaga

INVOICE

74781

DATE

4/28/26

PRESENTING CLINICAL SIGNS

Chronic inappropriate urination. suspected DJD. Solensia inj.

Abnormal PE/Chem/CBC/UA Results: gluc-256 usg-1.053

ULTRASONOGRAPHIC EXAMINATION OF THE ABDOMEN

Urinary System

The **urinary bladder**, trigone, and pelvic urethra presented normal thicknesses and normal tone. The ureters were not visible which is normal. No uroliths or sediment were visualized and anechoic urine was present. No evidence of inflammatory or neoplastic changes were noted. Ureteral papillae were normal.

The **kidneys** revealed largely normal size and structure, corticomedullary definition and ratio (cortex 1/3 of medulla) were essentially maintained with some age-related loss of curvilinear patterns regarding the capsule and C/M junction. The cortices presented largely uniform texture with some increased echogenicity expected for his age patient. Medullary structure differed distinctly from that of the cortex and no evidence of pelvic dilation was present. Slight mineralizations noted, non-obstructive. Left kidney measured 3.6 cm. Right kidney measured 3.9 cm.

Adrenal Glands

Both **adrenal glands** were visualized and recognized as having normal shape, size, position and echogenicity for this breed. The phrenic vasculature, glandular echogenicity and detail were unremarkable. Capsule, cortex, and medullary definition were normal for this age patient. Right measured 0.34 cm. Left measured 0.41 cm.

Spleen

The **spleen** presented a smooth homogeneous parenchyma hyperechoic to liver and renal cortical parenchyma. The capsule was smooth without noticeable expansion or deviation from within the spleen or adjacent pathology. The splenic vasculature demonstrated normal volume without signs of congestion or thrombosis. No sonographic evidence of acute or chronic inflammatory, neoplastic, or infarctual changes were noted.

Liver

The **liver** images submitted revealed subjectively normal liver size, contour, and structure. Parenchymal echogenicity was naturally coarse and hypoechoic to the spleen. Vascular and biliary tracts were of normal volume with no evidence of congestion. The gallbladder presented acceptably thin walls with primarily anechoic content. The cystic and common bile ducts were normal. No pathological hepatic lymphadenopathy was evident. No overt structural evidence of inflammatory, infiltrative or regenerative pathology was evident.

Gastrointestinal

The **stomach** revealed progressively shadowing luminal material, most consistent with hairball accumulation. Some transit of chyme into the small intestine is occurring.



PATIENT

Kooky Khan

SPECIES

Feline

BREED

DSH

SEX

Spayed Female

AGE

13 Years

WEIGHT

10.3 lbs

INTERPRETED BY

Eric Lindquist, DMV,
DABVP (CFM), Cert.
IVUSS

IMAGING PERFORMED BY

Kerri Becker

HOSPITAL NAME

Packanack Animal
Hospital

REFERRING VET

Dr. Gonzaga

INVOICE

74781

DATE

4/28/26

Pancreas

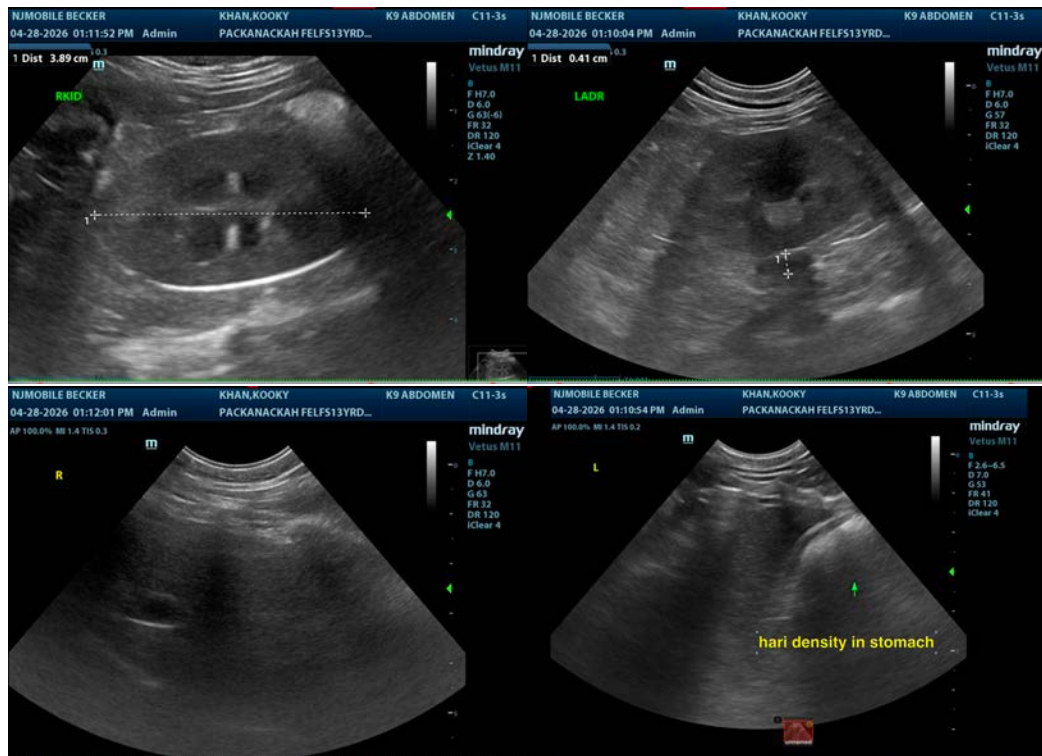
The base and limbs of the **pancreas** were observed to be largely isoechoic to surrounding omental fat. Pancreatic duct and capsular contour were acceptably normal and parenchyma respected normal curvilinear patterns. No overt evidence of active inflammatory or neoplastic disease was noted.

ULTRASONOGRAPHIC FINDINGS

- Hairball density in the stomach.
- Minor nephrolithiasis, primarily in the right kidney.

INTERPRETATION OF THE FINDINGS & FURTHER RECOMMENDATIONS

Structurally unremarkable abdomen. The patient may be passing calculi periodically, yet no obstructive disease noted at this time.





PATIENT

Kooky Khan

SPECIES

Feline

BREED

DSH

SEX

Spayed Female

AGE

13 Years

WEIGHT

10.3 lbs

INTERPRETED BY

Eric Lindquist, DMV,
DABVP (CFM), Cert.
IVUSS

**IMAGING
PERFORMED BY**

Kerri Becker

HOSPITAL NAME

Packanack Animal
Hospital

REFERRING VET

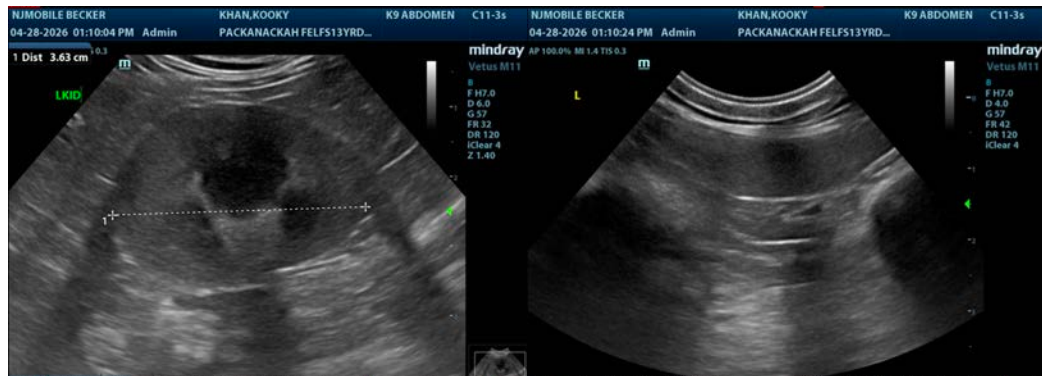
Dr. Gonzaga

INVOICE

74781

DATE

4/28/26



The information and recommendations provided are based on the images presented by the referring veterinarian/sonographer. No evaluation can be communicated regarding pathology that was not visible in the image/video clips provided.

Thank you for this referral. If the clinical or image interpretation does not parallel your findings or if I can be of any further assistance please contact me.

Eric Lindquist, DMV, DABVP(CFM), Cert. IVUSS,
CEO, Owner, Founder -- SonoPath.com
info@SonoPath.com