



**PATIENT**

Daisy Oldring

**SPECIES**

Canine

**BREED**

Beagle Mix

**SEX**

Spayed Female

**AGE**

9

**WEIGHT**

42

**INTERPRETED BY**

Eric Lindquist, DMV,  
DABVP(CFM), Cert.  
IVUSS

**IMAGING PERFORMED BY**

Dr. Susan Lincoski

**HOSPITAL NAME**

University Drive  
Veterinary Hospital

**REFERRING VET**

Dr. Susan Lincoski

**INVOICE**

15548

**DATE**

04/28/26

**PRESENTING CLINICAL SIGNS**

New heart murmur at annual exam, 2-3/6, some increased panting with exercise.

Abnormal PE/Chem/CBC/UA Results: CBC - WBCs slightly low (5.5K), otherwise WNL Chem - glucose mildly elevated (115), ALT (122), T4 mildly low (0.9) U/A: USG = 1.022, WNL 4dx- anaplasma positive (residual)previously treated. NuQ = <22.7 = LOW Pro BNP = 363 (WNL)

**ULTRASONOGRAPHIC EXAMINATION OF THE HEART & ABDOMEN**

CANINE CARDIAC PARAMETERS	MR VMAX (m/s)	TR VMAX (m/s)	LA/AO (M-Mode)	LA/AO (Heart Base; Swe)	FS (%)	EF (%)	EPSS (cm)
NORMAL PARAMETER	4.5-5.5	<2.7	1.3	Up to 1.6	28-40	40-100	<0.6
PATIENT	--	--	1.1	--	25	51	0.45
CANINE CARDIAC PARAMETERS	HR (BPM)	AV VMAX (m/s)	PV MAX (m/s)	BODY WEIGHT	LAD LA MAX 4 Chamber	LVIDd Avg; 2D and m-mode short axis (cm)	LVIDs Avg; 2D and m-mode short axis (cm)
NORMAL PARAMETER	50-100	0.7-1.7	0.7-1.6				
PATIENT	70	--	--	42	2.9	2.92	--

**Cardiac Presentation**

The echocardiogram in this patient demonstrated normal **left atrial** size based on 3 different LA measurement methods. Chamber volumes and echogenicity were normal. The cranial and caudal **mitral** valve leaflets presented vegetative thickening consistent with endocardiosis. Doppler indicated minor centralized insufficiency. The **left ventricle** presented normal thicknesses with linear contour and was not dilated nor restricted. The **myocardium** presented normal echogenicity without subjective evidence of significant fibrotic or ischemic disease. **Contractility** of the ventricular walls was adequate and in normal range for this patient evidenced by the fractional shortening measurement and subjective evaluation of the different regions of the myocardium. The **left ventricular outflow** tract demonstrated normal laminar flow and subjective structural integrity. The **right atrium** and auricle revealed normal size, structure and content. No evidence of masses was noted or chamber overload. **Tricuspid** valvular assessment demonstrated adequate linear morphology. The **right ventricle** was of normal size (1/3 diameter of LV), chordae structure, myocardial echogenicity and thickness. **Pulmonic** tract assessment revealed normal valve structure, laminar flow, and diameter (approx.1:1 pa/ao ratio). No visible **pericardial** or free pleura fluid was noted. No echographically detectable evidence of infiltrative disease was visible. The cranial **mediastinum and pericardial regions** were free of masses in the visible window.

**Urinary System**



## PATIENT

Daisy Oldring

## SPECIES

Canine

## BREED

Beagle Mix

## SEX

Spayed Female

## AGE

9

## WEIGHT

42

## INTERPRETED BY

Eric Lindquist, DMV,  
DABVP(CFM), Cert.  
IVUSS

## IMAGING PERFORMED BY

Dr. Susan Lincoski

## HOSPITAL NAME

University Drive  
Veterinary Hospital

## REFERRING VET

Dr. Susan Lincoski

## INVOICE

15548

## DATE

04/28/26

The **urinary bladder**, trigone, and pelvic urethra to a depth of 2.0 cm presented normal thicknesses and normal tone. The ureters were not visible which is normal. No uroliths or sediment were visualized, and anechoic urine was present. No evidence of inflammatory or neoplastic changes were noted. Ureteral papillae were normal.

The **kidneys** revealed largely normal size and structure, corticomedullary definition and ratio (cortex 1/3 of medulla) were essentially maintained with some age-related loss of curvilinear patterns regarding the capsule and C/M junction. The cortices presented largely uniform texture with some increased echogenicity expected for his age patient. Medullary structure differed distinctly from that of the cortex. Dystrophic mineralization was noted and non-obstructive at this time. The left kidney measured 5.0 cm in length. The right kidney measured 5.5 cm in length.

### **Adrenal Glands**

The **left adrenal gland** was visualized and recognized as having normal shape, size, position and echogenicity for this breed. The phrenic vasculature, glandular echogenicity and detail were unremarkable. Capsule, cortex, and medullary definition were normal for this age patient. The left adrenal gland measured 1.66 cm x 0.54 cm width.

The region of the **right adrenal gland** was imaged with no gross pathology yet not overtly visualized.

### **Spleen**

The **spleen** presented with multifocal coalescing nodular changes comprising a mass in the mid body measuring 3.7 cm. Other nodular changes were present in the spleen. The splenic mass is mildly vascular and appeared to be isolated. No evidence of static disease.

### **Liver**

The **liver** images from right and left intercostal as well as subcostal views revealed subjectively normal liver size, contour, and structure. Some mild age-related parenchymal remodeling was noted but likely not clinically significant at this time. Vascular and biliary tracts were of normal volume and no evidence of congestion was noted. The gallbladder presented some dependent debris with essentially normal contour. The cystic and common bile ducts were normal. No overt evidence of active inflammatory, infiltrative or regenerative pathology was noted but should be paired with current or past LE elevations regarding any clinical significance to this presentation. The hepatic lymph nodes were unremarkable.

### **Gastrointestinal**

Examination of the **gastrointestinal tract** revealed a stomach and intestine free of stasis, of normal wall thickness, acceptable curvilinear mural detail, and peristaltic activity. Small and large intestine demonstrated normal luminal chyme and stool consistency respectively. No obstructive or overt infiltrative disease was noted. No associated abnormal lymphatic activity was noted.

### **Pancreas**

The base and limbs of the **pancreas** were observed to be largely isoechoic to surrounding omental fat. Pancreatic duct and capsular contour were acceptably normal and parenchyma respected normal curvilinear patterns. No overt evidence of active inflammatory or neoplastic disease was noted.

## ULTRASONOGRAPHIC FINDINGS



## PATIENT

Daisy Oldring

- Stage B1 valvular disease.
- Splenic mass- incidental finding.
- Hepatic remodeling.
- Age-related renal changes.

## SPECIES

Canine

## BREED

Beagle Mix

## SEX

Spayed Female

## AGE

9

## WEIGHT

42

## INTERPRETED BY

Eric Lindquist, DMV,  
DABVP(CFM), Cert.  
IVUSS

## IMAGING PERFORMED BY

Dr. Susan Lincoski

## HOSPITAL NAME

University Drive  
Veterinary Hospital

## REFERRING VET

Dr. Susan Lincoski

## INVOICE

15548

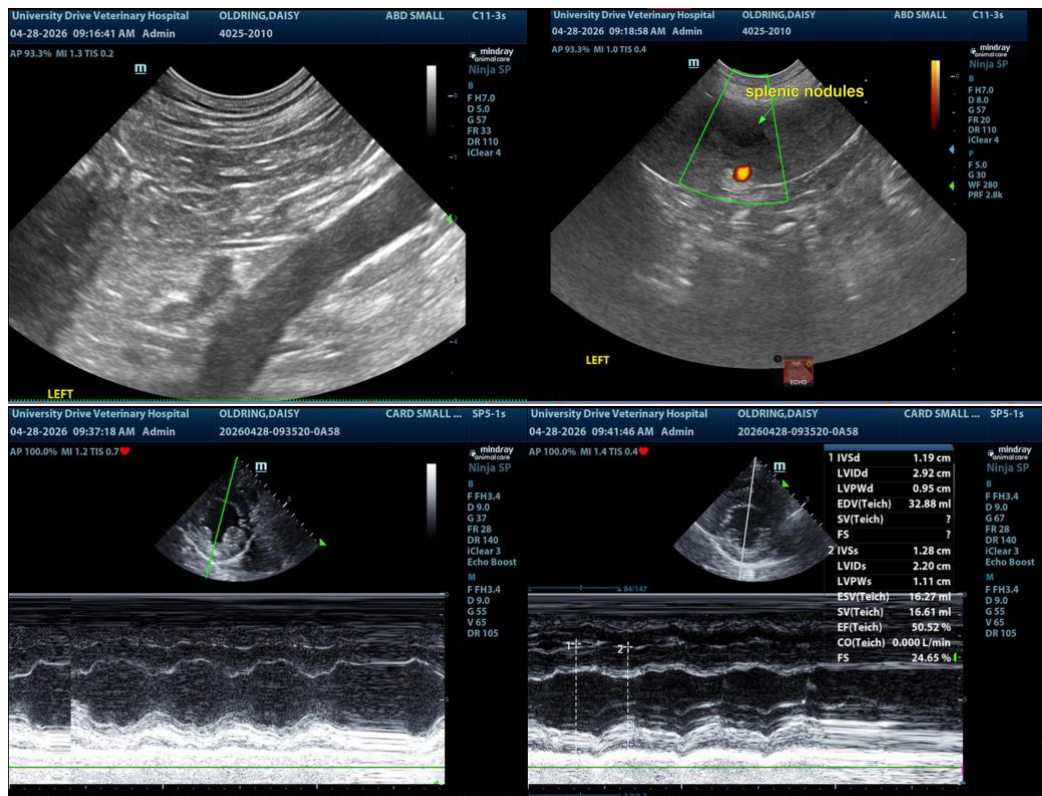
## DATE

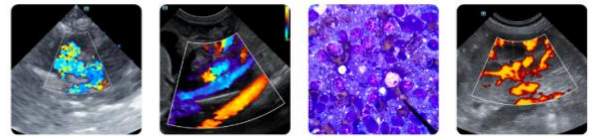
04/28/26

## INTERPRETATION OF THE FINDINGS & FURTHER RECOMMENDATIONS

The heart is stable without clinical disease. No overt contraindication for anesthesia of brief to moderate duration. I suggest Torbutrol premed, Propofol induction, Isoflor maintenance or similar protocol if anesthesia is desired. Blood pressure, EKG and chest radiographs are recommended if not already performed. Target white coat negative systolic pressure of < 160 mmHg. If higher than this ACE-inhibitor is suggested to reach this level. Recheck echocardiogram is recommended in 6-12 months, earlier if murmur grade increases or clinical signs initiate.

Recommend chest radiographs followed by splenectomy. Given the echotexture and character of the mass, recommend proactive splenectomy in this patient. The mass may be benign with hyperplasia, abscessation, hemangiosarcoma however, round cell neoplasia are strong potentials.





**PATIENT**

Daisy Oldring

**SPECIES**

Canine

**BREED**

Beagle Mix

**SEX**

Spayed Female

**AGE**

9

**WEIGHT**

42

**INTERPRETED BY**

Eric Lindquist, DMV,  
DABVP(CFM), Cert.  
IVUSS

**IMAGING  
PERFORMED BY**

Dr. Susan Lincoski

**HOSPITAL NAME**

University Drive  
Veterinary Hospital

**REFERRING VET**

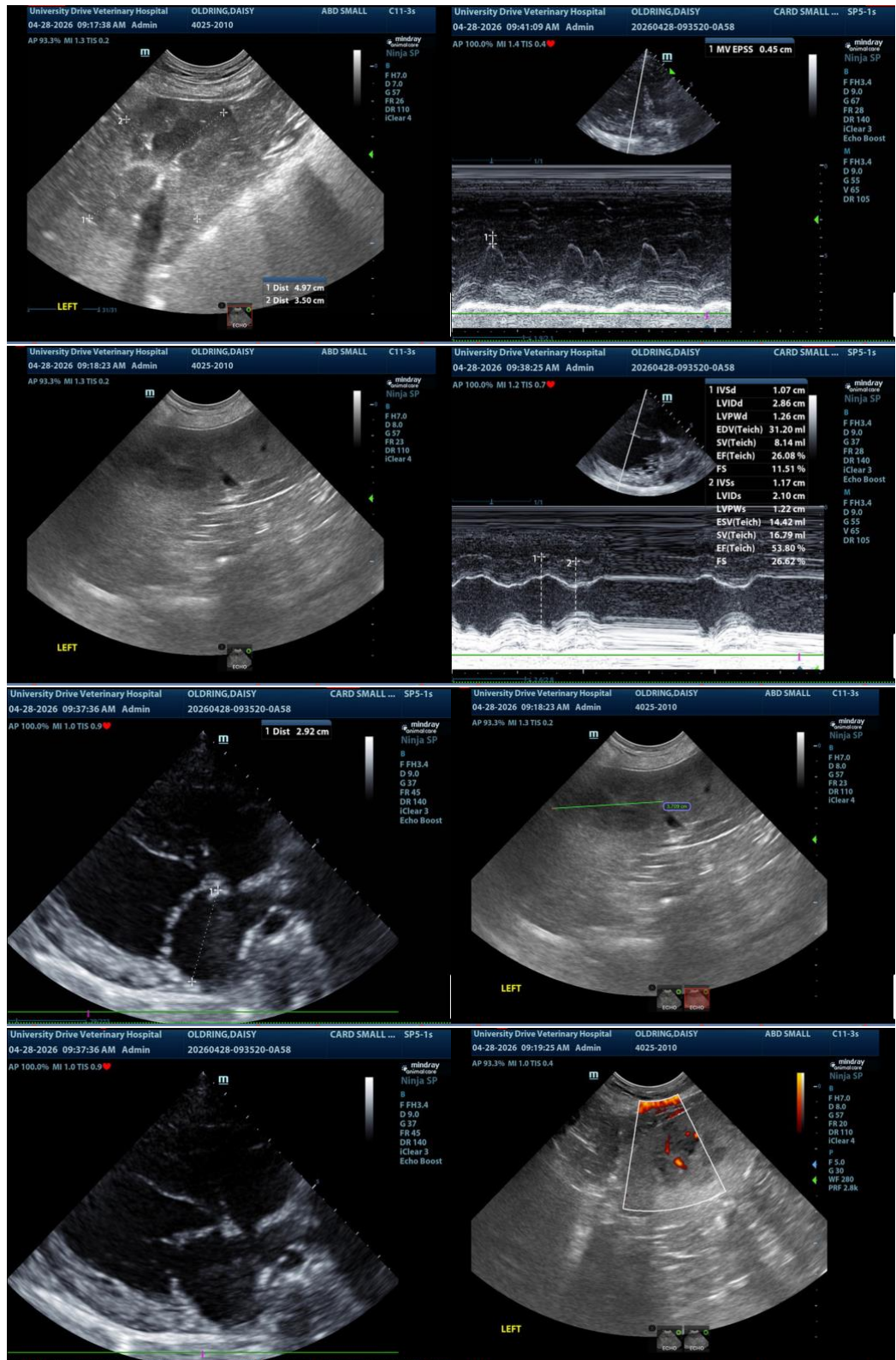
Dr. Susan Lincoski

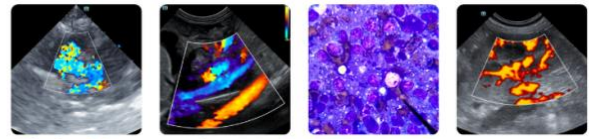
**INVOICE**

15548

**DATE**

04/28/26





## PATIENT

Daisy Oldring

## SPECIES

Canine

## BREED

Beagle Mix

## SEX

Spayed Female

## AGE

9

## WEIGHT

42

## INTERPRETED BY

Eric Lindquist, DMV,  
DABVP(CFM), Cert. IVUSS

## IMAGING PERFORMED BY

Dr. Susan Lincoski

## HOSPITAL NAME

University Drive  
Veterinary Hospital

## REFERRING VET

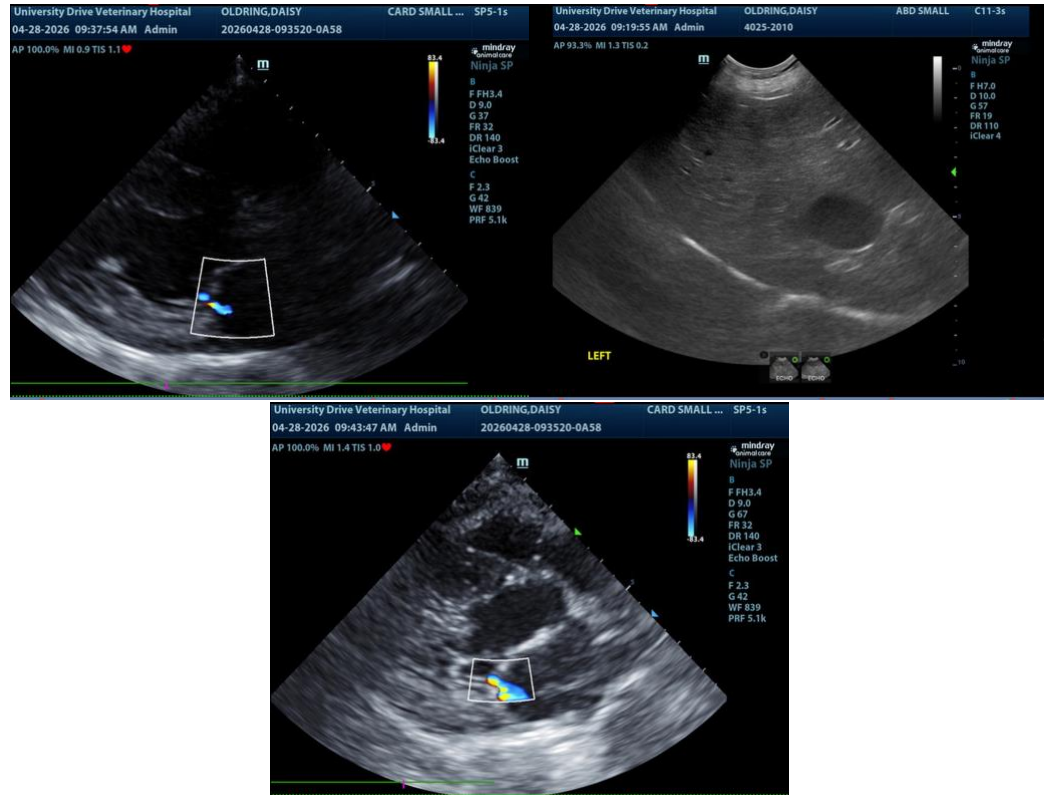
Dr. Susan Lincoski

## INVOICE

15548

## DATE

04/28/26



The information and recommendations provided are based on the images presented by the referring veterinarian/sonographer. No evaluation can be communicated regarding pathology that was not visible in the image/video clips provided.

Thank you for this referral. If the clinical or image interpretation does not parallel your findings or if I can be of any further assistance, please contact me.

**Eric Lindquist, DMV, DABVP(CFM), Cert. IVUSS,**

CEO, Owner, Founder -- SonoPath.com

[info@SonoPath.com](mailto:info@SonoPath.com)