



PATIENT

Cashmere Rebman

SPECIES

Feline

BREED

Ragdoll

SEX

Neutered Male

AGE

13 Years 11 Months

WEIGHT

10.75 lbs

INTERPRETED BY

Eric Lindquist, DMV,
DABVP (CFM), Cert.
IVUSS

IMAGING PERFORMED BY

Chlow Lowe, CVT

HOSPITAL NAME

Hackettstown Animal
Hospital

REFERRING VET

Dr. Bahr

INVOICE

74770

DATE

4/28/26

PRESENTING CLINICAL SIGNS

Concern for weight loss 2/2026 was 12.75 pounds now 10.75. Appetite fluctuates, no PU/PD, vomited one time only, normal stools. Exam unremarkable except weight loss. On S/O diet. History of crystals. 4/21/26 appetite 'OK' if change foods frequently, Audible G.I. noise at night.

Abnormal PE/Chem/CBC/UA Results: CBC /chem WNL. T4 1.2, free T4 32.5

ULTRASONOGRAPHIC EXAMINATION OF THE ABDOMEN

Urinary System

The **urinary bladder**, trigone, and pelvic urethra presented normal thicknesses and normal tone. The ureters were not visible which is normal. No uroliths or sediment were visualized and anechoic urine was present. No evidence of inflammatory or neoplastic changes were noted. Ureteral papillae were normal. The pelvic urethra was imaged 2.0 cm beyond the cystourethral junction.

The **kidneys** revealed largely normal size and structure, corticomedullary definition and ratio (cortex 1/3 of medulla) were essentially maintained with some age-related loss of curvilinear patterns regarding the capsule and C/M junction. The cortices presented largely uniform texture with some increased echogenicity expected for his age patient. Medullary structure differed distinctly from that of the cortex and no evidence of pelvic dilation was present. Left kidney measured 3.7 cm. Right kidney measured 4.3 cm.

Adrenal Glands

Both **adrenal glands** were visualized and recognized as having normal shape, size, position and echogenicity for this breed. The phrenic vasculature, glandular echogenicity and detail were unremarkable. Capsule, cortex, and medullary definition were normal for this age patient. Left measured 0.34 cm. Right measured 0.40 cm.

Spleen

The **spleen** presented a smooth homogeneous parenchyma hyperechoic to liver and renal cortical parenchyma. The capsule was smooth without noticeable expansion or deviation from within the spleen or adjacent pathology. The splenic vasculature demonstrated normal volume without signs of congestion or thrombosis. No sonographic evidence of acute or chronic inflammatory, neoplastic, or infarctual changes were noted.

Liver

The **liver** images from right and left intercostal as well as subcostal views revealed subjectively normal liver size, contour, and structure. Some age-related parenchymal remodeling was noted but likely not clinically significant at this time. Vascular and biliary tracts were of normal volume and no evidence of congestion was noted. The gallbladder presented some dependent debris with essentially normal contour. The cystic and common bile ducts were normal. No overt evidence of active inflammatory, infiltrative or regenerative pathology was noted but should be paired with current or past LE elevations regarding any clinical significance to this presentation. The hepatic lymph nodes were unremarkable.



PATIENT

Cashmere Rebman

SPECIES

Feline

BREED

Ragdoll

SEX

Neutered Male

AGE

13 Years 11 Months

WEIGHT

10.75 lbs

INTERPRETED BY

Eric Lindquist, DMV,
DABVP (CFM), Cert.
IVUSS

IMAGING PERFORMED BY

Chlow Lowe, CVT

HOSPITAL NAME

Hackettstown Animal
Hospital

REFERRING VET

Dr. Bahr

INVOICE

74770

DATE

4/28/26

Gastrointestinal

The **gastrointestinal** presentation revealed mild uniform prominence of the gastric mucosa as well as areas of "ropey" small intestinal wall with slight disruption of the normal 1:3 muscularis/mucosal ratio. The intestinal submucosa was slightly irregular, thickened and hyperechoic suggestive of low grade, chronic disease. No concerning lymphadenopathy was visible. No evidence of obstruction was present. Some reactive mesentery noted associated with the thickened intestine. Chronic inflammatory bowel disease is likely with a low possibility of an early neoplastic event such as lymphoma. Full thickness tissue biopsies via open laparotomy, ideally guided by intraoperative ultrasound in order to obtain the most representative mural sample, would be necessary to rule out this possibility.

Pancreas

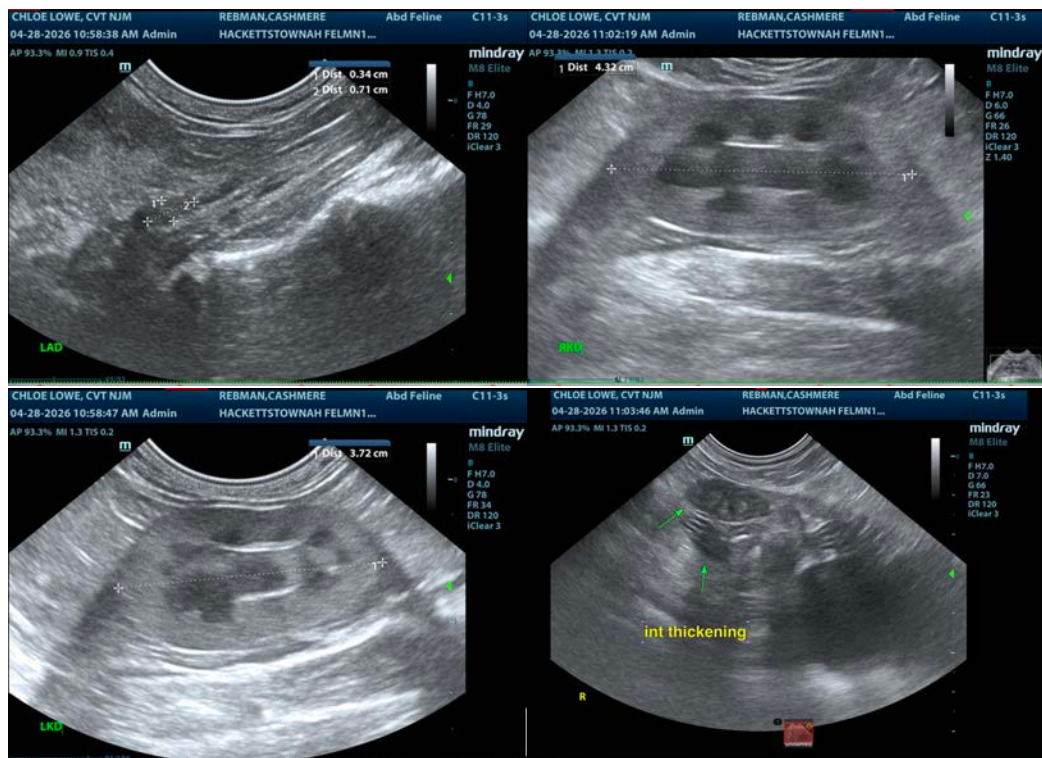
The base and limbs of the **pancreas** were observed to be largely isoechoic to surrounding omental fat. Pancreatic duct and capsular contour were acceptably normal and parenchyma respected normal curvilinear patterns. No overt evidence of active inflammatory or neoplastic disease was noted.

ULTRASONOGRAPHIC FINDINGS

- Thickened intestine without neoplastic criteria – Inflammatory bowel likely.
- Age related abdominal changes otherwise.

INTERPRETATION OF THE FINDINGS & FURTHER RECOMMENDATIONS

No neoplastic criteria met in any of the organ systems. However, thickened intestine is present, most consistent with inflammatory bowel.





PATIENT

Cashmere Rebman

SPECIES

Feline

BREED

Ragdoll

SEX

Neutered Male

AGE

13 Years 11 Months

WEIGHT

10.75 lbs

INTERPRETED BY

Eric Lindquist, DMV,
DABVP (CFM), Cert.
IVUSS

IMAGING PERFORMED BY

Chlow Lowe, CVT

HOSPITAL NAME

Hackettstown Animal
Hospital

REFERRING VET

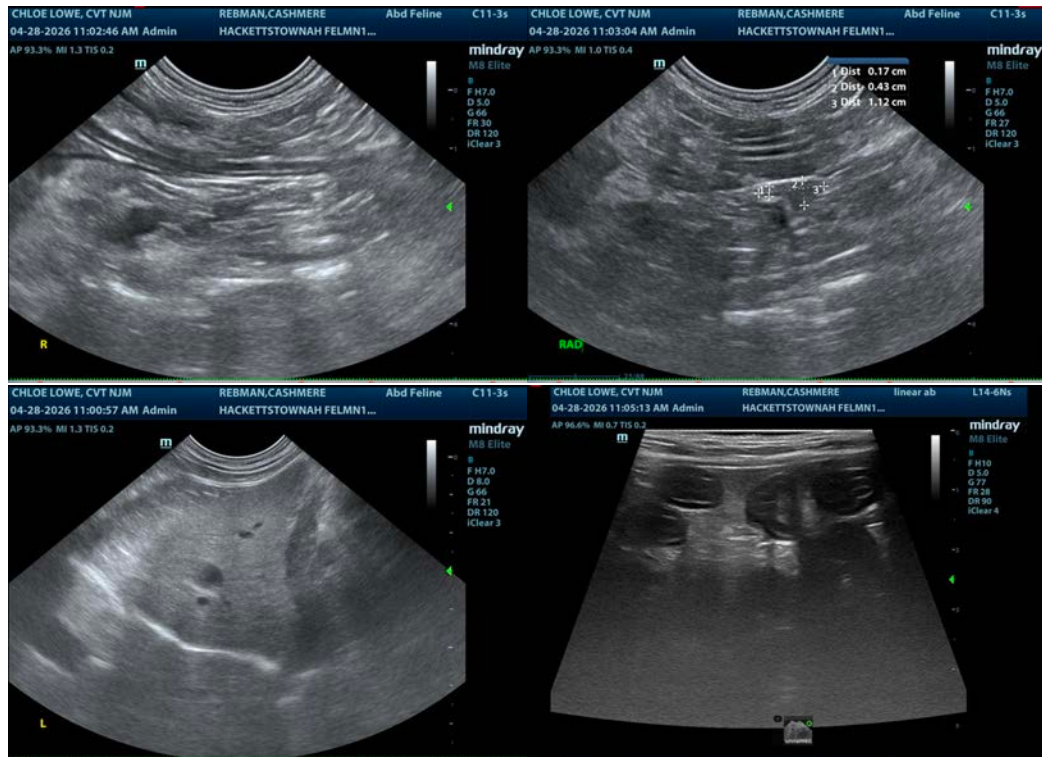
Dr. Bahr

INVOICE

74770

DATE

4/28/26



The information and recommendations provided are based on the images presented by the referring veterinarian/sonographer. No evaluation can be communicated regarding pathology that was not visible in the image/video clips provided.

Thank you for this referral. If the clinical or image interpretation does not parallel your findings or if I can be of any further assistance please contact me.

Eric Lindquist, DMV, DABVP(CFM), Cert. IVUSS,
CEO, Owner, Founder -- SonoPath.com
info@SonoPath.com