



PATIENT

Buddy Maimone

SPECIES

Canine

BREED

Bichon

SEX

Neutered male

AGE

12 years

WEIGHT

17 lbs

INTERPRETED BY

Eric Lindquist, DMV
DABVP, Cert. IVUSS

IMAGING PERFORMED BY

Dr. Wasserman

HOSPITAL NAME

Insight Imaging

REFERRING VET

Dr. Defabio

INVOICE

74924

DATE

4/28/26

PRESENTING CLINICAL SIGNS

History: 4/24/26 Full SDEP abdomen submitted at time of clinical complaint consistent with pancreatitis. Submitting recheck views of the pancreas 8a and duodenum since pancreas was not distinctly seen on 4/24/25 US. Patient appears BAR and markedly improved today with outpatient supportive care. There are no clinical complaints today.

Abnormal PE/Chem/CBC/UA Results: No pain or discomfort at time of ultrasound today compared to 4/24/26 US. No sedation needed today.

ULTRASONOGRAPHIC EXAMINATION OF THE ABDOMEN

Right Adrenal Gland

The right adrenal gland measured 0.6 cm at the caudal pole and 0.78 cm at the cranial pole.

Liver

The visible **liver** was unremarkable.

Gastrointestinal

There was some residual chyme and gas was noted in the **stomach**, yet not pathological. This is consistent with post prandial presentation. Transit of chyme into the small intestine was normal. Curvilinear patterns were maintained throughout the GI tract. No evidence of pathology. Small and large intestine demonstrated normal luminal chyme and stool consistency respectively. No obstructive or overt infiltrative disease was noted. No associated abnormal lymphatic activity was noted.

Pancreas

The **pancreas** revealed slight coarse architecture, yet the curvilinear patterns were maintained. There was minor undulating contour and minor remodeling. The left pancreatic limb revealed a 0.8 cm cyst. This is not overtly pathological. I cannot rule out focal abscessation.

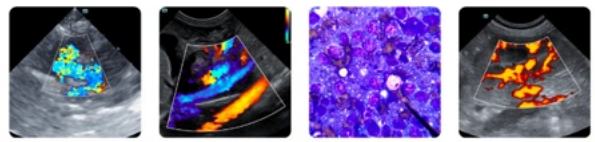
ULTRASONOGRAPHIC FINDINGS

Pancreas, largely resolved with a focal cyst.

Full stomach.

INTERPRETATION OF THE FINDINGS & FURTHER RECOMMENDATIONS

Ultrasound-guided drainage of the small cyst and culture would be ideal.



PATIENT

Buddy Maimone

SPECIES

Canine

BREED

Bichon

SEX

Neutered male

AGE

12 years

WEIGHT

17 lbs

INTERPRETED BY

Eric Lindquist, DMV
DABVP, Cert. IVUSS

IMAGING PERFORMED BY

Dr. Wasserman

HOSPITAL NAME

Insight Imaging

REFERRING VET

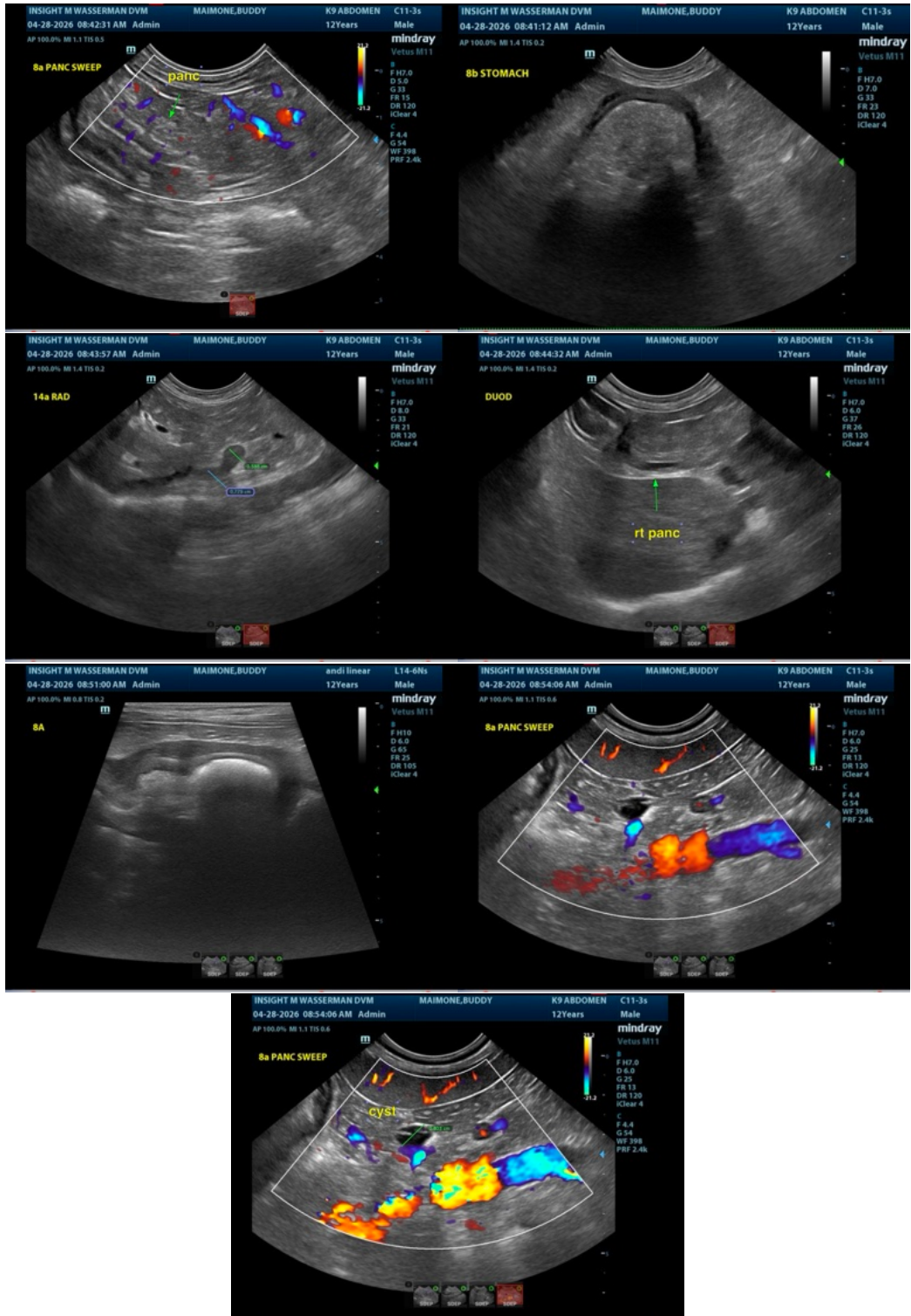
Dr. Defabio

INVOICE

74924

DATE

4/28/26



The information and recommendations provided are based on the images presented by the



PATIENT

Buddy Maimone

SPECIES

Canine

BREED

Bichon

SEX

Neutered male

AGE

12 years

WEIGHT

17 lbs

INTERPRETED BY

Eric Lindquist, DMV
DABVP, Cert. IVUSS

IMAGING PERFORMED BY

Dr. Wasserman

HOSPITAL NAME

Insight Imaging

REFERRING VET

Dr. Defabio

INVOICE

74924

DATE

4/28/26

referring veterinarian/sonographer. No evaluation can be communicated regarding pathology that was not visible in the image/video clips provided.

Thank you for this referral. If the clinical or image interpretation does not parallel your findings or if I can be of any further assistance please contact me.

Eric Lindquist, DMV, DABVP (CFM), Cert. IVUSS, CEO of SonoPath.com

info@SonoPath.com