

**DATE PRESENTING CLINICAL SIGNS**

4/28/23

**PATIENT**

Trooper Fine

**SPECIES**

Canine

**BREED**

Labrador Mix

**SEX**

Neutered Male

**AGE**

10/25/15

**WEIGHT**

89.5 Pounds

**INTERPRETED BY**Eric Lindquist, DMV  
DABVP, Cert. IVUSS**HOSPITAL NAME**Animal Emergency  
Hospital**REFERRING VET**

Dr. Nacke-Horney

**INVOICE**

22196

History: ATO: lethargic. went for a mid-day walk - standard walk nothing special. came back and house smelled nasty, saw him burp and licking his lips. vomited twice on walk. vomited twice after being home - now digested food (last ate 7am) not typically one to get into anything. doesn't destroy toys  
 Date: 04-27-2023 Notes: Seemed more calm today than normal - went on walk and he seemed normal other wise - produced normal BM. Owner left and when he came back, noted house smelled odd Was walked by dog walker - vomited twice on the walk then vomited again when he got back home Would drink a bunch of water after drinking. Owner noted that grass is treated but has been over a week since - will keep patient off the yard for a few days after it is treated. Can't get to cat litter box Potential for him to eat something in the yard Change his food 2-3 weeks ago, was a quick change - was on grain free prior to the change Will occasionally get scraps like eggs cooked in butter or piece of string cheese, strawberries Will make him puppy frosty - plain yogurt, peanut butter, banana, honey Known allergies in spring and fall - has been getting benedryl with jiff peanut butter

Current Medications: Unasyn, Denamarin, Cerenia.

Lab Results: See attached.

Radiographs: Empty stomach, decreased serosal detail.

Date of Previous IntraPet Ultrasound: No previous.

Sedation: Not required to complete full diagnostic ultrasound.

Stat Report: Not requested.

Imaging Performed By: Rachel Brillhart, RDMS.

**ULTRASONOGRAPHIC EXAMINATION OF THE ABDOMEN****Urinary System**

The **urinary bladder**, trigone, and pelvic urethra presented normal thicknesses and normal tone. The ureters were not visible which is normal. No uroliths or sediment were visualized and anechoic urine was present. No evidence of inflammatory or neoplastic changes were noted. Ureteral papillae were normal.

The **kidneys** revealed normal size and structure, corticomedullary definition and ratio for this age. The cortices presented largely uniform texture with normal echogenic relationship to liver and spleen. Medullary structure differed distinctly from the cortex and no evidence of pelvic dilation was present. The capsules were acceptably uniform without significant irregularities. The left kidney measured 8.23 cm. The right kidney measured 8.23 cm.

**Adrenal Glands**

Both **adrenal glands** were visualized and recognized as having normal shape, size, position and echogenicity for this breed. The phrenic vasculature, glandular echogenicity and detail were unremarkable. Capsule, cortex, and medullary definition were normal for this age patient. The right adrenal gland measured 2.9 cm x 0.93 cm at the cranial pole and 0.8 cm at the caudal pole. The left adrenal gland measured 3.09 cm x 0.74 cm at the caudal pole and 0.7 cm at the cranial pole.

**Spleen**

The **spleen** presented a smooth homogeneous parenchyma hyperechoic to liver and renal cortical parenchyma. The capsule was smooth without noticeable expansion or deviation from within the spleen or adjacent pathology. The splenic vasculature demonstrated normal volume without signs of congestion or thrombosis. No sonographic evidence of acute or chronic inflammatory, neoplastic, or infarctual changes were noted.

### **Liver**

The **liver** images submitted revealed subjectively normal liver size, contour, and structure. Parenchymal echogenicity was naturally coarse and hypoechoic to the spleen. Vascular and biliary tracts were of normal volume with no evidence of congestion. The gallbladder presented acceptably thin walls with primarily anechoic content. The cystic and common bile ducts were normal. No pathological hepatic lymphadenopathy was evident. No overt structural evidence of inflammatory, infiltrative or regenerative pathology was evident.

### **Gastrointestinal**

Examination of the **gastrointestinal tract** revealed a stomach and intestine free of stasis, of normal wall thickness, acceptable curvilinear mural detail, and peristaltic activity. Small and large intestine demonstrated normal luminal chyme and stool consistency respectively. No obstructive or overt infiltrative disease was noted. No associated abnormal lymphatic activity was noted.

### **Pancreas**

The base and limbs of the **pancreas** were observed to be largely isoechoic to surrounding omental fat. Pancreatic duct and capsular contour were acceptably normal and parenchyma respected normal curvilinear patterns. No overt evidence of active inflammatory or neoplastic disease was noted.

### **Free Abdomen**

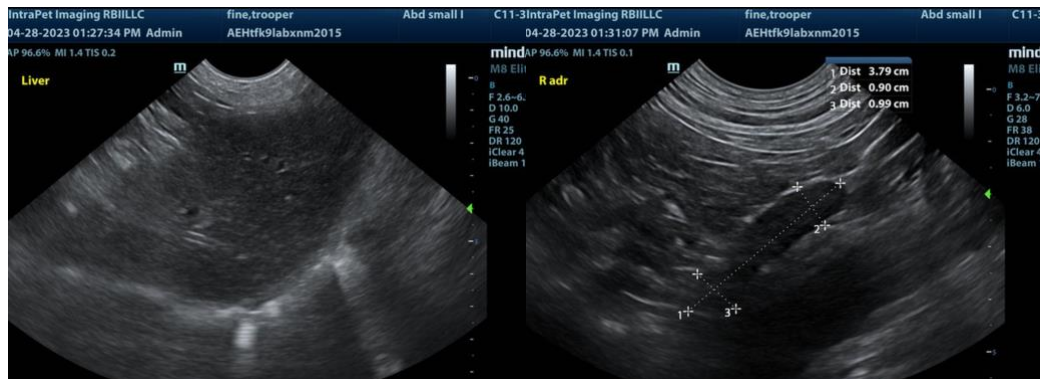
The **mesenteric lymph nodes** were slightly enlarged, measuring up to 2.45 cm x 0.73 cm, reactive.

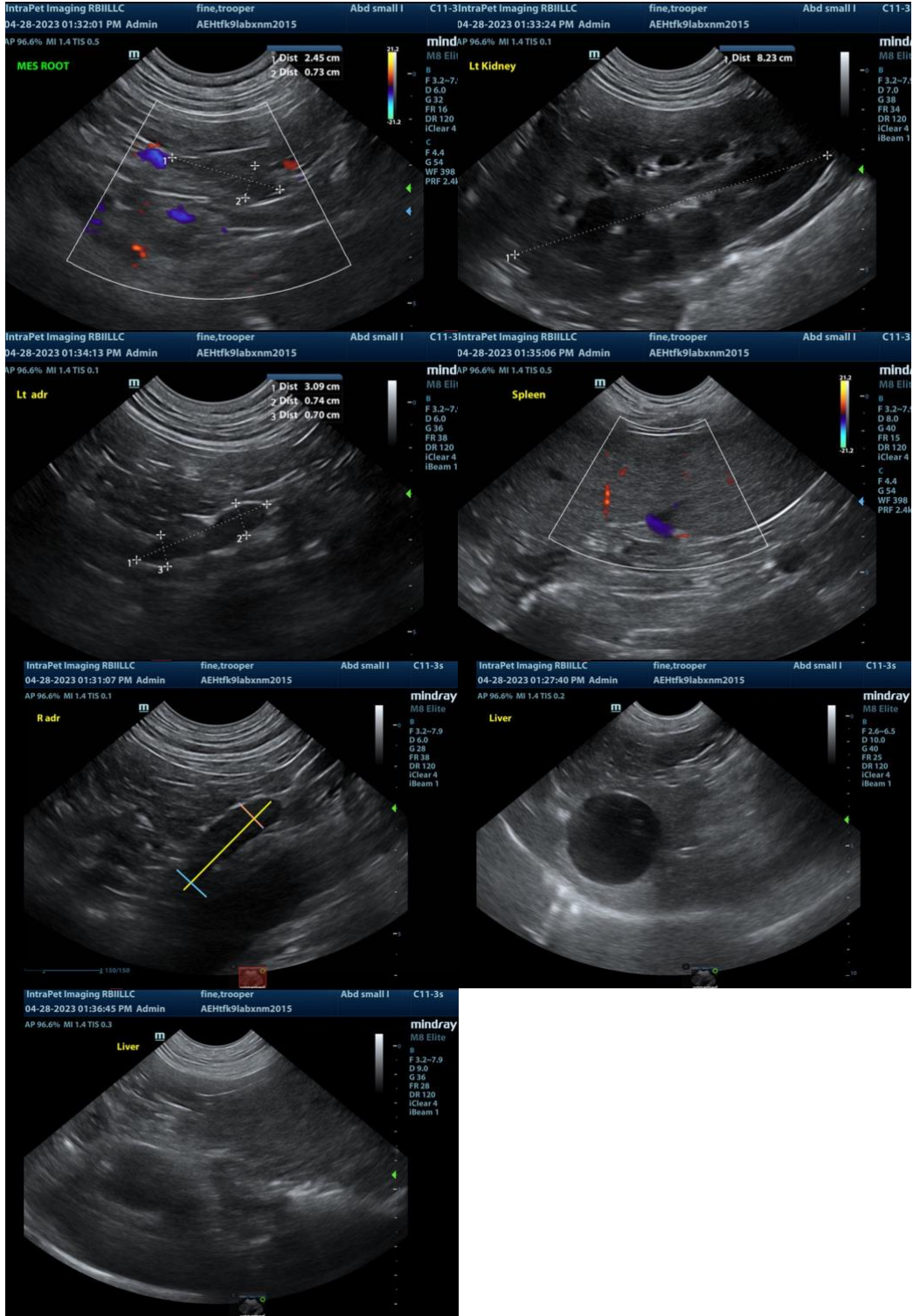
## **ULTRASONOGRAPHIC FINDINGS**

- Structurally unremarkable abdomen- no evidence of pathology responsible for the clinical signs
- Mesenteric lymph nodes were slightly enlarged/reactive

## **INTERPRETATION OF THE FINDINGS & FURTHER RECOMMENDATIONS**

Orthopedic, CNS and thoracic exam are all indicated. If clinical exam reveals abnormalities in these regions, then CT of the region is indicated.





The information and recommendations provided are based on the images presented by the

**referring veterinarian. No evaluation can be communicated regarding pathology that was not visible in the image/video clips provided.**

Thank you for this referral. If the clinical or image interpretation does not parallel your findings or if I can be of any further assistance please contact me.

**Eric Lindquist**, DMV, DABVP, Cert. IVUSS, CEO of SonoPath.com  
info@SonoPath.com