



PATIENT PRESENTING CLINICAL SIGNS

PATIENT
Ellie Labonte

SPECIES
Canine

BREED
Boxer

SEX
Spayed Female

AGE
4 years

WEIGHT
26.8 kg

INTERPRETED BY
Eric Lindquist, DMV
DABVP, Cert. IVUSS

IMAGING PERFORMED BY
Dr. Markland

HOSPITAL NAME
Island Mobile Paws VS

REFERRING VET
Saltspring VS

INVOICE
99975

DATE
4/28/22

Ellie presented for weight loss and a hard stomach. She is eating, drinking, urinating and defecating normally. The clients report normal activity level. A very large mass effect was present on PE. Radiographs confirmed and mass, suspected to be associated with either the liver or the spleen and possible ascites. CBC is normal. Chemistry is pending.

ULTRASONOGRAPHIC EXAMINATION OF THE ABDOMEN

The midabdomen revealed a 10.0 + cm cystic and parenchymal abscess/mass in the region of the spleen. However, the exact origin of the undifferentiated pathology cannot be completely ascertained and impinged upon the liver. The structure is likely splenic and/or hepatic in origin.

The left kidney was visible and does not appear involved.

The gallbladder appeared to be over distended with echogenic debris and polypoid changes.

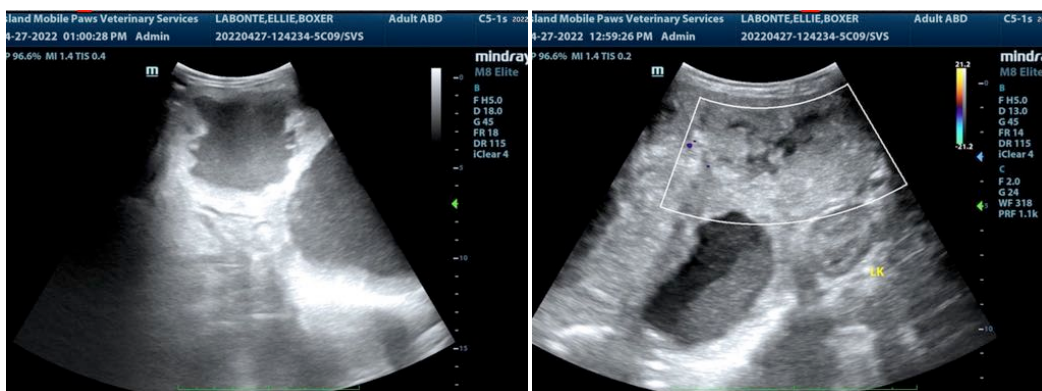
ULTRASONOGRAPHIC FINDINGS

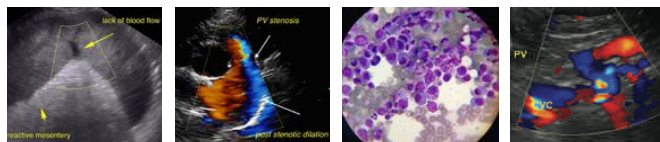
Extensive necrotic and cystic mass likely deriving from the spleen, possibly liver.

Thickened, echogenic, overdistended gallbladder.

INTERPRETATION OF THE FINDINGS & FURTHER RECOMMENDATIONS

CT evaluation is necessary for further definition or direct exploratory surgery. Abscessation versus cystic neoplasia with a mild potential for migrating foreign body.





PATIENT

Ellie Labonte

SPECIES

Canine

BREED

Boxer

SEX

Spayed Female

AGE

4 years

WEIGHT

26.8 kg

INTERPRETED BY

Eric Lindquist, DMV
DABVP, Cert. IVUSS

IMAGING PERFORMED BY

Dr. Markland

HOSPITAL NAME

Island Mobile Paws VS

REFERRING VET

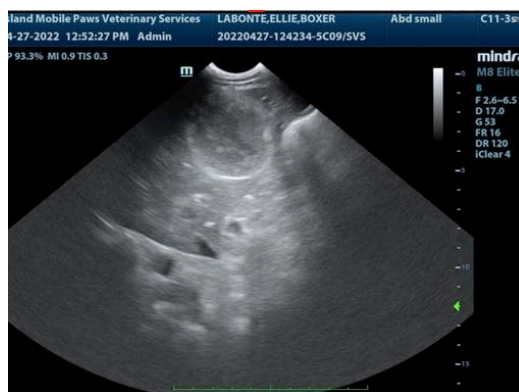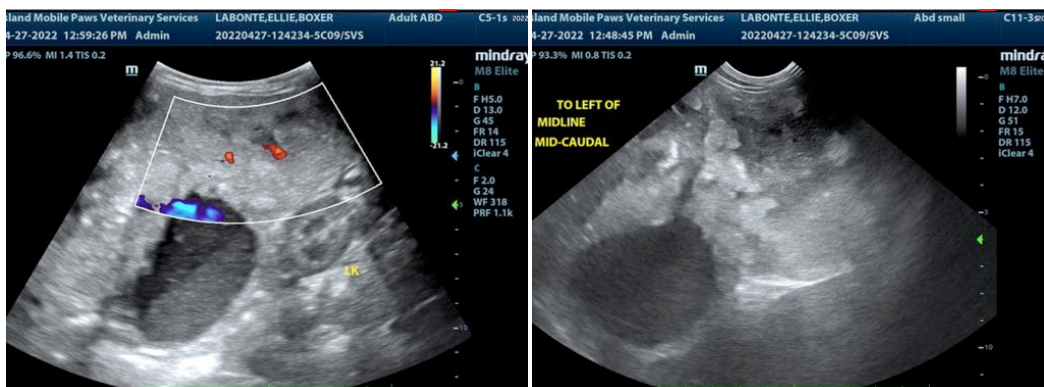
Saltspring VS

INVOICE

99975

DATE

4/28/22



The information and recommendations provided are based on the images presented by the referring veterinarian/sonographer. No evaluation can be communicated regarding pathology that was not visible in the image/video clips provided.

Thank you for this referral. If the clinical or image interpretation does not parallel your findings or if I can be of any further assistance please contact me.

Eric Lindquist, DMV, DABVP, Cert. IVUSS, CEO of SonoPath.com
info@SonoPath.com