



PATIENT

Zoey Hinton

SPECIES

Canine

BREED

Manx

SEX

Spayed female

AGE

10 years

WEIGHT

9.26 lbs

INTERPRETED BY

Eric Lindquist, DMV
DABVP, Cert. IVUSS

IMAGING PERFORMED BY

Leon Anderson, DVM

HOSPITAL NAME

Elizabeth AH

REFERRING VET

Dr. Anderson

INVOICE

74885

DATE

4/27/26

PRESENTING CLINICAL SIGNS

History: Elevated BNP and Murmur on wellness examination and wellness lab testing. For years will wheeze once in a while. No real issues at home.

PE: Cardiac Murmur, grade II/VI, Left heart base, systolic BCS 3/5 Heart rate 190 bpm, respiratory rate panting (nervous) Labs: 4/21/26 Normal CBC, Chem, spec fPL, total and Free T4 Cardiopet proBNP 275 pmol/L

ULTRASONOGRAPHIC EXAMINATION OF THE HEART

The echocardiogram in this patient demonstrated normal **left atrial** size based on 3 separate LA measurements. Trivial **mitral** valve insufficiency was noted, yet not clinically significant. The **left ventricle** presented normal thicknesses with linear contour and was not dilated nor restricted. The **myocardium** presented normal echogenicity without subjective evidence of significant fibrotic or ischemic disease. **Contractility** of the ventricular walls was adequate and in normal range for this patient evidenced by the fractional shortening measurement and subjective evaluation of the different regions and angles of the myocardium. The **left ventricular outflow** tract demonstrated normal laminar flow and subjective structural integrity. The **right atrium** and auricle revealed normal size, structure and content. No evidence of masses was noted or chamber overload. **Tricuspid** valvular assessment demonstrated adequate linear morphology and kinetics. The **right ventricle** was of normal size (1/3 diameter of LV), chordae structure, myocardial echogenicity and thickness. **Pulmonic** tract assessment revealed normal valve structure, laminar flow, and diameter (approx. 1:1 pa/ao ratio). No visible **pericardial** or free pleura fluid was noted or extra cardiac pathology in the visible planes. The cranial **mediastinum and pericardial regions** were free of masses in the visible window.

The hepatic veins were not dilated.

FELINE CARDIAC PARAMETERS	BODY WEIGHT	HR (BPM)	IVSd (cm)	LVIDd (cm)	LVWd (cm)	FS (%)	EF (%)
NORMAL PARAMETER	-----	150-240	0.3-0.6	1.0-2.1	0.25-0.6	35-67	80-100
PATIENT	9.26 lbs	NM	0.59	1.0	0.46	25	55
FELINE CARDIAC PARAMETERS	LA/AO (M-mode)	LA/AO HEART BASE (Sisson)	LAD LA MAX 4 Chamber		LVOT VEL. (m/s)	RVOT VEL. (m/s)	IVRT (m/)
NORMAL PARAMETER	<1.5	1.6	0.7-1.7		<1.6	<1.3	40-60
PATIENT	1.2	1.08	1.2		NM	1.1	NM
Adapted from June Boon, Veterinary Echocardiography, 1998 Sisson D et al. JVIM 1991; 5: 232, Jacobs et al. Am J Vet Res 1985; 46:1705							



PATIENT

Zoey Hinton

SPECIES

Canine

BREED

Manx

SEX

Spayed female

AGE

10 years

WEIGHT

9.26 lbs

INTERPRETED BY

Eric Lindquist, DMV
DABVP, Cert. IVUSS

IMAGING PERFORMED BY

Leon Anderson, DVM

HOSPITAL NAME

Elizabeth AH

REFERRING VET

Dr. Anderson

INVOICE

74885

DATE

4/27/26

ULTRASONOGRAPHIC FINDINGS

Normal echocardiogram, flow murmur.

Minor mitral insufficiency, no evidence of structural or functional disease.

INTERPRETATION OF THE FINDINGS & FURTHER RECOMMENDATIONS

No therapy is recommended at this time.

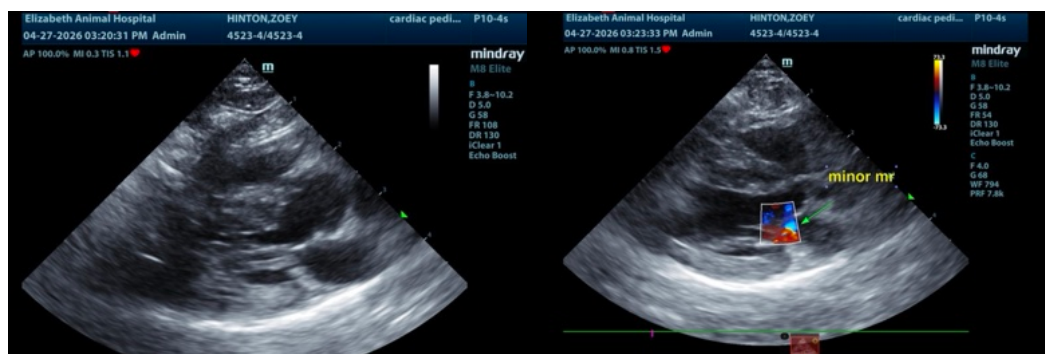
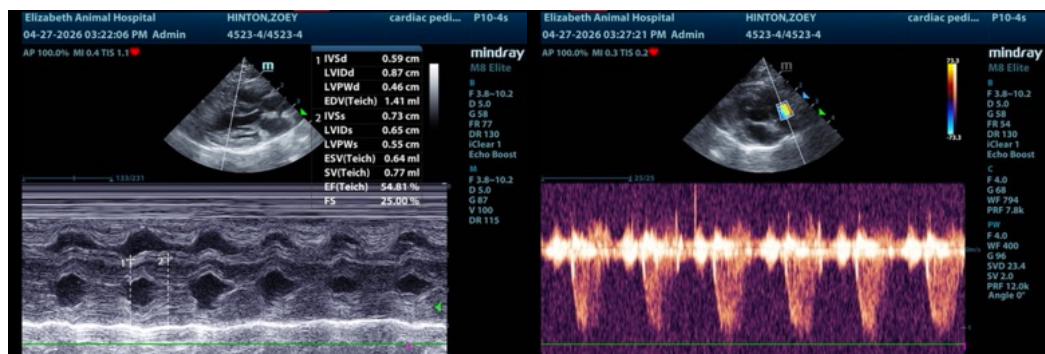
Bio markers such as NT-proBNP are screening tests for myocardial stress. A positive test (>100 pmol/liter) does not mean that cardiac disease is necessarily present.

BNP false +can occur in hyperthyroid, renal insufficiency, severe airway disease, systemic hypertension and potentially other systemic influences.

A negative result largely rules out clinically relevant myocardial disease but does not rule out occult cardiomyopathy.

In cases of pleural effusion, diluting the fluid 1:1 and testing BNP on the fluid is useful to assess if the pleural effusion is cardiogenic in nature.

Ultrasound, however, is the gold standard as far as evaluating clinically significant and occult heart disease.



The information and recommendations provided are based on the images presented by the



PATIENT

Zoey Hinton

SPECIES

Canine

BREED

Manx

SEX

Spayed female

AGE

10 years

WEIGHT

9.26 lbs

INTERPRETED BY

Eric Lindquist, DMV
DABVP, Cert. IVUSS

IMAGING PERFORMED BY

Leon Anderson, DVM

HOSPITAL NAME

Elizabeth AH

REFERRING VET

Dr. Anderson

INVOICE

74885

DATE

4/27/26

referring veterinarian/sonographer. No evaluation can be communicated regarding pathology that was not visible in the image/video clips provided.

Thank you for this referral. If the clinical or image interpretation does not parallel your findings or if I can be of any further assistance please contact me.

Eric Lindquist, DMV, DABVP (CFM), Cert. IVUSS, CEO of SonoPath.com

info@SonoPath.com