



**DATE PRESENTING CLINICAL SIGNS**

04/27/26

Patient History: Normal morning with normal stool and urination - After 8 hours away, client returned to find patient lethargic - Decreased appetite, initially refused dinner, ate when mixed with whipped cream - Client measured rectal temperature at home: 104.5-105°F on multiple readings - Increased respiratory effort/panting beyond normal baseline - Reluctance to lift back hips, takes time to move - Less reactive to other dogs than normal.

**PATIENT**

Remus Traynor

Current Medications: Gabapentin since 4/10 for cervical pain and suspected arthritis-related excessive licking. Buprenorphine.

**SPECIES**

Canine

Labwork Results: Labwork attached.

Date of Previous IntraPet Ultrasound: No previous.

Sedation: Not required to complete full diagnostic ultrasound.

Stat Report: DVM requested.

**BREED**

Miniature Australian  
Shepherd

Imaging Performed by: Andi Parkinson RDMS

**ULTRASONOGRAPHIC EXAMINATION OF THE ABDOMEN**

**SEX**

**Urinary System**

Intact Male

The **urinary bladder** and visible pelvic urethra were unremarkable for the level of repletion presented. The urine, however, did present some mildly echogenic debris consistent with mucous, exfoliated cells from renal or bladder origin, and/or blood clots as these echogenic changes can all present similarly. Some of the debris was mineralizing. This is often related to urinary tract infection but may represent simple evidence of exfoliated debris or sterile inflammation. Cystocentesis, urinalysis, +/- culture would be recommended to rule out and define any UTI. A large amount of bladder sand was present measuring 3.3 cm.

**AGE**

04/26/16

**WEIGHT**

68 pounds

The **prostate** was mildly enlarged with lobar swelling appeared to impinge upon the urethra and mildly deviate the descending colon. The prostatic tissue was hyperechoic containing focal areas of decreased echogenicity. These changes are suggestive of either chronic inflammatory episodes, benign cystic pathology or both. Underlying neoplasia cannot be completely ruled-out but is lower on the differential list. This presentation is most consistent with benign prostatic hyperplasia with possible active prostatitis.

**INTERPRETED BY**

Eric Lindquist, DMV,  
DABVP(CFM), Cert.  
IVUSS

Neutering or off-label Finasteride (Propecia) (0.1-0.5 mg/kg Sid) treatment is indicated +/- FNA or prostatic wash cytology and culture. The prostate measured 4.4 cm.

**HOSPITAL NAME**

Animal Emergency  
Hospital

The **left testicle** presented cystic and irregular measuring 5.0 cm.

**REFERRING VET**

Dr. Reynolds

The **kidneys** revealed largely normal size and structure, corticomedullary definition and ratio (cortex 1/3 of medulla) were essentially maintained with some mild age-related loss of curvilinear patterns regarding the capsule and C/M junction. The cortices presented largely uniform texture with some increased echogenicity expected for his age patient. Medullary structure differed distinctly from that of the cortex and no evidence of pelvic dilation was present. The left kidney measured 6.7 cm in length. The right kidney measured 6.7 cm in length.

**Adrenal Glands**

**INVOICE**

15481

The **right adrenal gland** was normal in size and contour measuring 2.5 cm x 0.58 cm width at the caudal pole and 0.50 cm width at the cranial pole.

The **left adrenal gland** comprised a mass. The mass is significantly vascular and measured 6.3 cm, deviating the left kidney caudally. The adrenal mass extended into the vena cava with significant invasion. The vena cava thrombus owing to the invasive left adrenal mass was extensive, measuring approximately 3.0 cm to

4.0 cm in width, extending cranially to the level of the diaphragm. The left adrenal mass was imaged both from the left and the right approach. The right approach demonstrated the extension of the vena cava thrombosis.

### *Spleen*

The **spleen** presented with subtle heterogenous hypoechoic nodular changes without disruption of architecture.

### *Liver*

The **liver** images from right and left intercostal as well as subcostal views revealed subjectively normal liver size, contour, and structure. Some moderate age-related parenchymal remodeling was noted but likely not clinically significant at this time. The gallbladder presented some dependent debris with essentially normal contour. The cystic and common bile ducts were normal. No overt evidence of active inflammatory, infiltrative or regenerative pathology was noted but should be paired with current or past LE elevations regarding any clinical significance to this presentation. The hepatic lymph nodes were unremarkable.

### *Gastrointestinal*

Examination of the **gastrointestinal tract** revealed a stomach and intestine free of stasis, of normal wall thickness, acceptable curvilinear mural detail, and peristaltic activity. Small and large intestine demonstrated normal luminal chyme and stool consistency respectively. No obstructive or overt infiltrative disease was noted. No associated abnormal lymphatic activity was noted.

### *Pancreas*

The base and limbs of the **pancreas** were observed to be largely isoechoic to surrounding omental fat. Pancreatic duct and capsular contour were acceptably normal and parenchyma respected normal curvilinear patterns. No overt evidence of active inflammatory or neoplastic disease was noted.

## **ULTRASONOGRAPHIC FINDINGS**

- Extensive left adrenal mass with caval invasion. Not resectable, enveloping greater vasculature. Likely pheochromocytoma or carcinoma.
- Urinary bladder sand.
- Nodular spleen.
- Age-related renal changes.
- Benign prostatic hyperplasia pattern.
- Retained left testicle with a cystic component.

## **INTERPRETATION OF THE FINDINGS & FURTHER RECOMMENDATIONS**

### **Adrenal Tumors**

<http://www.sonopath.com/AdrenalTumor>

**Description:** An adrenal mass is suspected when the maximum width of the adrenal gland exceeds 1.5 cm, there is loss of normal architecture or shape, or the shape or size between the affected adrenal gland

and the contralateral gland is asymmetrical. The latter comprise the initial criteria for diagnosis; however, a bulbous enlargement of the cranial or caudal pole of the adrenal gland is common in dogs with no adrenal pathology and can be misinterpreted as an adrenal mass. If the suspected mass is not precipitating obvious signs (i.e., aggressive behavior), then an abdominal ultrasound should be repeated to confirm that the mass is a consistent finding before pursuing further diagnostics or surgery. Large breeds (Poodles, German Shepherds, Retrievers, and Terriers) and females appear to be overrepresented in the clinical reviews of adrenal tumors. Adrenal tumors in cats are rare with minimal information to characterize the disease. However, adrenal carcinoma and aldosterone producing tumors are the more common adrenal masses in our archived feline population. More specific information regarding this pathology may be found in the Feline Hyperaldosterone chapter.

Incidental adrenal lesions should be investigated clinically if discovered on ultrasound. Non-neoplastic adrenal lesions, such as cysts or granulomas, are very rare in dogs and cats, and the high incidence of metastatic lesions justifies a thorough hormonal screening as well as evaluation for non-adrenal neoplasms. Although incidental adrenal masses may appear to be nonfunctional at the time of diagnosis, it seems more likely that they are in fact subclinically functional. The diagnosis of functional adrenal tumors is discussed below; however, the identification of a nonfunctional, incidental adrenal mass creates a management dilemma.

**Clinical Signs:** Clinical signs attributable to adrenal tumors are dependent on hormone secretion type. Please see below.

**Diagnostics:** Cortical adrenal tumors, such as adenomas and adenocarcinomas, are responsible for 15-20% of hyperadrenocortical cases—what are commonly referred to as adrenal-dependent hyperadrenocorticism (ADH)—in dogs. The remaining tumors are the result of pituitary-dependent secretions, which give rise to pituitary-dependent hyperadrenocorticism (PDH). PDH cases tend to demonstrate bilateral hypertrophy with excessive adrenal length and, probably more importantly, width. These enlarged adrenal glands do not invade surrounding vascular structures and are defined by overstimulation resulting from excessive ACTH secretion from the pituitary gland. Yet, ADH cases are usually unilateral (bilateral in 10-20% of cases), may invade the aorta on the left or the vena cava on the right, and metastasize to the liver and lungs most frequently. Practitioners must differentiate ADH masses from hyperplastic, non-functional, benign adrenal tumors, as well as pheochromocytomas. Thus, dynamic function tests (ex. LDDS, HDDS, ACTH stimulation, ACTH baseline, urine cortisol-creatinine ratio) are essential, as is conducting routine biochemistry (ALP is elevated in more than 90% of cases) and urinalysis (true polyuria/polydipsia [PU/PD] with USG < 1.020) to determine adequately the need for surgical intervention or aggressive medical therapy. It is important to assess the following: blood pressure for hypertension; oscillating hyper- and hypotensive episodes in cases of pheochromocytomas; urine protein-creatinine ratios; and serum antithrombin III to determine the risk for thromboembolism. Moreover, it is essential to evaluate the entire clinical picture and objective probabilities of possessing a true hyperadrenocorticism case. This further entails ruling out other sources of PU/PD, such as primary polydipsia, renal disease, electrolyte abnormalities, infections, and diabetes insipidus or mellitus.

### *Malignant or Benign, Functional or Non-Functional: How to Decide?*

In some cases, it may be difficult to determine whether the mass is malignant or benign, functional or nonfunctional, prior to surgical removal and histopathological examination. A thorough review of the clinical signs, physical examination findings, routine blood work, urine tests, and appropriate hormonal tests should be conducted to determine the functional status of an incidental adrenal mass.

Malignancy is more often associated with larger masses. The larger the mass, the more likely metastasis has already occurred, in spite of a lack of detectable lesions on ultrasound and thoracic radiographs. Invasion of the mass into surrounding organs or blood vessels also supports malignancy, as does the detection of additional mass lesions with abdominal ultrasound and thoracic radiographs. Use of imaging modalities, such as CT and MRI, will likely provide additional data on the characteristics of specific adrenal lesions for use in diagnosis and treatment planning.

Ultrasonography is the primary instrument for assessing tumor size, aggressiveness, non-capsulated versus capsulated appearance, vascular invasion, and hepatic or other metastasis. Ideally, the patient will have fasted prior to the ultrasound; one may choose to administer an enema to enhance visibility around the ascending and descending colon. Ultrasound-guided biopsy or fine needle aspiration (FNA) may be possible on the larger masses, especially on the left side; however, adjacent vascular structures often prevent the feasibility of this procedure.

### *Diagnosis of the Functional Adrenal Mass:*

- A) Cortisol-Secreting: It is very rare that a patient with hyperadrenocorticism will have a repeatable urine specific gravity greater than 1.020, so it must be determined whether the patient is truly PU/PD. If yes, then dynamic function testing is appropriate. If the patient is not truly PU/PD, then a false positive result must be considered before treatment is initiated, as the resulting hypoadrenocorticism can be life threatening. Other causes of dysuria, such as occult urinary tract infection, must then be considered. The most common functional adrenal tumor identified in dogs and cats results in hyperadrenocorticism. Approximately 15% of hyperadrenocorticism cases will be caused by a functional adrenal tumor, of which 50% of these will be malignant.
  - a. Clinical signs can include: PU/PD; polyphagia; abdominal distention; bilaterally symmetrical truncal alopecia; delayed fur regrowth; hyperpigmentation; comedones; calcinosis cutis; excessive bruising; poor wound healing; ectopic calcification of kidneys and blood vessel walls; pyodermas; muscle weakness; exercise intolerance; hypertension; and panting.
  - b. Ultrasound usually reveals a small or atrophied contralateral adrenal gland as a result of suppressed pituitary ACTH secretion. Ten to twenty percent of cases have bilateral disease. Adenomas of the adrenal gland are generally less than 2 cm in diameter, and carcinomas can be any size (often they are > 2 cm). Calcification does not appear to be predictive for either adenoma or carcinoma.
  - c. Specific biochemical tests: Urine cortisol-creatinine ratio, ACTH stimulation test, and LDDS test.

- B) Catecholamine-Producing: Pheochromocytoma is a tumor derived from the chromaffin cells of the adrenal medulla; it is relatively common in dogs, but quite rare in cats. These cases should be considered malignant until proven otherwise. Invasion/entrapment/compression of the caudal vena cava is common. Mural invasion or luminal narrowing of the aorta, renal vessels, adrenal vessels, and hepatic veins may also occur.
- Clinical signs associated with this type of tumor are usually related to the invasion of local structures, metastases, or the secretion of catecholamines. The most common clinical signs of excess catecholamines include generalized weakness, episodic collapse, tachypnea, panting, tachycardia, and cardiac arrhythmias. Catecholamine release and hypertension tends to be episodic; thus, failure to document systemic hypertension does not rule out pheochromocytoma.
  - Ultrasound: The contralateral adrenal gland is usually normal in size and shape. Pheochromocytomas do not typically calcify.
  - Tests: Many of the clinical signs and blood pressure alterations are similar for pheochromocytoma and ADH. It is therefore important to rule out ADH before focusing on pheochromocytoma. The diagnosis prior to surgery is primarily one of exclusion. Specific hormonal tests, such as those that measure urinary catecholamine concentrations or their metabolites, are not routinely performed.
- C) Aldosterone-Secreting (rare in dogs and cats):
- Clinical signs (Conn's Syndrome) are related to excessive secretion of aldosterone, which causes sodium retention and potassium depletion. The resulting symptoms include lethargy, weakness, mild hypernatremia, severe hypokalemia (usually < 3.0 mEq/L), and systemic hypertension.
  - Ultrasound usually reveals a normal contralateral adrenal gland.
  - Tests: Documenting increased plasma aldosterone concentrations before and after ACTH administration is a means of confirming the diagnosis. If weakness and severe hypokalemia are present, plasma aldosterone concentrations can be measured along with plasma cortisol concentrations during the ACTH stimulation test.
- D) Progesterone-Secreting: Although a functional tumor arising from the zona reticularis of the adrenal cortex could secrete excessive amounts of estrogen, progesterone, or testosterone, to date only progesterone-secreting adrenocortical tumors in cats have been documented.
- Clinical signs include: diabetes mellitus and feline fragile skin syndrome, which is characterized by progressively worsening dermal and epidermal atrophy, patchy endocrine alopecia, and easily torn skin.
  - Ultrasound usually reveals a normal contralateral adrenal gland.
  - Tests: Diagnosis requires documenting an increased plasma progesterone concentration. The clinical features mimic feline hyperadrenocorticism, which is the primary differential diagnosis. Pituitary-adrenocortical axis test results are normal to suppressed in cats with progesterone-secreting adrenal tumors.
- E) Deoxycorticosterone-Secreting (rare):
- Clinical signs are related to mineralocorticoid activity and include weakness, marked hypokalemia, and systemic hypertension.

- b. Tests: Increased plasma deoxycorticosterone and non-detectable plasma aldosterone concentrations have been documented in dogs.
- F) 17-OH-progesterone-Secreting (rare):
- a. Clinical signs are similar to hyperadrenocorticism.
  - b. Tests: Pre- and post-ACTH stimulation plasma 17-OH-progesterone concentrations will be increased.

**Treatment:** If hormonal tests for ADH and serum electrolytes are normal and clinical signs suggestive of pheochromocytoma are present, one can assume the adrenal mass is a pheochromocytoma and begin treatment with an alpha-adrenergic antagonist (ex. phenoxybenzamine at 0.25 mg/kg PO BID initially) for at least 2 weeks to prevent severe clinical manifestations of hypertension and promote a smooth anesthetic induction if adrenalectomy is planned. Adjustments to the dose are based on clinical response; an increase in the dose should be considered if clinical signs do not improve after 2 weeks of treatment. If hormonal tests for ADH and serum electrolyte concentrations are normal, clinical signs suggestive of pheochromocytoma are not present, but an adrenalectomy is nevertheless planned, one should still assume the adrenal mass is a pheochromocytoma and begin phenoxybenzamine treatment prior to adrenalectomy.

When a cortisol-producing adrenal tumor has been documented, medical therapy with trilostane (5-20mg/kg PO Q24hr) or mitotane (25-50 mg/kg PO Q24hr for 10 days, then every 4-7 days) should be considered.

The biggest dilemma is whether to perform an adrenalectomy if hormonal tests for hyperadrenocorticism and serum electrolyte concentrations are normal, and clinical signs and systemic hypertension suggestive of pheochromocytoma are not present.

An aggressive approach—adrenalectomy—is based on the assumption that the mass is malignant until proven otherwise and should be removed before metastasis has occurred. In theory, this approach would offer the best chance for long-term survival; however, the age of the patient, the size of the mass, the presence of concurrent diseases, the level of invasion into other organs, and the probability that metastases already exist should factor into the decision. Poor surgical candidates generally include: dogs compromised from the effects of hypercortisolis; older animals; animals with concurrent disease; those for whom invasion has been aggressive and surgical or post-surgical complications are likely; animals with very large masses that have likely already metastasized; and those with documented potential metastatic disease. In addition, adrenalectomy may not be indicated when the mass is small (< 3 cm diameter) and nonfunctional, and the patient is healthy. Reports suggest that there is an approximate 45% success rate of surgical resection of adrenal masses, with a positive prognosis inversely proportionate to tumor size.

In cases of concurrent hepatic nodular changes, liver biopsy samples can be obtained at surgery in cases of suspicious lesions visualized by ultrasound. Hyperadrenocorticism often causes benign nodular hyperplasia of the liver and should not be automatically interpreted as a sign of hepatic metastasis during

ultrasonographic examination. Rather, suspect lesions should be confirmed and biopsied either at surgery or via ultrasound-guided FNA or core biopsy. Post-operative complications include delayed wound healing due to excessive corticoid circulation and wasting, hemorrhage, sepsis, and thromboembolism.

When surgery is a risk and a functional adrenal tumor has been documented, medical therapy, as outlined above, should be considered. Medical therapy will not impede metastatic events. An alternative approach in these cases is to determine the rate of growth of the mass by repeating abdominal ultrasounds initially at 2, 4, and 6 months. If the adrenal mass does not change in size, the time between ultrasound evaluations can be increased to every 4-6 months; however, if the adrenal mass is increasing in size, adrenalectomy should be considered.

**Conclusion:** Any incidentally discovered adrenal tumor warrants investigation into functionality and metastasis. The course of treatment for each case depends largely on which hormones are secreted by the adrenal tumor. Each case should be carefully evaluated on an individual basis before adrenalectomy is considered for aggressive tumors.

**References:**

Behrend EN, Kooistra HS, Nelson R, et al. Diagnosis of Spontaneous Canine Hyperadrenocorticism: 2012 ACVIM Consensus Statement (Small Animal). *J Vet Intern Med* 2013;27:1292–1304 .

Heorauf A, Reusch C. Ultrasonographic characteristics of both adrenal glands in 15 dogs with functional adrenocortical tumors. *J Am Anim Hosp Assoc* 1999;35(3):193-99.

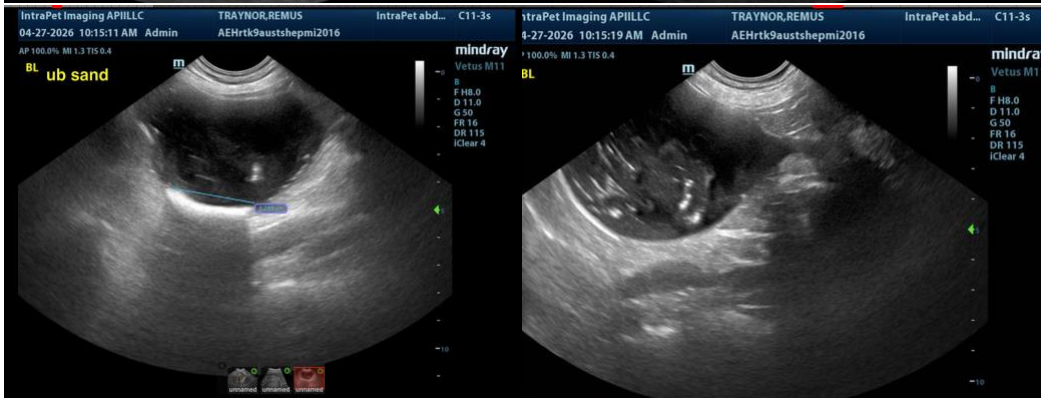
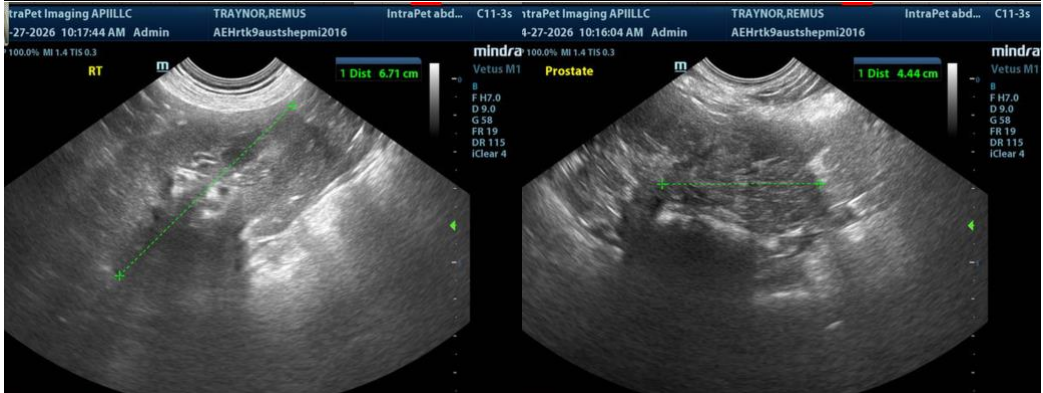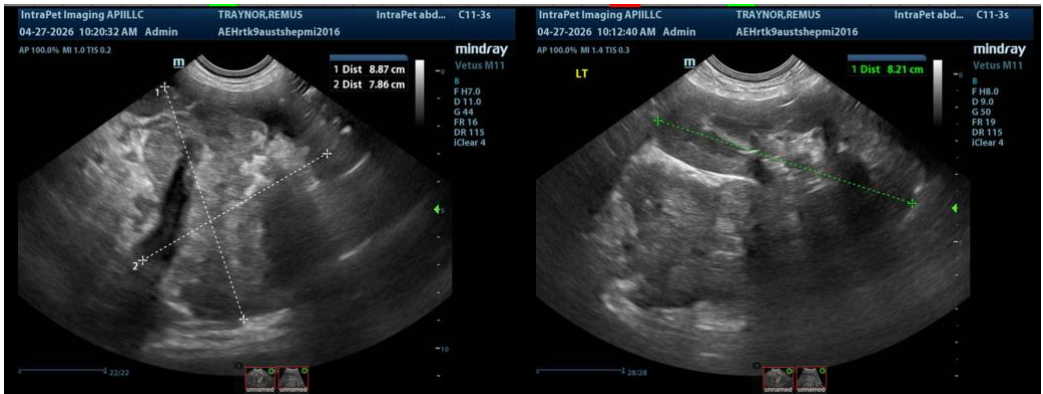
Herrara MA, Mehl ML, Kass PH, et al. Predictive factors and the effect of phenoxybenzamine on outcome in dogs undergoing adrenalectomy for pheochromocytoma. *J Vet Intern Med* 2008;22(6):1333-39.

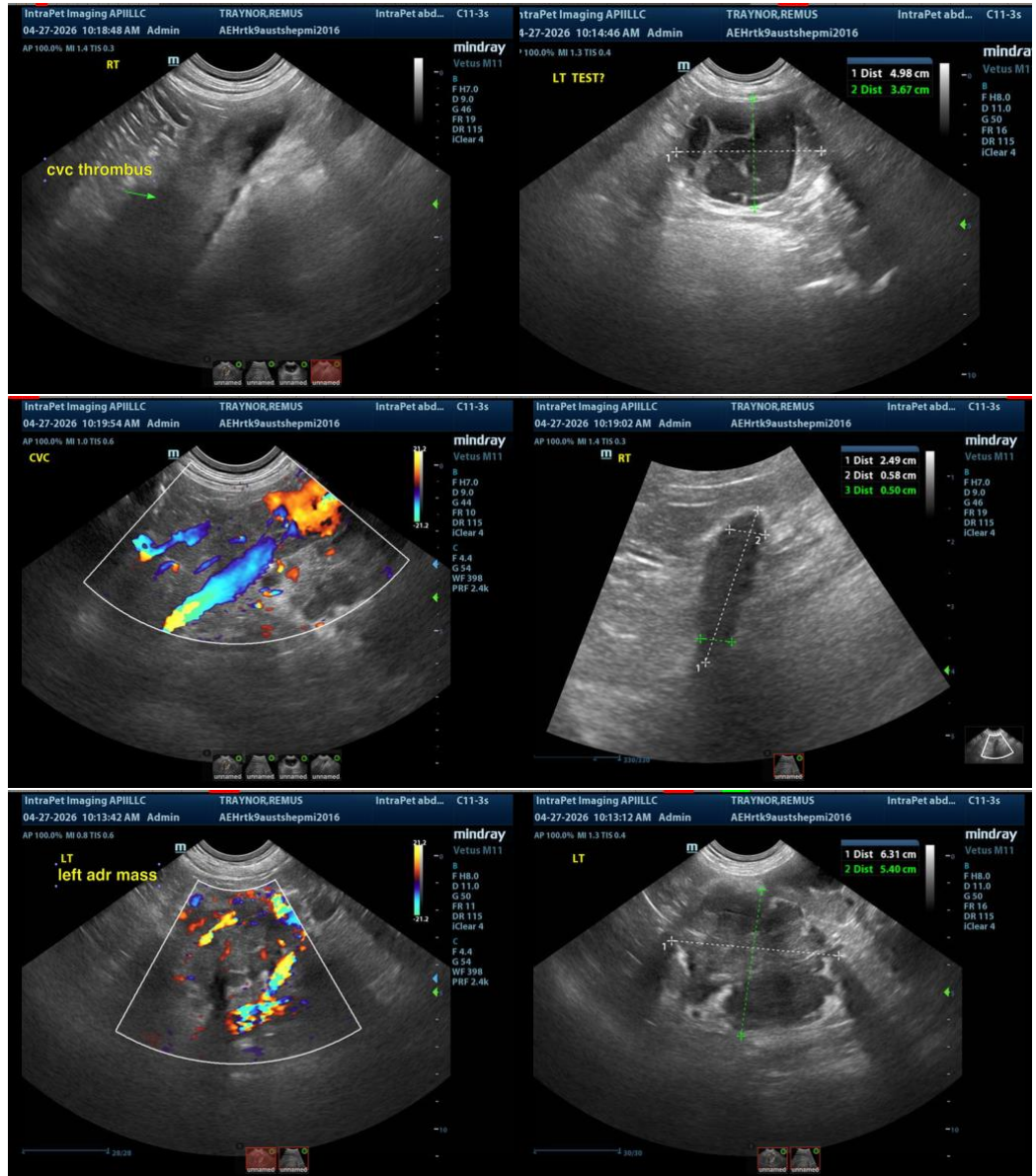
Nelson, RW. Diagnostic approach to the incidental adrenal mass. World Small Animal Veterinary Association World Congress, Granada, Spain, 3-5 October, 2002.

Syme HM, Scott-Moncrieff JC, Treadwell NG, et al. Hyperadrenocorticism associated with excessive sex hormone production by an adrenocortical tumor in two dogs. *J Am Vet Med Assoc* 2001;219(12):1725-28.

Withrow, S. Management of endocrine neoplasia. World Small Animal Veterinary Association World Congress, Vancouver, BC, 8-11 August, 2001.

von Dehn BJ, Nelson RW, Feldman EC, Griffey SM. Pheochromocytoma and hyperadrenocorticism in dogs: six cases (1982-1992). *J Am Vet Med Assoc* 1995;207(3):322-24.





The information and recommendations provided are based on the images presented by the referring veterinarian/sonographer. No evaluation can be communicated regarding pathology that was not visible in the image/video clips provided.

Thank you for this referral. If the clinical or image interpretation does not parallel your findings or if I can be of any further assistance, please contact me.

**Eric Lindquist, DMV, DABVP(CFM), Cert. IVUSS,**

CEO, Owner, Founder -- SonoPath.com

[info@SonoPath.com](mailto:info@SonoPath.com)