



PATIENT

Orion Loveless

SPECIES

Feline

BREED

Domestic Shorthair

SEX

Male

AGE

15 years

WEIGHT

8.7 lbs

INTERPRETED BY

Eric Lindquist, DMV
DABVP, Cert. IVUSS

IMAGING PERFORMED BY

Dr. Levy

HOSPITAL NAME

Court Street VH

REFERRING VET

Dr. Miller

INVOICE

74882

DATE

4/27/26

PRESENTING CLINICAL SIGNS

History: Chronic diarrhea (not responsive to metro/ HA diet/ Cobalequin B12)
Weight loss
Chin mass (Sx removal and biopsy pending)
Abnormal PE/Chem/CBC/UA Results: NSF on Chem/ CBC/ UA/ Fecal Ag

ULTRASONOGRAPHIC EXAMINATION OF THE ABDOMEN

Urinary System

The **urinary bladder**, trigone, and pelvic urethra presented normal thicknesses and normal tone. The ureters were not visible which is normal. No uroliths or sediment were visualized and anechoic urine was present. No evidence of inflammatory or neoplastic changes was noted. Ureteral papillae were normal.

The **kidneys** were enlarged with hyperechoic cortical striations noted. The cortices were thickened. The corticomedullary definition was maintained. Both kidneys were at the upper limits of normal in size measuring 4.0 cm each.

Adrenal Glands

Both **adrenal glands** were visualized and recognized as having normal shape, size, position and echogenicity for this breed. The phrenic vasculature, glandular echogenicity and detail were unremarkable. Capsule, cortex, and medullary definition were normal for this age patient. The left adrenal gland measured 0.4 cm. The right adrenal gland measured 0.4 cm.

Spleen

The **spleen** was mildly enlarged with micronodular changes. The spleen was folded upon itself caudally.

Liver

The **liver** images submitted revealed subjectively normal liver size, contour, and structure. Parenchymal echogenicity was naturally coarse and hypoechoic to the spleen. Vascular and biliary tracts were of normal volume with no evidence of congestion. The gallbladder presented acceptably thin walls with primarily anechoic content. The cystic and common bile ducts were normal. No pathological hepatic lymphadenopathy was evident. No overt structural evidence of inflammatory, infiltrative or regenerative pathology was evident.

Gastrointestinal

There was some residual chyme and gas was noted in the **stomach**, yet not pathological. This is consistent with post prandial presentation. Transit of chyme into the small intestine was normal.



PATIENT

Orion Loveless

SPECIES

Feline

BREED

Domestic Shorthair

SEX

Male

AGE

15 years

WEIGHT

8.7 lbs

INTERPRETED BY

Eric Lindquist, DMV
DABVP, Cert. IVUSS

IMAGING PERFORMED BY

Dr. Levy

HOSPITAL NAME

Court Street VH

REFERRING VET

Dr. Miller

INVOICE

74882

DATE

4/27/26

Curvilinear patterns were maintained throughout the GI tract. No evidence of pathology. Small and large intestine demonstrated normal luminal chyme and stool consistency respectively. No obstructive or overt infiltrative disease was noted. No associated abnormal lymphatic activity was noted.

Pancreas

The base and limbs of the **pancreas** were observed to be largely isoechoic to surrounding omental fat. Some parenchymal remodeling, however, with mild deviation from curvilinear normalcy was observed. Pancreatic duct and capsular irregularities were present consistent with age related changes. If pain upon imaging (+ Murphy sign) was present or if the patient is focally painful in subxiphoid palpation then low-grade smoldering chronic pancreatitis should be suspected.

ULTRASONOGRAPHIC FINDINGS

Swollen kidneys with degenerative changes.

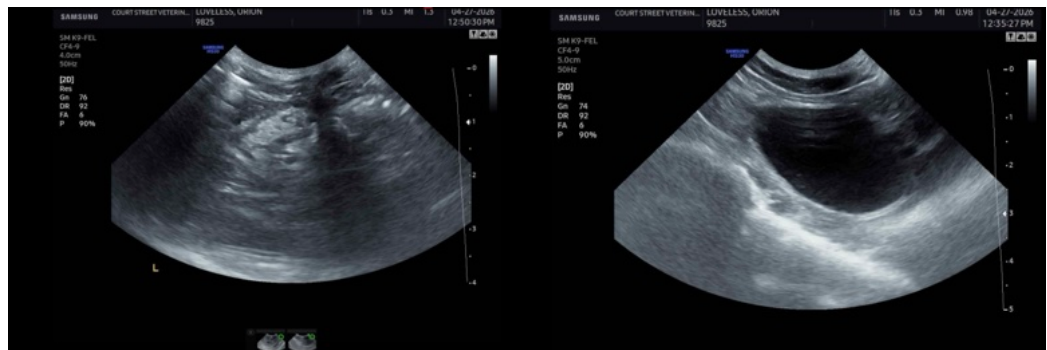
Fluid filled gastric lumen.

Age related pancreas.

INTERPRETATION OF THE FINDINGS & FURTHER RECOMMENDATIONS

Subxiphoid palpation is recommended to assess for pain in the region of the pancreas. Full urinary work-up is warranted. GI protectant protocol is recommended. Medical management for pancreatitis and gastritis is recommended. There was no overt evidence of neoplasia.

Maldigestion panel, three view chest radiographs and full CNS examination is recommended to examine for occult disease that could be responsible for the weight loss. Evaluation for competitive eating environments should also be considered.





PATIENT

Orion Loveless

SPECIES

Feline

BREED

Domestic Shorthair

SEX

Male

AGE

15 years

WEIGHT

8.7 lbs

INTERPRETED BY

Eric Lindquist, DMV
DABVP, Cert. IVUSS

IMAGING PERFORMED BY

Dr. Levy

HOSPITAL NAME

Court Street VH

REFERRING VET

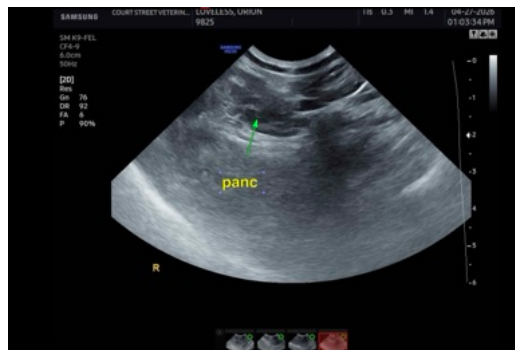
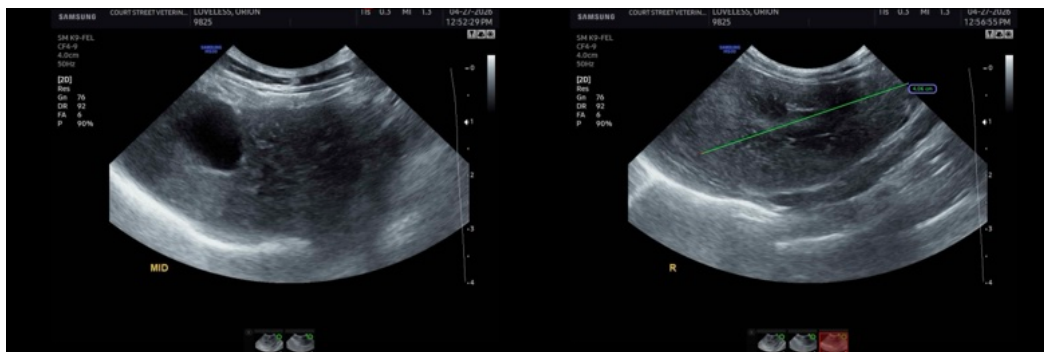
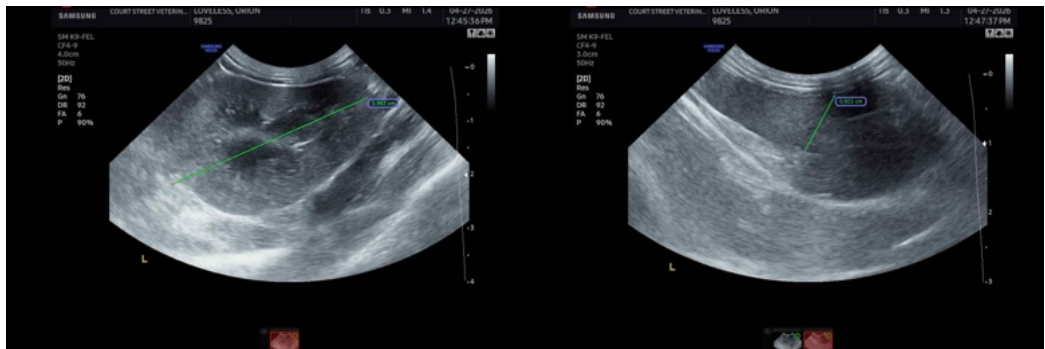
Dr. Miller

INVOICE

74882

DATE

4/27/26



The information and recommendations provided are based on the images presented by the referring veterinarian/sonographer. No evaluation can be communicated regarding pathology that was not visible in the image/video clips provided.

Thank you for this referral. If the clinical or image interpretation does not parallel your findings or if I can be of any further assistance please contact me.

Eric Lindquist, DMV, DABVP (CFM), Cert. IVUSS, CEO of SonoPath.com

info@SonoPath.com