



PATIENT

Harley Bonventre

SPECIES

Canine

BREED

Hound Mix

SEX

Spayed female

AGE

12 years

WEIGHT

29 kg

INTERPRETED BY

Eric Lindquist, DMV
DABVP, Cert. IVUSS

IMAGING PERFORMED BY

Matthew Olcha

HOSPITAL NAME

East Meadow VC

REFERRING VET

Dr. Olcha

INVOICE

74884

DATE

4/27/26

PRESENTING CLINICAL SIGNS

History: Presented for PUPD, signs seem to have improved somewhat on clavamox. Ionized calcium and PTH pending. Chest x-rays unremarkable. Rectal exam unremarkable. Hypercalcemia noted on chemistry. Bacteriuria on UA. Possible liver mass noted on AFAST following urine collection

ULTRASONOGRAPHIC EXAMINATION OF THE ABDOMEN

Urinary System

The **urinary bladder**, trigone, and pelvic urethra presented normal thicknesses and normal tone. The pelvic urethra was imaged 1.0 cm beyond the cystourethral junction and appeared normal. The ureters were not visible which is normal. No uroliths or sediment were visualized and anechoic urine was present. No evidence of inflammatory or neoplastic changes was noted. Ureteral papillae were normal.

The **kidneys** revealed normal size and structure, corticomedullary definition and ratio for this age. The cortices presented largely uniform texture with normal echogenic relationship to liver and spleen. Medullary structure differed distinctly from the cortex. The capsules were acceptably uniform without significant irregularities. The left kidney measured 6.0 cm. The right kidney revealed slight pyelectasia noted. The right kidney measured 6.9 cm.

Adrenal Glands

Both **adrenal glands** were visualized and recognized as having normal shape, size, position and echogenicity for this breed. The phrenic vasculature, glandular echogenicity and detail were unremarkable. Capsule, cortex, and medullary definition were normal for this age patient. The left adrenal gland measured 0.5 cm. The right adrenal gland measured 0.7 cm at the caudal pole.

Spleen

The **spleen** presented a smooth homogeneous parenchyma hyperechoic to liver and renal cortical parenchyma. The capsule was smooth without noticeable expansion or deviation from within the spleen or adjacent pathology. Hyperechoic lipid plaques were noted, yet not pathological. The splenic vasculature demonstrated normal volume without signs of congestion or thrombosis. No sonographic evidence of acute or chronic inflammatory, neoplastic, or infarctual changes was noted.

Liver

The **liver** images from right and left intercostal as well as subcostal views revealed subjectively normal liver size, contour, and structure. Some age-related parenchymal remodeling was noted but likely not clinically significant at this time. The caudal aspect of the left liver revealed a hepatomatous or adenomatous type mass that measured 3.7 cm. Vascular and biliary tracts were of normal volume and no evidence of congestion was noted. The gallbladder presented some dependent debris with essentially normal contour. The cystic and common bile ducts were normal. No overt evidence of active



PATIENT

Harley Bonventre

SPECIES

Canine

BREED

Hound Mix

SEX

Spayed female

AGE

12 years

WEIGHT

29 kg

INTERPRETED BY

Eric Lindquist, DMV
DABVP, Cert. IVUSS

IMAGING PERFORMED BY

Matthew Olcha

HOSPITAL NAME

East Meadow VC

REFERRING VET

Dr. Olcha

INVOICE

74884

DATE

4/27/26

inflammatory, infiltrative or regenerative pathology was noted but should be paired with current or past LE elevations regarding any clinical significance to this presentation. The hepatic lymph nodes were unremarkable.

Gastrointestinal

There was some residual chyme and gas was noted in the **stomach**, yet not pathological. This is consistent with post prandial presentation. Transit of chyme into the small intestine was normal. Curvilinear patterns were maintained throughout the GI tract. No evidence of pathology. Small and large intestine demonstrated normal luminal chyme and stool consistency respectively. No obstructive or overt infiltrative disease was noted. No associated abnormal lymphatic activity was noted.

Pancreas

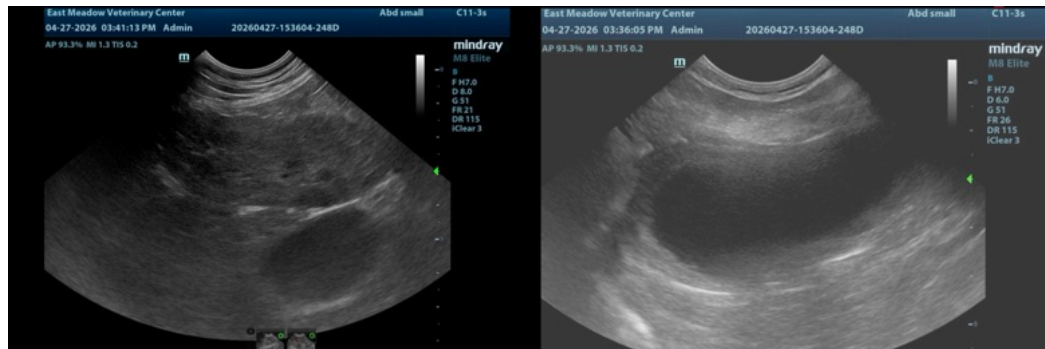
The base and limbs of the **pancreas** were observed to be largely isoechoic to surrounding omental fat. Pancreatic duct and capsular contour were acceptably normal and parenchyma respected normal curvilinear patterns. No overt evidence of active inflammatory or neoplastic disease was noted.

ULTRASONOGRAPHIC FINDINGS

Slight renal pyelectasia with hepatomatous or adenomatous type liver mass.
Structurally normal adrenal glands.

INTERPRETATION OF THE FINDINGS & FURTHER RECOMMENDATIONS

FNA of the liver mass is warranted. The mass appears resectable. Differentials include adenoma, adenocarcinoma less likely. Hyperplasia is possible. The cause of hypercalcemia is not evident in abdomen. Anal gland palpation and imaging, chest radiographs and spinal radiographs +/- parathyroid ultrasound would be appropriate depending upon hypercalcemia results.





PATIENT

Harley Bonventre

SPECIES

Canine

BREED

Hound Mix

SEX

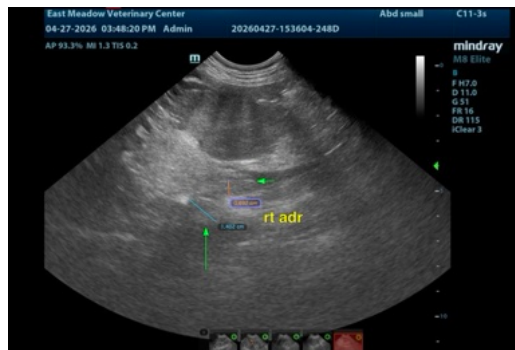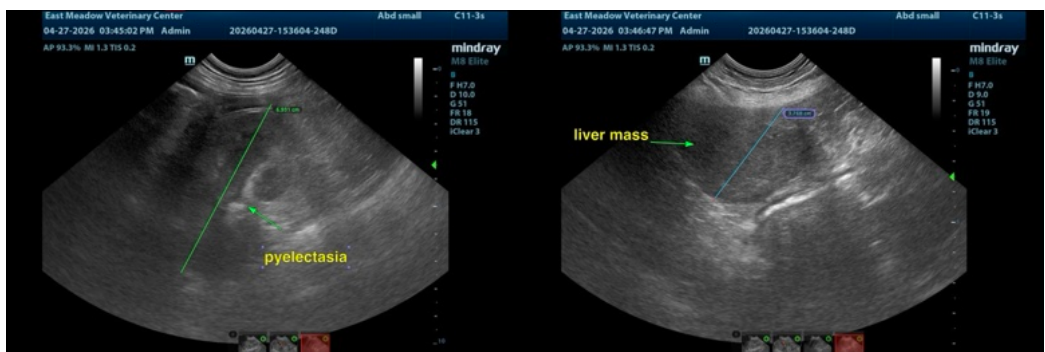
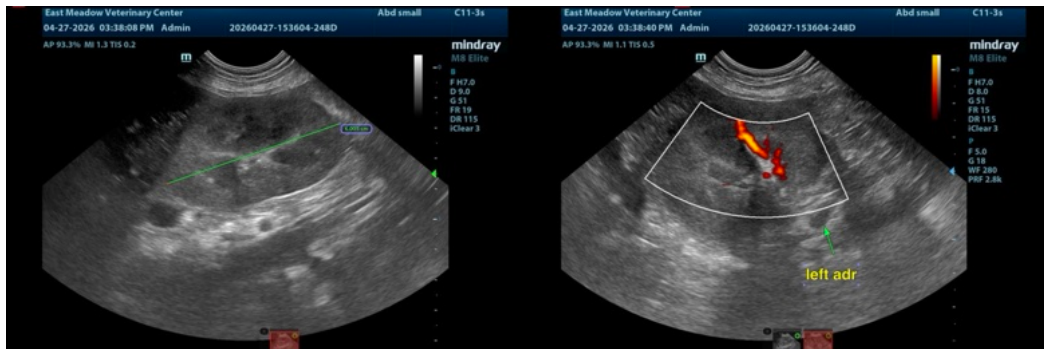Spayed female

AGE

12 years

WEIGHT

29 kg



INTERPRETED BY

Eric Lindquist, DMV
DABVP, Cert. IVUSS

IMAGING PERFORMED BY

Matthew Olcha

HOSPITAL NAME

East Meadow VC

REFERRING VET

Dr. Olcha

INVOICE

74884

DATE

4/27/26

The information and recommendations provided are based on the images presented by the referring veterinarian/sonographer. No evaluation can be communicated regarding pathology that was not visible in the image/video clips provided.

Thank you for this referral. If the clinical or image interpretation does not parallel your findings or if I can be of any further assistance please contact me.

Eric Lindquist, DMV, DABVP (CFM), Cert. IVUSS, CEO of SonoPath.com

info@SonoPath.com

Excerpt from the Curbside Guide: <https://sonopath.com/thecurbsideguide/>

Polyuria and Polydipsia (PU/PD)



PATIENT

Harley Bonventre

SPECIES

Canine

BREED

Hound Mix

SEX

Spayed female

AGE

12 years

WEIGHT

29 kg

INTERPRETED BY

Eric Lindquist, DMV
DABVP, Cert. IVUSS

IMAGING PERFORMED BY

Matthew Olcha

HOSPITAL NAME

East Meadow VC

REFERRING VET

Dr. Olcha

INVOICE

74884

DATE

4/27/26

DESCRIPTION Polyuria and polydipsia (PU/PD) often occur together and are a common complaint in small animal practice. Given the many differential diagnoses for PU/PD and the diagnostic challenge associated with ruling in or out the various disease processes, one should follow a systematic approach when confronted with PU/PD cases. Causes can be categorized in two ways: 1) using an assessment of specific gravity, i.e., solute diuresis (specific gravity 1.008–1.024) and water diuresis (specific gravity 1.001–1.007), and 2) undertaking a clinical evaluation of diseases caused by primary renal disease or extrarenal causes of PU/PD. The following is a reference list of differential diagnoses one can use to categorize PU/PD according to renal or extrarenal disease:

Renal Disease	Extrarenal Disease	
Acute Renal Failure	Hyperadrenocorticism	Hypercalcemia
Chronic renal failure	Hypoadrenocorticism	Hyponatremia
Glomerulonephritis	Diabetes Mellitus	Hypokalemia
Primary glucosuria (Fanconi's)	Hyperthyroidism (cats)	Liver failure
Pyelonephritis	Acromegaly	Pheochromocytoma
Non-azotemic renal disease	Pyometra	Polycythemia
Leptospirosis	-Postobstructive diuresis -Salt Supplementation -Drugs (e.g., diuretics, prednisone) -Atypical Cushing's -SARDS -Medullary washout	-Paraneoplastic -Pericardial effusion -Hypertension -Central diabetes insipidus -Nephrogenic diabetes insipidus -Psychogenic water intake

A final diagnosis of psychogenic PU/PD is very rare and is always a diagnosis of exclusion.

CLINICAL SIGNS Clinical signs include excessive thirst and urination. Whereas normal intake ranges from 60–80 mL/kg/day, excessive thirst is classified as drinking upwards of 100 mL/kg/day. Excessive urination is deemed to be a urine output greater than 50 mL/kg/day (normal output ranges from 20–40 mL/kg/day). The signs may manifest as abnormal intake behavior and even water seeking in profoundly polydipsic patients, as well as urinary accidents in the house.

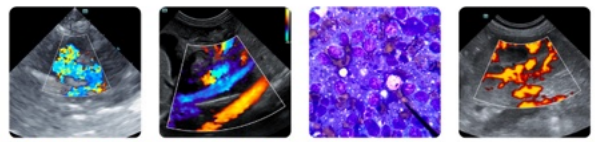
DIAGNOSTICS The diagnostic approach to PU/PD can be daunting given the large number of differentials listed above. First, one must evaluate signalment, patient history, and the results of a physical examination to determine clues that point to potential causes of PU/PD. For example, diabetes may be suspected in a middle-to-older-aged dog experiencing weight loss and polyphagia, hyperthyroidism may be suspected in older cats experiencing weight loss and polyphagia, and pyometra may be suspected in intact female dogs and cats.

Prior to proceeding with expensive diagnostic tests, the presence of PU/PD should be confirmed by measuring water intake over a 2–3-day period at home. Urine specific gravity is also an important screening test as a concentrated urine sample rules out the presence of PU/PD.

BASIC WORKUP Many disease processes can be ruled out through basic blood work. The minimum database includes a CBC, biochemical profile, and urinalysis (UA). The UA is especially important for evaluating specific gravity, glucose or protein loss, and sediment that may indicate infection. A urine protein:creatinine (UPC) and/or microalbumin test should be performed to assess for protein-losing nephropathy (PLN), especially in cases where the urine sample is not concentrated, and a urine dipstick test may yield a false negative. One should take the systemic blood pressure to evaluate for hypertension. A urine culture should also be done to rule out infection and pyelonephritis,

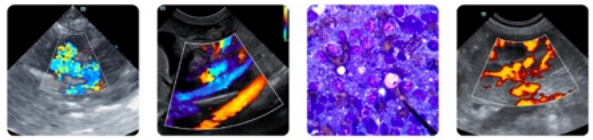


PATIENT	even if there is no evidence of the latter on the ultrasound. One may also consider a trial with antibiotics to see if the PU/PD resolves. It is also necessary to assess the total T4 and/or the free T4 in geriatric cats.
Harley Bonventre	
SPECIES	ABDOMINAL ULTRASOUND The role of abdominal ultrasound is key in the diagnosis of PU/PD as it permits practitioners to evaluate the different organs for potential disease processes. For example, the kidneys can be evaluated for size, as they may be small in the face of chronic renal failure or normal-to-enlarged in cases of acute renal failure. The renal parenchymal echogenicity may be normal or increased in cases of renal disease, and a loss of corticomedullary distinction may also be present in such cases. Mild pyelectasia can be an indication of active or prior pyelonephritis but may also be seen in patients treated with IV fluid therapy. Mild pelvic dilation can be present in patients with chronic renal disease. Patients with obstructed renal pelvises secondary to ureteroliths or strictures demonstrate significantly more dilation of the renal pelvis than those with pyelonephritis or who are undergoing fluid therapy.
Canine	
BREED	The liver should be evaluated for multiple parameters given that liver failure can cause PU/PD or may be indirectly related to diseases that can cause PU/PD. For example, the size will be subnormal in the face of cirrhosis but enlarged in patients with Cushing's and diabetes. Echogenicity, hyperechogenicity, and homogeneity are characteristic of Cushing's disease and diabetes. The liver may be mottled, hypoechoic, or hyperechoic in cases of lymphoma, which can cause hypercalcemia and PU/PD; the notation of hepatic nodules may indicate liver failure or cirrhosis, benign nodular hyperplasia, or malignancy. The adrenal glands can be measured, as they are often, but not always, enlarged in cases of Cushing's disease, whereas they may be small in cases of Addison's. The presence of a mass can indicate an adrenal tumor causing Cushing's disease. The bladder should be assessed for wall thickness, as it may be increased secondary to chronic urinary tract infection (UTI) in cases of diabetes, Cushing's disease, and pyelonephritis. The presence of stones may be secondary to chronic UTI, Cushing's disease, and liver failure (the latter is especially indicated by the presence of ammonium biurate stones). It should be noted that an infection of the lower urinary tract does not cause PU/PD; however, this would predispose the patient to ascending pyelonephritis. The echogenicity of the spleen may be increased or decreased in cases of lymphoma, and the presence of nodules may indicate malignancy or benign nodular hyperplasia.
Hound Mix	
SEX	ADVANCED BLOOD TESTING An ACTH stimulation test or low-dose dexamethasone suppression test must be performed prior to assessing for diabetes insipidus or psychogenic polydipsia.
Spayed female	
AGE	EVALUATION OF RENAL FUNCTION Early renal disease can cause PU/PD without resulting in an elevation in BUN or creatinine. In these cases, SDMA and/or cystatin C would be elevated; however, if SDMA and/or cystatin C is normal, then specific renal function can be assessed practically in hospital using an iohexal clearance test (preferable) or, less commonly, an endogenous creatinine clearance test. The disadvantage of the latter is that it requires 24-hour urine collection with a closed urinary catheter collection system. A more advanced and specific way to evaluate renal function involves using nuclear scintigraphy and measuring the glomerular filtration rate (GFR); however, this procedure is usually only available at select tertiary referral centers. The iohexal clearance test is easily administered and the results are calculated from a computerized model of the GFR. The protocol for administering the test is as follows: the patient should not be fed for 12 hours prior but should be well hydrated. Give 300 mg/kg IV (slow push) and mark the time of injection to the nearest minute. Collect blood samples at two, three, and four hours to the nearest minute, and mark times on the samples. The serum samples should then be submitted to the Michigan State University Diagnostic Lab for a GFR study. Adverse effects of the iohexal are rare, but include anaphylactic/anaphylactoid reactions, hypotension, arrhythmias, acute renal failure, nausea, and vomiting. Pretreatment with diphenhydramine can reduce the occurrence of anaphylactic/anaphylactoid reactions. The normal values for dogs are a mean of 5.48 mL/kg/min and a range of 2.89–8.07 mL/kg/min, and for cats, a mean of 1.94 mL/kg/min and a range of 1.15–2.73 mL/kg/min.
12 years	
WEIGHT	
29 kg	
INTERPRETED BY	
Eric Lindquist, DMV DABVP, Cert. IVUSS	
IMAGING PERFORMED BY	
Matthew Olcha	
HOSPITAL NAME	
East Meadow VC	
REFERRING VET	
Dr. Olcha	
INVOICE	
74884	
DATE	
4/27/26	



PATIENT	The creatinine clearance is then estimated using an equation that considers the creatinine levels in both the serum and the urine, the time of urine collection, and the urine volume. Creatinine clearance = {urine creatinine (mg/dL) X urine volume (mL)} / {time (min) X serum creatinine (mg/dL) X body weight (kg)}. Results are expressed in mL/min/kg. Normal values for dogs are 2.4–5 mL/min/kg and 1.9–5 mL/min/kg for cats. A decrease in the GFR by 66% correlates with isosthenuria, and a decrease of 75% correlates with azotemia.
Harley Bonventre	
SPECIES	
Canine	
BREED	IN SEARCH OF CUSHING'S DISEASE If the estimated renal function is normal and urine specific gravity is consistently < 1.020, then urine cortisol:creatinine ratio (UCCR) should be utilized. If UCCR is elevated in these cases, then a low-dose dexamethasone suppression test (LDDST) or an ACTH stimulation test can be performed to assess for Cushing's disease. In cases where the likelihood of Cushing's is low, a urine cortisol:creatinine ratio (UCCR) can be run on a urine sample obtained at home. If the results are negative, Cushing's disease can be ruled out; however, if they are positive, they are not necessarily conclusive, and additional testing for Cushing's will be required. Combined PCR on serum and urine is the best option for ruling out leptospirosis, especially when paired with convalescent titers 2–3 weeks later to avoid vaccine interference and false positive results. Once all causes of PU/PD other than central diabetes insipidus, primary nephrogenic diabetes insipidus, and psychogenic polydipsia (a diagnosis made by exclusion) have been ruled out, then one can either perform a modified water deprivation test or pursue an even more practical approach: trial therapy with vasopressin to assess response to ADH supplementation. The modified water deprivation test (MWDT) is not typically recommended anymore, as it can result in rapid dehydration and acute renal decompensation in PU/PD patients, especially in those with non-azotemic renal disease.
Hound Mix	
SEX	
Spayed female	
AGE	
12 years	
WEIGHT	
29 kg	
INTERPRETED BY	TRIAL THERAPY WITH DESMOPRESSIN A trial with desmopressin therapy at home may not yield a definitive diagnosis but can be less expensive and safer than performing a MWDT. The desmopressin can be given as an intraconjunctival drop twice daily; the urine specific gravity and water intake should be measured after one week. Alternatively, and likely easier, the desmopressin can be given as an oral tablet. Current dosage recommendations are 0.1 mg tablet/20 kg dog PO TID for seven days or 0.2 mg tablet/40 kg dog PO TID for seven days; urine specific gravity and water consumption should be reevaluated after this time. If the water intake dramatically decreases and the urine specific gravity increases by more than 50%, then this is strongly indicative of chronic kidney disease, provided Cushing's has been ruled out. It is recommended that one attempts to reestablish the medullary concentration gradient before trial therapy. This would entail gradually reducing the patient's water intake to within normal range (60–80 mL/kg/day) over several days prior to initiating the desmopressin therapy. This should only be done once the possibility of non-azotemic renal disease has been excluded using renal function testing.
Eric Lindquist, DMV DABVP, Cert. IVUSS	
IMAGING PERFORMED BY	
Matthew Olcha	
HOSPITAL NAME	
East Meadow VC	
REFERRING VET	TREATMENT Treatment for secondary causes of PU/PD is based on the primary disease that is diagnosed. For example, specific therapy for cases of Cushing's disease, diabetes mellitus, or pyelonephritis would be implemented first before treating for PU/PD specifically. In other words, the actual resolution of PU/PD depends on the etiology. Therapy for central diabetes insipidus is based on the supplementation of an exogenous form of ADH. Desmopressin intranasal spray (1–4 drops in the conjunctival sac Q12–24hr, titrated to resolve the PU/PD) is most commonly used. Oral desmopressin can also be tried, although an exact dose is unknown and reported dosing strategies vary depending on the source (e.g., the dose range is 1/4–1/2 of a 0.1–0.2 mg tablet PO Q12–24hr or 0.1–0.2 mg PO Q8hr; adjust as needed to control signs). Additional medical therapy for partial central diabetes insipidus consists of enhancing the effects of ADH at the level of the kidney using chlorpropamide or thiazide diuretics and feeding the patient a diet low in sodium. Congenital nephrogenic diabetes insipidus is treated with salt restriction and thiazide diuretics. Psychogenic PU/PD can be managed with slow gradual water restriction. The therapies for partial central diabetes insipidus, primary nephrogenic diabetes insipidus, and psychogenic polyuria are not fully effective.
Dr. Olcha	
INVOICE	
74884	
DATE	
4/27/26	

REFERENCES



PATIENT

Harley Bonventre

SPECIES

Canine

BREED

Hound Mix

SEX

Spayed female

AGE

12 years

WEIGHT

29 kg

INTERPRETED BY

Eric Lindquist, DMV
DABVP, Cert. IVUSS

IMAGING PERFORMED BY

Matthew Olcha

HOSPITAL NAME

East Meadow VC

REFERRING VET

Dr. Olcha

INVOICE

74884

DATE

4/27/26

1. Bexfield NH, Heiene R, Gerritsen RJ, et al. Glomerular filtration rate estimated by 3 sample plasma clearance of Iohexal in 118 healthy dogs. *J Vet Intern Med* 2008; 22: 66-73.
2. Bruyette D: Approach to the Patient with Polyuria and Polydipsia. World Small Animal Veterinary Association World Congress Proceedings 2015.
3. Feldman EC and Nelson RW. Water metabolism and diabetes insipidus. In: Feldman EC and Nelson RW, eds. *Canine and Feline Endocrinology and Reproduction, 2nd ed.* Philadelphia, PA: WB Saunders; 1996: 2-37.
4. Shiel RC. Polyuria and polydipsia. In: Ettinger SJ, Feldman EC, Cote E, eds. *Textbook of Small Animal Internal Medicine, 8th ed.* Saint Louis, MO: Elsevier; 2017: 181-85.
5. Galgut B: Understanding the Polyuric/Polydipsic Animal. Western Veterinary Conference Proceedings 2013.
6. Shiel RE. Diabetes insipidus. In: Ettinger SJ, Feldman EC, Cote E, eds. *Textbook of Small Animal Internal Medicine, 7th ed.* Saint Louis, MO: Elsevier; 2017: 1710-14.