



PATIENT

Buster Williamson

SPECIES

Canine

BREED

Toy Poodle

SEX

Neutered male

AGE

12 years

WEIGHT

11.2 lbs

INTERPRETED BY

Eric Lindquist, DMV
DABVP, Cert. IVUSS

IMAGING PERFORMED BY

Bill McGee DVM,
DABVP

HOSPITAL NAME

Bridgeport AH PLLC

REFERRING VET

Dr. Harris

INVOICE

74898

DATE

4/27/26

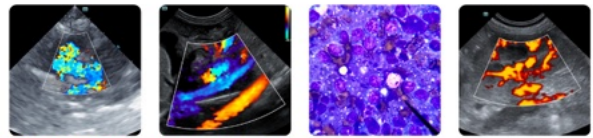
PRESENTING CLINICAL SIGNS

History: Harsh cough, tires easily, grade 5of6 murmur

ULTRASONOGRAPHIC EXAMINATION OF THE ABDOMEN

The echocardiogram in this patient demonstrated enlarged **left atrial** size based on 3 different LA measurement methods. Chamber volumes and echogenicity were normal. The cranial and caudal **mitral** valve leaflets presented vegetative thickening consistent with endocardiosis. Prolapse of the mitral valve leaflet was noted. Doppler indicated measurable insufficiency. The **left ventricle** presented normal thicknesses with linear contour and was not dilated nor restricted. The **myocardium** presented normal echogenicity without subjective evidence of significant fibrotic or ischemic disease. **Contractility** of the ventricular walls was adequate and in normal range for this patient evidenced by the fractional shortening measurement and subjective evaluation of the different regions of the myocardium. The **left ventricular outflow** tract demonstrated normal laminar flow and subjective structural integrity. The **right atrium** and auricle revealed normal size, structure and content. No evidence of masses was noted or chamber overload. **Tricuspid** valvular assessment demonstrated adequate linear morphology. The **right ventricle** was of normal size (1/3 diameter of LV), chordae structure, myocardial echogenicity and thickness. **Pulmonic** tract assessment revealed normal valve structure, laminar flow, and diameter (approx.1:1 pa/ao ratio). No visible **pericardial** or free pleura fluid was noted. No echographically detectable evidence of infiltrative disease was visible. The cranial **mediastinum and pericardial regions** were free of masses in the visible window. Tachycardia was noted.

CANINE CARDIAC PARAMETERS	MR VMAX (m/s)	TR VMAX (m/s)	LA/AO	LA/AO (Heart Base)	FS (%)	EF (%)	EPSS (cm)
NORMAL PARAMETER	4.5-5.5	<2.7	1.3	<1.6	28-40	40-100	<0.6
PATIENT	>5.0	-	NM	2.1	50	83	0.6
CANINE CARDIAC PARAMETERS	HR (BPM)	AV VMAX (m/s)	PV MAX (m/s)	BODY WEIGHT	LA 2D short axis Base view (cm)	LVIDd Avg; 2D and m-mode short axis (cm)	LVIDs Avg; 2D and m-mode short axis (cm)
NORMAL PARAMETER	50-100	0.7-1.7	0.7-1.6	BELOW	BELOW	BELOW	BELOW
PATIENT	200	1.1	0.9	11.2 lbs	3.5	3.25	



PATIENT

Buster Williamson

SPECIES

Canine

BREED

Toy Poodle

SEX

Neutered male

AGE

12 years

WEIGHT

11.2 lbs

INTERPRETED BY

Eric Lindquist, DMV
DABVP, Cert. IVUSS

IMAGING PERFORMED BY

Bill McGee DVM,
DABVP

HOSPITAL NAME

Bridgeport AH PLLC

REFERRING VET

Dr. Harris

INVOICE

74898

DATE

4/27/26

ULTRASONOGRAPHIC FINDINGS

Mitral valve prolapse.

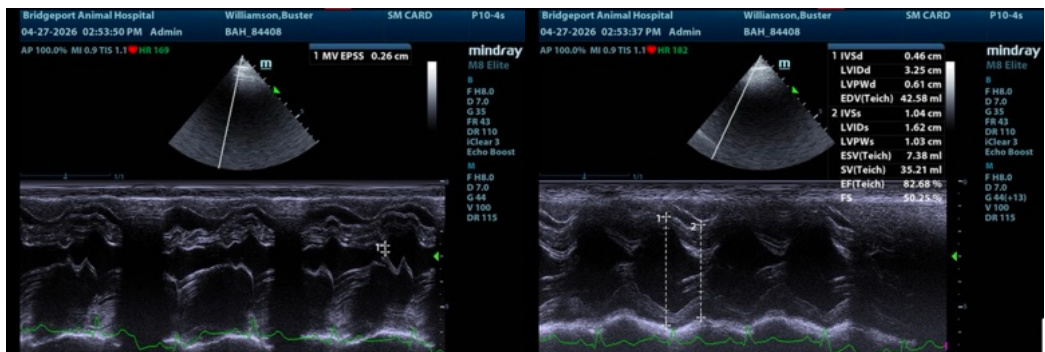
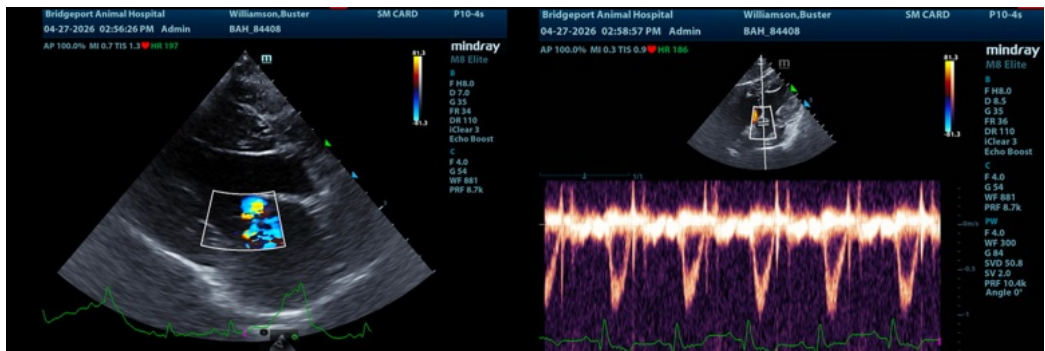
Left atrial enlargement.

Advanced stage B2-B2+ valvular disease.

Tachycardia.

INTERPRETATION OF THE FINDINGS & FURTHER RECOMMENDATIONS

I recommend Pimobendan at 0.3 mg/kg b.i.d., ace inhibitor at 0.5 mg/kg s.i.d. progressing to b.i.d. and Spironolactone at 1-2 mg/kg s.i.d. EKG is indicated. The cough may be owing to main stem bronchus impingement depending on radiograph results.





PATIENT

Buster Williamson

SPECIES

Canine

BREED

Toy Poodle

SEX

Neutered male

AGE

12 years

WEIGHT

11.2 lbs

INTERPRETED BY

Eric Lindquist, DMV
DABVP, Cert. IVUSS

IMAGING PERFORMED BY

Bill McGee DVM,
DABVP

HOSPITAL NAME

Bridgeport AH PLLC

REFERRING VET

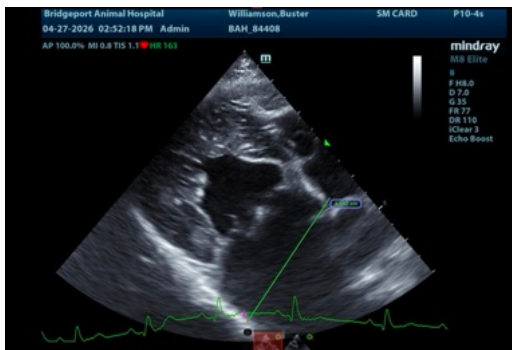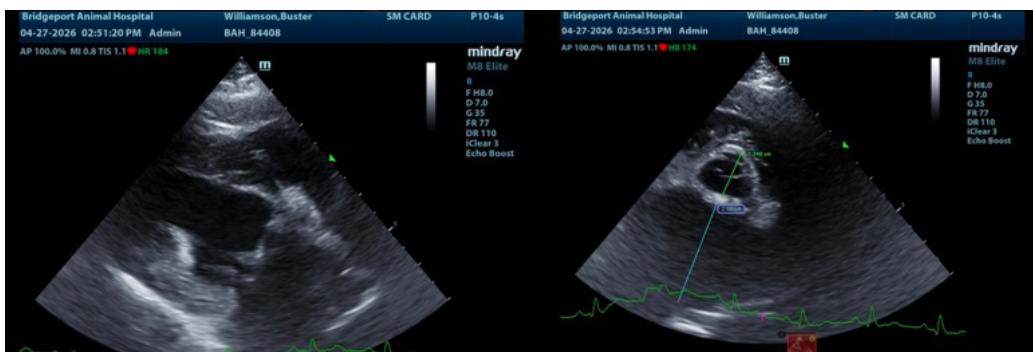
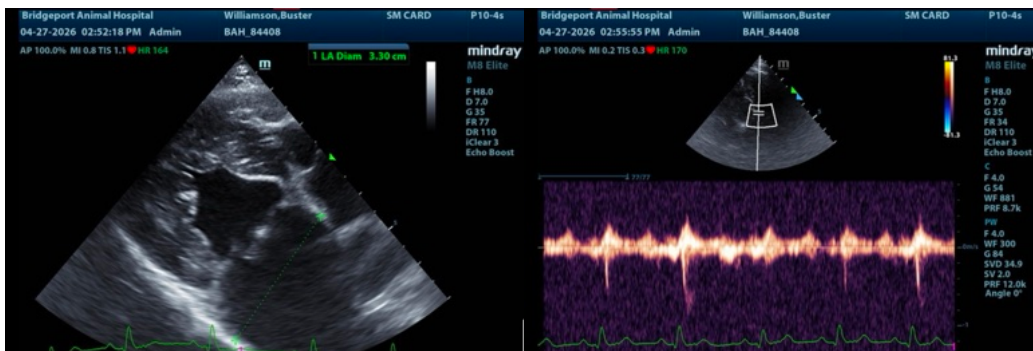
Dr. Harris

INVOICE

74898

DATE

4/27/26



The information and recommendations provided are based on the images presented by the referring veterinarian/sonographer. No evaluation can be communicated regarding pathology that was not visible in the image/video clips provided.

Thank you for this referral. If the clinical or image interpretation does not parallel your findings or if I can be of any further assistance please contact me.

Eric Lindquist, DMV, DABVP (CFM), Cert. IVUSS, CEO of SonoPath.com

info@SonoPath.com