



## PATIENT

Bandit Beaudet

## SPECIES

Canine

## BREED

Shih Tzu Cross

## SEX

Neutered male

## AGE

5 years

## WEIGHT

6.8 lbs

## INTERPRETED BY

Eric Lindquist, DMV  
DABVP, Cert. IVUSS

## IMAGING PERFORMED BY

Gudrun Gunther

## HOSPITAL NAME

New Frontier Animal  
Medical Center

## REFERRING VET

Dr. Gunther

## INVOICE

74897

## DATE

4/27/26

## PRESENTING CLINICAL SIGNS

History: Patient is feeling much better! Today is his first day off of all pain meds and he is moving really well. We were able to do all of his imaging with no sedation and he was very comfortable for the whole thing

## ULTRASONOGRAPHIC EXAMINATION OF THE ABDOMEN

### Urinary System

The **urinary bladder**, trigone, and pelvic urethra presented normal thicknesses and normal tone. The ureters were not visible which is normal. No uroliths or sediment were visualized and anechoic urine was present. No evidence of inflammatory or neoplastic changes was noted. Ureteral papillae were normal.

The **kidneys** revealed normal size and structure, corticomedullary definition and ratio for this age. The cortices presented largely uniform texture with normal echogenic relationship to liver and spleen. Medullary structure differed distinctly from the cortex. The capsules were acceptably uniform without significant irregularities. The left kidney revealed pyelectasia that measured 0.7 cm and mild irregular contour with slight pericapsular enhanced fat and trace amounts of fluid. The pyelectasia may resolve and it is debatable on whether this will cause eventual dysfunction if it remains. The left kidney measured 3.7 cm and the right kidney measured 3.5 cm.

### Adrenal Glands

Both **adrenal glands** were visualized and recognized as having normal shape, size, position and echogenicity for this breed. The phrenic vasculature, glandular echogenicity and detail were unremarkable. Capsule, cortex, and medullary definition were normal for this age patient. The left adrenal gland measured 1.45 x 0.2 cm at the cranial pole and 0.2 cm at the caudal pole. The right adrenal gland measured 1.59 x 1.26 cm.

### Spleen

The **spleen** presented a smooth homogeneous parenchyma hyperechoic to liver and renal cortical parenchyma. The capsule was smooth without noticeable expansion or deviation from within the spleen or adjacent pathology. The splenic vasculature demonstrated normal volume without signs of congestion or thrombosis. No sonographic evidence of acute or chronic inflammatory, neoplastic, or infarctual changes was noted.

### Liver

The **liver** images submitted revealed subjectively normal liver size, contour, and structure. Parenchymal echogenicity was naturally coarse and hypoechoic to the spleen. Vascular and biliary tracts were of



**PATIENT**

Bandit Beaudet

**SPECIES**

Canine

**BREED**

Shih Tzu Cross

**SEX**

Neutered male

**AGE**

5 years

**WEIGHT**

6.8 lbs

**INTERPRETED BY**

Eric Lindquist, DMV  
DABVP, Cert. IVUSS

**IMAGING PERFORMED BY**

Gudrun Gunther

**HOSPITAL NAME**

New Frontier Animal  
Medical Center

**REFERRING VET**

Dr. Gunther

**INVOICE**

74897

**DATE**

4/27/26

normal volume with no evidence of congestion. The gallbladder presented acceptably thin walls with primarily anechoic content. The cystic and common bile ducts were normal. No pathological hepatic lymphadenopathy was evident. No overt structural evidence of inflammatory, infiltrative or regenerative pathology was evident.

**Gastrointestinal**

There was some residual chyme and gas was noted in the **stomach**, yet not pathological. This is consistent with post prandial presentation. Transit of chyme into the small intestine was normal. Curvilinear patterns were maintained throughout the GI tract. No evidence of pathology. Small and large intestine demonstrated normal luminal chyme and stool consistency respectively. No obstructive or overt infiltrative disease was noted. No associated abnormal lymphatic activity was noted.

**Pancreas**

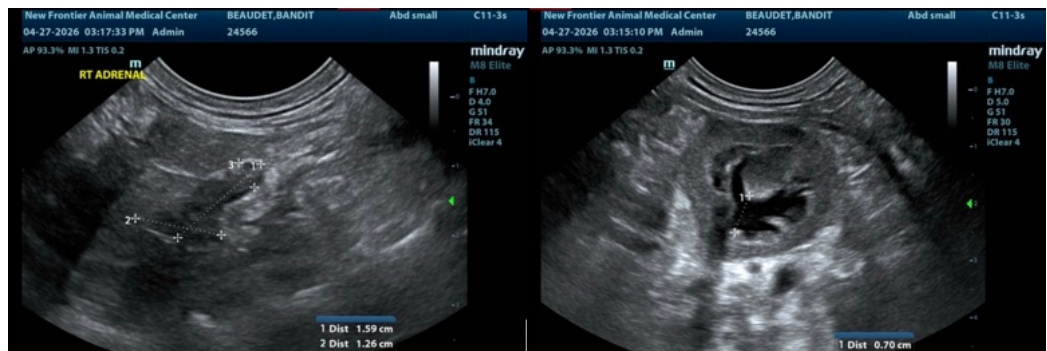
The base and limbs of the **pancreas** were observed to be largely isoechoic to surrounding omental fat. Pancreatic duct and capsular contour were acceptably normal and parenchyma respected normal curvilinear patterns. No overt evidence of active inflammatory or neoplastic disease was noted.

**ULTRASONOGRAPHIC FINDINGS**

Minor residual inflammatory pattern noted around the left kidney with pyelectasia, appears to be stable.

**INTERPRETATION OF THE FINDINGS & FURTHER RECOMMENDATIONS**

I recommend continuation of medical management and can be outpatient if the patient is stable and eating normally. Recheck sonogram is recommended in a week. Broad spectrum antibiotics should be maintained as well as any pain management that is necessary depending upon palpation of the left kidney.





**PATIENT**

Bandit Beaudet

**SPECIES**

Canine

**BREED**

Shih Tzu Cross

**SEX**

Neutered male

**AGE**

5 years

**WEIGHT**

6.8 lbs

**INTERPRETED BY**

Eric Lindquist, DMV  
DABVP, Cert. IVUSS

**IMAGING PERFORMED BY**

Gudrun Gunther

**HOSPITAL NAME**

New Frontier Animal  
Medical Center

**REFERRING VET**

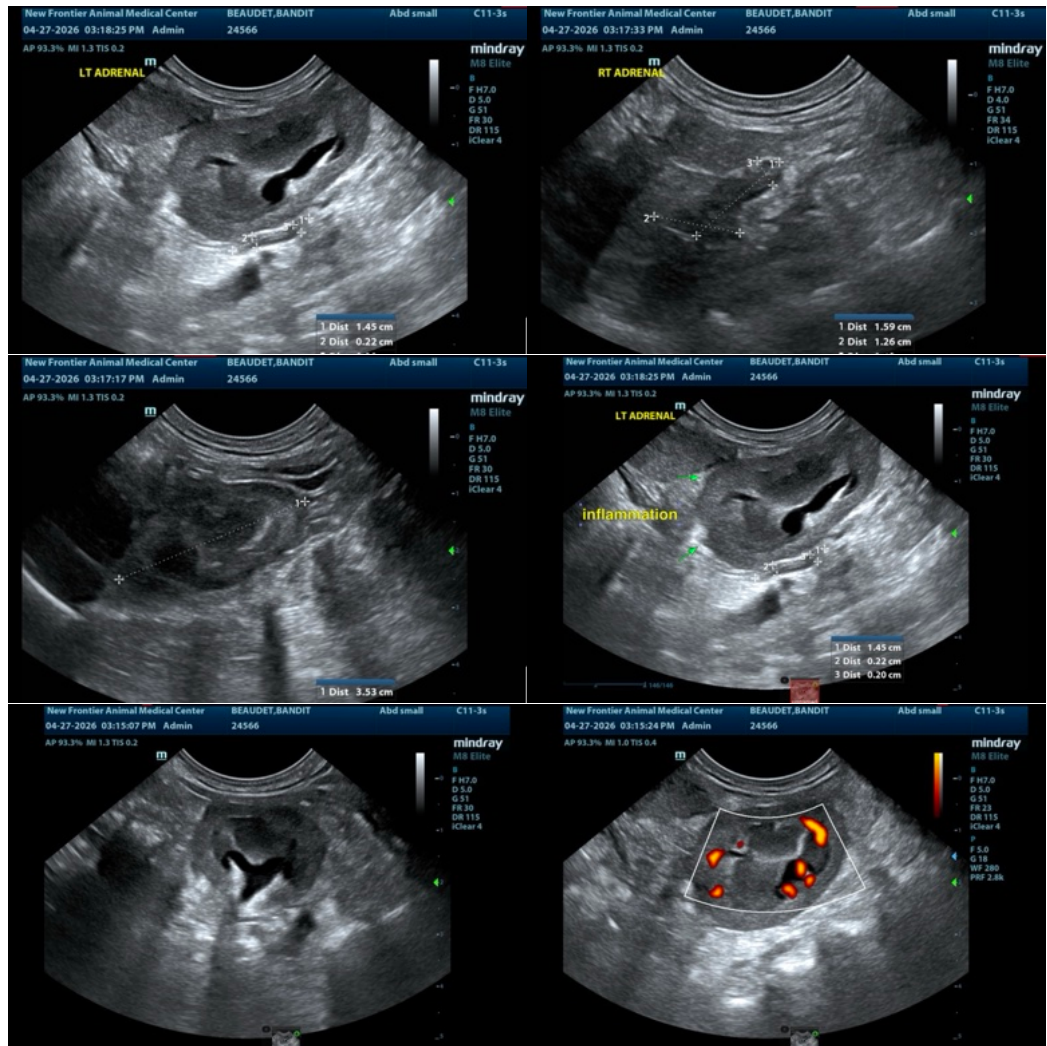
Dr. Gunther

**INVOICE**

74897

**DATE**

4/27/26



The information and recommendations provided are based on the images presented by the referring veterinarian/sonographer. No evaluation can be communicated regarding pathology that was not visible in the image/video clips provided.

Thank you for this referral. If the clinical or image interpretation does not parallel your findings or if I can be of any further assistance please contact me.

Eric Lindquist, DMV, DABVP (CFM), Cert. IVUSS, CEO of SonoPath.com

[info@SonoPath.com](mailto:info@SonoPath.com)