



**PATIENT**

Wonton Clark

**PRESENTING CLINICAL SIGNS**

History: recheck from yesterday showed delayed GI flow pattern Dog has been NPO

**SPECIES**

Canine

**ULTRASONOGRAPHIC EXAMINATION OF THE ABDOMEN**

**Gastrointestinal**

**BREED**

Mix

The stomach in this patient revealed a minor amount of fluid filled gastric lumen. Stasis in the upper small intestine was noted. Hyperperistalsis was present. The distal small intestine was empty.

**SEX**

Neutered male

**ULTRASONOGRAPHIC FINDINGS**

Delayed outflow pattern.

**AGE**

2 years

**INTERPRETATION OF THE FINDINGS & FURTHER RECOMMENDATIONS**

Appears to be an obstructive pattern. Some of the echogenic structures within the lumen appear linear and may represent worm burden. Assessment for worm burden is recommended. Anti-parasitic protocol is warranted. I cannot rule out an overt foreign body. If no evidence of intestinal parasites are present on fecal then exploratory surgery should be considered assuming the patient is completely n.p.o.

**WEIGHT**

44 lbs

**INTERPRETED BY**

Eric Lindquist, DMV  
DABVP, Cert. IVUSS

**IMAGING PERFORMED BY**

Jenn

**HOSPITAL NAME**

Rockaway AH

**REFERRING VET**

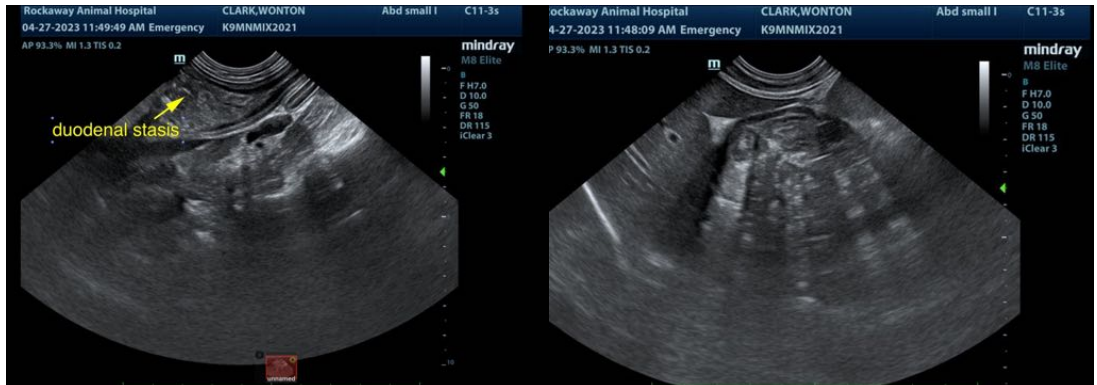
Dr. Maniar

**INVOICE**

44038

**DATE**

4/27/23



The information and recommendations provided are based on the images presented by the referring veterinarian/sonographer. No evaluation can be communicated regarding pathology that was not visible in the image/video clips provided.

Thank you for this referral. If the clinical or image interpretation does not parallel your findings or if I can be of any further assistance please contact me.

**Eric Lindquist, DMV, DABVP, Cert. IVUSS, CEO of SonoPath.com**  
info@SonoPath.com