



PATIENT PRESENTING CLINICAL SIGNS

Laney Johnson History: recheck from Monday showed luminal grass type density measuring approx 3.0cm in stomach

SPECIES

Canine

ULTRASONOGRAPHIC EXAMINATION OF THE ABDOMEN

Gastrointestinal

BREED

Collie Mix

The upper **gastrointestinal tract** was now empty. There was no evidence of residual luminal material noted. Transit of chyme appeared to be normal.

SEX

Spayed female

ULTRASONOGRAPHIC FINDINGS

Normal gastrointestinal tract.

AGE

9 years

INTERPRETATION OF THE FINDINGS & FURTHER RECOMMENDATIONS

There is no evidence of further pathology.

WEIGHT

72

INTERPRETED BY

Eric Lindquist, DMV
DABVP, Cert. IVUSS

IMAGING PERFORMED BY

Jenn

HOSPITAL NAME

Rockaway AH

REFERRING VET

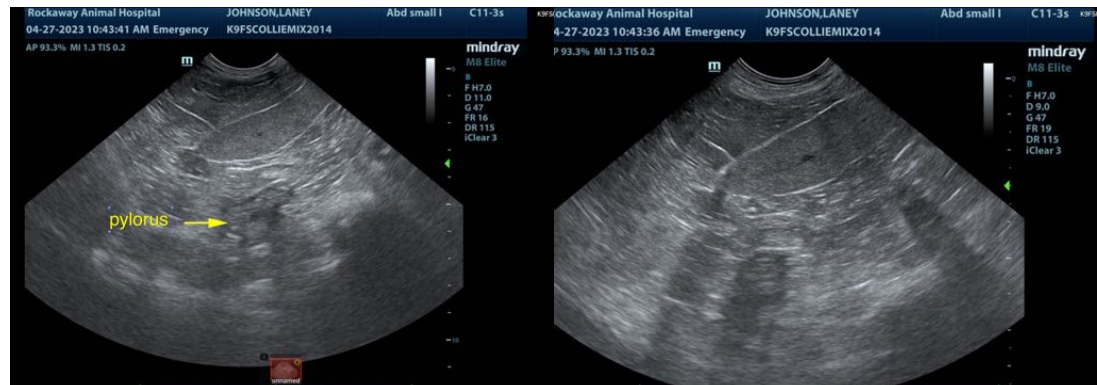
Dr. Maniar

INVOICE

44040

DATE

4/27/23



The information and recommendations provided are based on the images presented by the referring veterinarian/sonographer. No evaluation can be communicated regarding pathology that was not visible in the image/video clips provided.

Thank you for this referral. If the clinical or image interpretation does not parallel your findings or if I can be of any further assistance please contact me.

Eric Lindquist, DMV, DABVP, Cert. IVUSS, CEO of SonoPath.com
info@SonoPath.com