



PATIENT

Hunny Bunny
Gienieswki

SPECIES

Feline

BREED

Domestic Shorthair

SEX

Spayed female

AGE

6 years

WEIGHT

11.5 lbs

INTERPRETED BY

Eric Lindquist, DMV
DABVP, Cert. IVUSS

IMAGING PERFORMED BY

Dr. Grau

HOSPITAL NAME

Fredon AH

REFERRING VET

Dr. Grau

INVOICE

44058

DATE

4/27/23

PRESENTING CLINICAL SIGNS

History: owner lost another cat to lymphoma, looking for screening
Abnormal PE/Chem/CBC/UA Results: overweight, ventral abd over grooms, bloodwork NSF

ULTRASONOGRAPHIC EXAMINATION OF THE ABDOMEN

Urinary System

The **urinary bladder**, trigone, and pelvic urethra presented normal thicknesses and normal tone. The pelvic urethra was imaged 2.0 cm beyond the cystourethral junction and appeared normal. The ureters were not visible which is normal. No uroliths or sediment were visualized and anechoic urine was present. No evidence of inflammatory or neoplastic changes was noted. Ureteral papillae were normal.

The **kidneys** revealed normal size and structure, corticomedullary definition and ratio for this age. The cortices presented largely uniform texture with normal echogenic relationship to liver and spleen. Medullary structure differed distinctly from the cortex and no evidence of pelvic dilation was present. The capsules were acceptably uniform without significant irregularities. Slight, pinpoint mineralization was noted and non-obstructive at 0.2 cm. The left kidney measured 3.8 cm. The right kidney measured 4.1 cm.

Adrenal Glands

Both **adrenal glands** were visualized and recognized as having normal shape, size, position and echogenicity for this breed. The phrenic vasculature, glandular echogenicity and detail were unremarkable. Capsule, cortex, and medullary definition were normal for this age patient.

Spleen

The **spleen** presented a smooth homogeneous parenchyma hyperechoic to liver and renal cortical parenchyma. The capsule was smooth without noticeable expansion or deviation from within the spleen or adjacent pathology. The splenic vasculature demonstrated normal volume without signs of congestion or thrombosis. No sonographic evidence of acute or chronic inflammatory, neoplastic, or infarctual changes was noted.

Liver

The **liver** images submitted revealed subjectively normal liver size, contour, and structure. Parenchymal echogenicity was naturally coarse and hypoechoic to the spleen. Vascular and biliary tracts were of normal volume with no evidence of congestion. The gallbladder presented acceptably thin walls with primarily anechoic content. The cystic and common bile ducts were normal. No pathological hepatic lymphadenopathy was evident. No overt structural evidence of inflammatory, infiltrative or regenerative pathology was evident.



PATIENT

Gastrointestinal

Hunny Bunny
Gienieswki

The **gastrointestinal** presentation revealed mild uniform prominence of the gastric mucosa as well as areas of "ropy" small intestinal wall with slight disruption of the normal 1:3 muscularis/mucosal ratio. The intestinal submucosa was slightly irregular, thickened and hyperechoic suggestive of low grade, chronic disease. The mesenteric lymph nodes were prominent and measured 0.5 cm. The length to width ratio maintained.

SPECIES

Feline

BREED

Pancreas

Domestic Shorthair

The base and limbs of the **pancreas** were observed to be largely isoechoic to surrounding omental fat. Pancreatic duct and capsular contour were acceptably normal and parenchyma respected normal curvilinear patterns. No overt evidence of active inflammatory or neoplastic disease was noted.

SEX

Spayed female

ULTRASONOGRAPHIC FINDINGS

AGE

Minor intestinal thickening.

WEIGHT

INTERPRETATION OF THE FINDINGS & FURTHER RECOMMENDATIONS

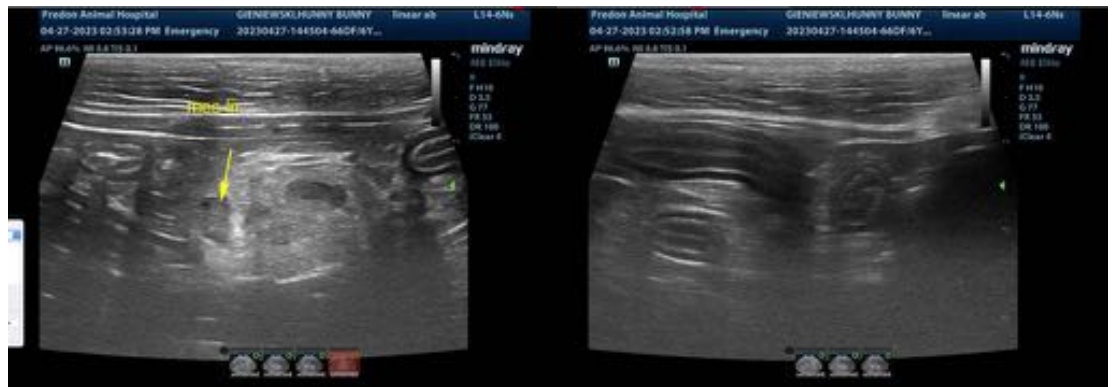
INTERPRETED BY

There was no evidence of neoplastic criteria in the GI tract or elsewhere.

11.5 lbs

IMAGING PERFORMED BY

Eric Lindquist, DMV
DABVP, Cert. IVUSS

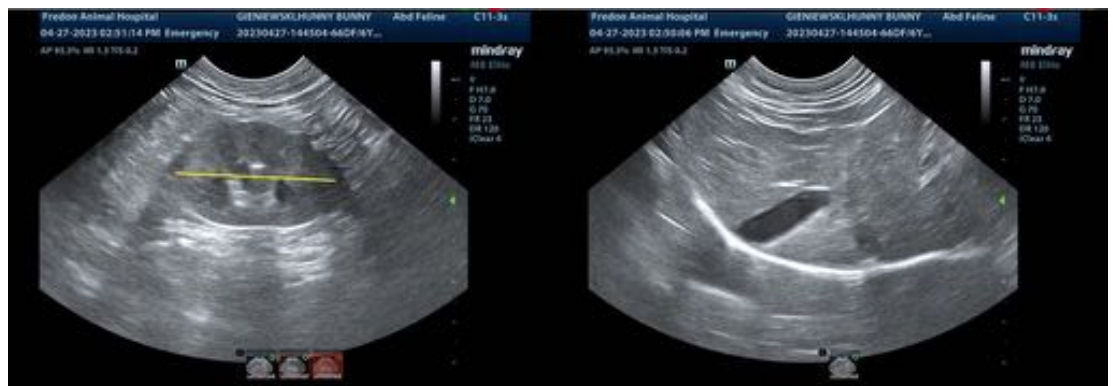


HOSPITAL NAME

Dr. Grau

REFERRING VET

Fredon AH



INVOICE

44058

DATE

4/27/23



PATIENT

Hunny Bunny
Gienieswki

SPECIES

Feline

BREED

Domestic Shorthair

SEX

Spayed female

AGE

6 years

WEIGHT

11.5 lbs

INTERPRETED BY

Eric Lindquist, DMV
DABVP, Cert. IVUSS

IMAGING PERFORMED BY

Dr. Grau

HOSPITAL NAME

Fredon AH

REFERRING VET

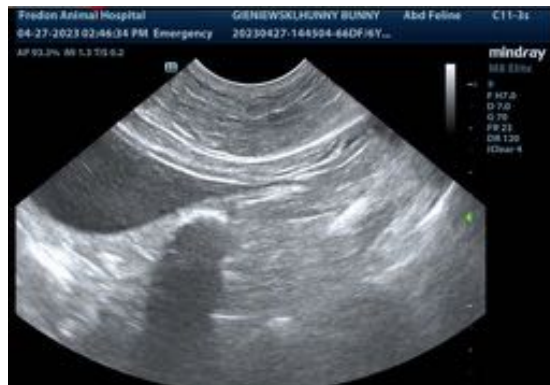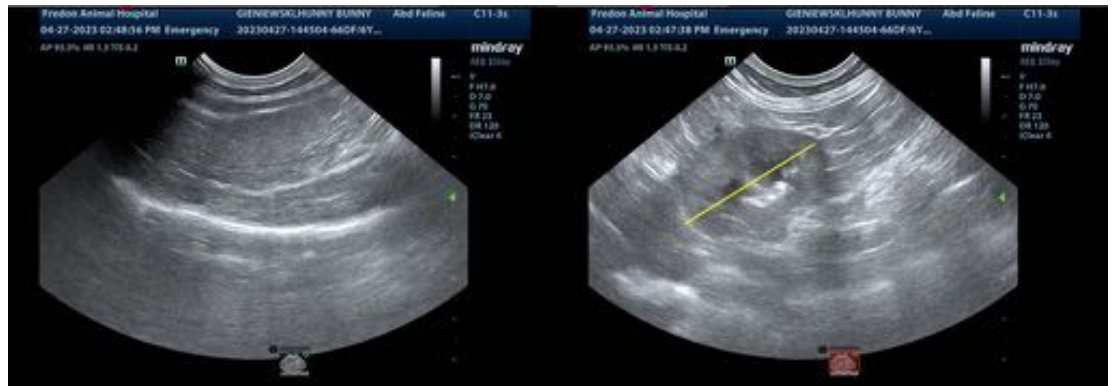
Dr. Grau

INVOICE

44058

DATE

4/27/23



The information and recommendations provided are based on the images presented by the referring veterinarian/sonographer. No evaluation can be communicated regarding pathology that was not visible in the image/video clips provided.

Thank you for this referral. If the clinical or image interpretation does not parallel your findings or if I can be of any further assistance please contact me.

Eric Lindquist, DMV, DABVP, Cert. IVUSS, CEO of SonoPath.com
info@SonoPath.com