

**DATE**

4/27/22

PRESENTING CLINICAL SIGNS

Presented for routine exam w/ vaccines on 4/23. Upon exam, firm mid abdominal mass was palpated. Vaccines were postponed. Radiographs performed. Pet acting normal at home.

PATIENT

Lexi Ellerbe

Current Medications: None.

SPECIES

Canine

Radiographs: Large, mid-abdominal mass effect partially mineralized, mineralized areas sporadic elsewhere in the abdomen - suspect possibly uterine, ovarian, or intestinal; Spoke to owner about breeding - Owner stated pet has never been bred before; Recommend abdominal ultrasound as next step.

Date of Previous IntraPet Ultrasound: No previous.

Sedation: Not required to complete full diagnostic ultrasound.

Stat Report: Not requested.

BREED

Rottweiler

ULTRASONOGRAPHIC EXAMINATION OF THE ABDOMEN**SEX**

Intact Female

Urinary System

The **urinary bladder**, trigone, and pelvic urethra presented normal thicknesses and normal tone. The ureters were not visible which is normal. No uroliths or sediment were visualized and anechoic urine was present. No evidence of inflammatory or neoplastic changes were noted. Ureteral papillae were normal. The pelvic urethra was imaged 3.0 cm beyond the cystourethral junction.

AGE

11/12/19

The **kidneys** revealed normal size and structure, corticomedullary definition and ratio for this age. The cortices presented largely uniform texture with normal echogenic relationship to liver and spleen. Medullary structure differed distinctly from the cortex and no evidence of pelvic dilation was present. The capsules were acceptably uniform without significant irregularities. The right kidney measured 7.0 cm. The left kidney measured 7.0 cm.

WEIGHT

87.5 Pounds

INTERPRETED BYEric Lindquist, DMV
DABVP, Cert. IVUSS**Adrenal Glands**

Both **adrenal glands** were visualized and recognized as having normal shape, size, position and echogenicity for this breed. The phrenic vasculature, glandular echogenicity and detail were unremarkable. Capsule, cortex, and medullary definition were normal for this age patient. The left adrenal gland measured 2.9 cm x 0.76 cm at the caudal pole and 0.60 cm at the cranial pole. The right adrenal gland measured 3.13 cm x 0.92 cm at the caudal pole and 0.94 cm at the cranial pole.

IMAGING PERFORMED BY

Rachel Brilhart RDMS

Spleen

The **spleen** was uniform, yet folded upon itself cranially, likely owing to space occupation.

HOSPITAL NAME

Parkville AH

Liver

The **liver** images submitted revealed subjectively normal liver size, contour, and structure. Parenchymal echogenicity was naturally coarse and hypoechoic to the spleen. Vascular and biliary tracts were of normal volume with no evidence of congestion. The gallbladder presented acceptably thin walls with primarily anechoic content. The cystic and common bile ducts were normal. No pathological hepatic lymphadenopathy was evident. No overt structural evidence of inflammatory, infiltrative or regenerative pathology was evident.

REFERRING VET

Dr. Mangini

INVOICE

37244

Gastrointestinal

Examination of the **gastrointestinal tract** revealed a stomach and intestine free of stasis, of normal wall thickness, acceptable curvilinear mural detail, and peristaltic activity. Small and large intestine demonstrated normal luminal chyme and stool consistency respectively. No obstructive or overt infiltrative disease was noted. No associated abnormal lymphatic activity was noted.

Pancreas

The base and limbs of the **pancreas** were observed to be largely isoechoic to surrounding omental fat. Pancreatic duct and capsular contour were acceptably normal and parenchyma respected normal curvilinear patterns. No overt evidence of active inflammatory or neoplastic disease was noted.

Other

A mineralized left cranial abdominal mass noted in this patient, measuring 13 cm x 10 cm. The mass was cystic and did not appear to be associated with any particular organ.

Slight amount of free fluid noted in the mid caudal abdomen.

The uterus was unremarkable, uniform, at 6.0 mm.

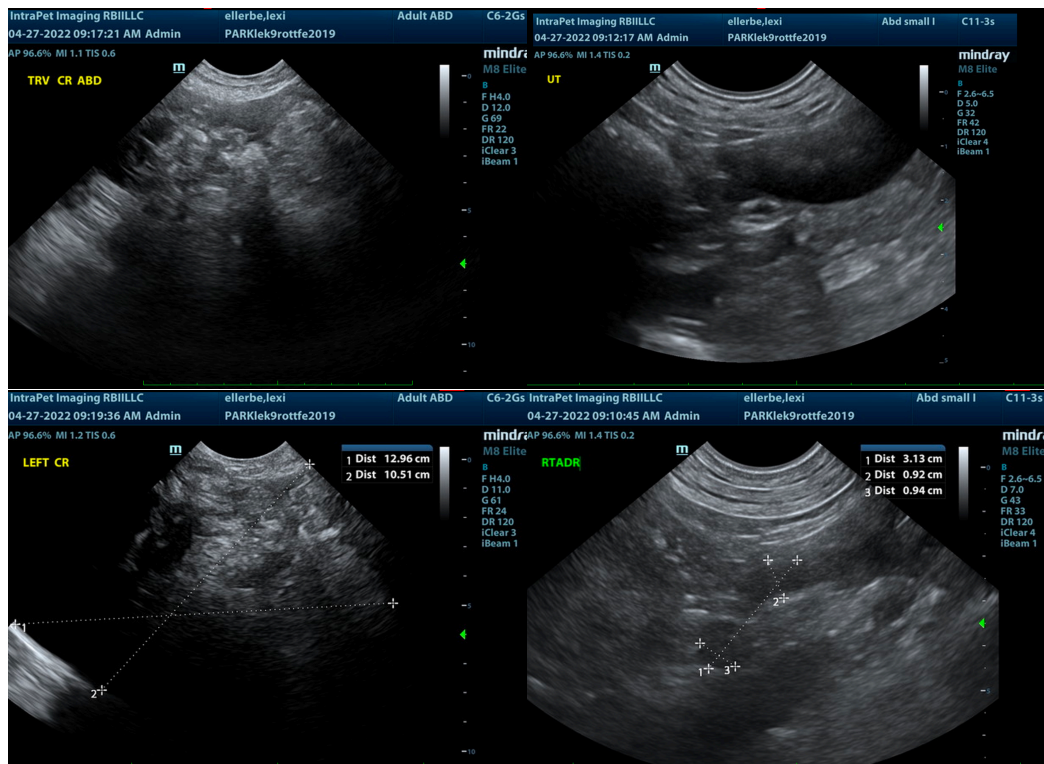
ULTRASONOGRAPHIC FINDINGS

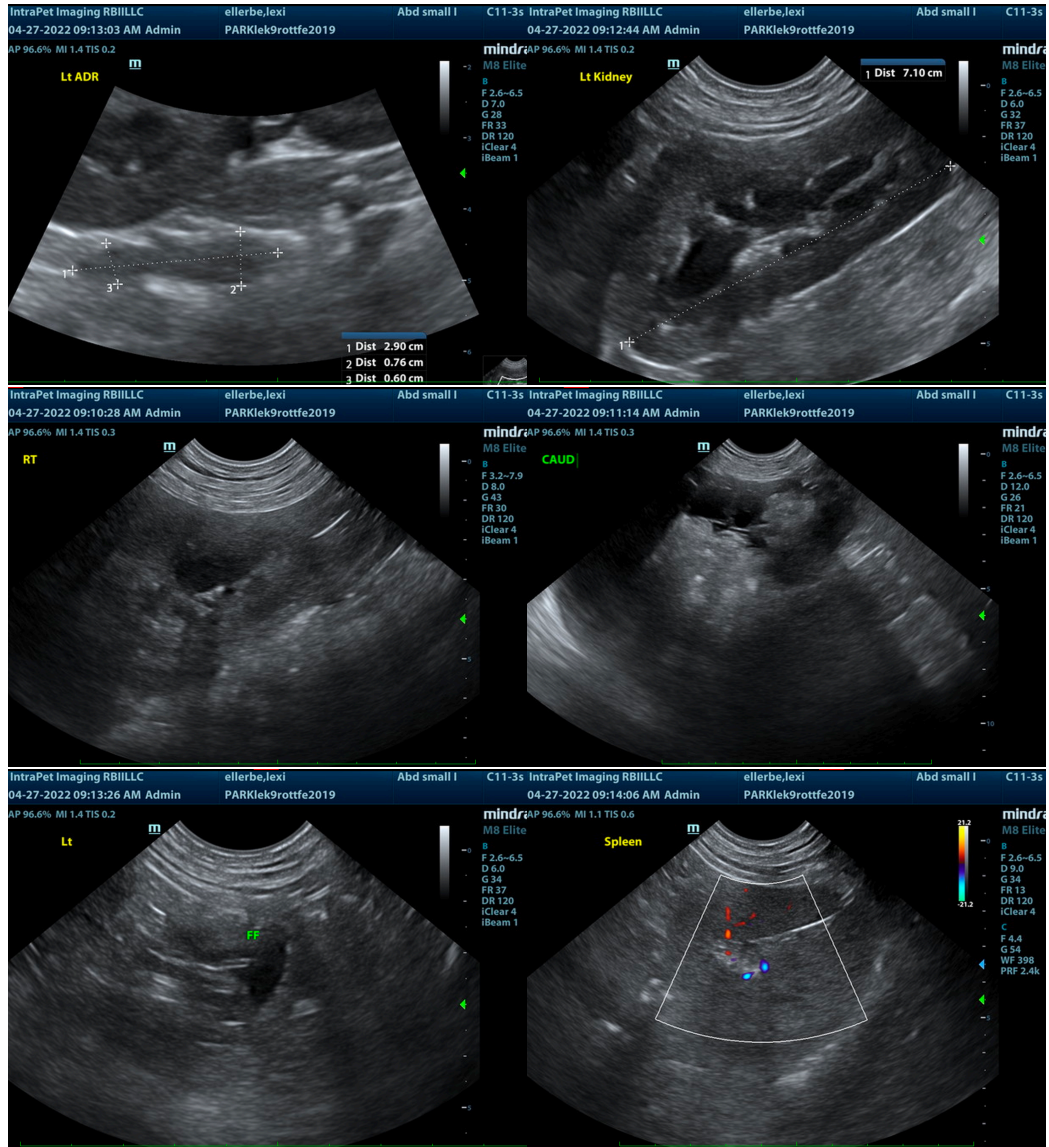
- Undifferentiated mineralized mass and free fluid in the left cranial abdomen, possibly related to the pancreas

INTERPRETATION OF THE FINDINGS & FURTHER RECOMMENDATIONS

Exploratory surgery indicated. No evidence of metastatic disease. Ovariohysterectomy should be considered at the time of surgery, given the convenience of the procedure and necessity for exploratory.

Radiographs: Mineralized mass in mid abdomen.





The information and recommendations provided are based on the images presented by the referring veterinarian/sonographer. No evaluation can be communicated regarding pathology that was not visible in the image/video clips provided.

Thank you for this referral. If the clinical or image interpretation does not parallel your findings or if I can be of any further assistance please contact me.

Eric Lindquist, DMV, DABVP, Cert. IVUSS, CEO of SonoPath.com
info@SonoPath.com