

**DATE**

4/27/22

**PRESENTING CLINICAL SIGNS**

Jazzy presented for a routine surgery on 1/11/22 and ALT was elevated.

**PATIENT**

Jazzy Campbell

Current Medications: None listed.

Lab Results: Consistently elevated ALT 673. AST 65.

Date of Previous IntraPet Ultrasound: No previous.

Sedation: Not required to complete full diagnostic ultrasound.

Stat Report: Not requested.

**SPECIES**

Canine

**ULTRASONOGRAPHIC EXAMINATION OF THE ABDOMEN****BREED**

Labrador X

**Urinary System**

The **urinary bladder**, trigone, and pelvic urethra presented normal thicknesses and normal tone. The ureters were not visible which is normal. No uroliths or sediment were visualized and anechoic urine was present. No evidence of inflammatory or neoplastic changes were noted. Ureteral papillae were normal.

**SEX**

Spayed Female

The **kidneys** revealed normal size and structure, corticomedullary definition and ratio for this age. The cortices presented largely uniform texture with normal echogenic relationship to liver and spleen. Medullary structure differed distinctly from the cortex and no evidence of pelvic dilation was present. The capsules were acceptably uniform without significant irregularities. The left kidney measured 6.36 cm. The right kidney measured 6.38 cm.

**AGE**

1/24/14

**WEIGHT**

68.7 Pounds

**Adrenal Glands**

Both **adrenal glands** were visualized and recognized as having normal shape, size, position and echogenicity for this breed. The phrenic vasculature, glandular echogenicity and detail were unremarkable. Capsule, cortex, and medullary definition were normal for this age patient. The left adrenal gland measured 3.0 cm x 0.82 cm at the caudal pole and 0.65 cm at the cranial pole. The right adrenal gland measured 3.07 cm x 0.87 cm at the caudal pole and 0.78 cm at the cranial pole.

**INTERPRETED BY**

Eric Lindquist, DMV  
DABVP, Cert. IVUSS

**Spleen**

The **spleen** revealed two separate hypoechoic (1.42 cm and 1.0 cm) nodules. Mild disruption of architecture. No evidence of capsular expansion.

**IMAGING PERFORMED BY**

Rachel Brilhart RDMS

**Liver**

The **liver** presented slight coarse architecture. Minor increased portal markings. The gallbladder and common bile duct were unremarkable.

**HOSPITAL NAME**

Northwind AH

**Gastrointestinal**

Examination of the **gastrointestinal tract** revealed a stomach and intestine free of stasis, of normal wall thickness, acceptable curvilinear mural detail, and peristaltic activity. Small and large intestine demonstrated normal luminal chyme and stool consistency respectively. No obstructive or overt infiltrative disease was noted. No associated abnormal lymphatic activity was noted.

**REFERRING VET**

Dr. Russ

**INVOICE**

37239

**Pancreas**

The base and limbs of the **pancreas** were observed to be largely isoechoic to surrounding omental fat. Pancreatic duct and capsular contour were acceptably normal and parenchyma respected normal curvilinear patterns. No overt evidence of active inflammatory or neoplastic disease was noted.

**Other**

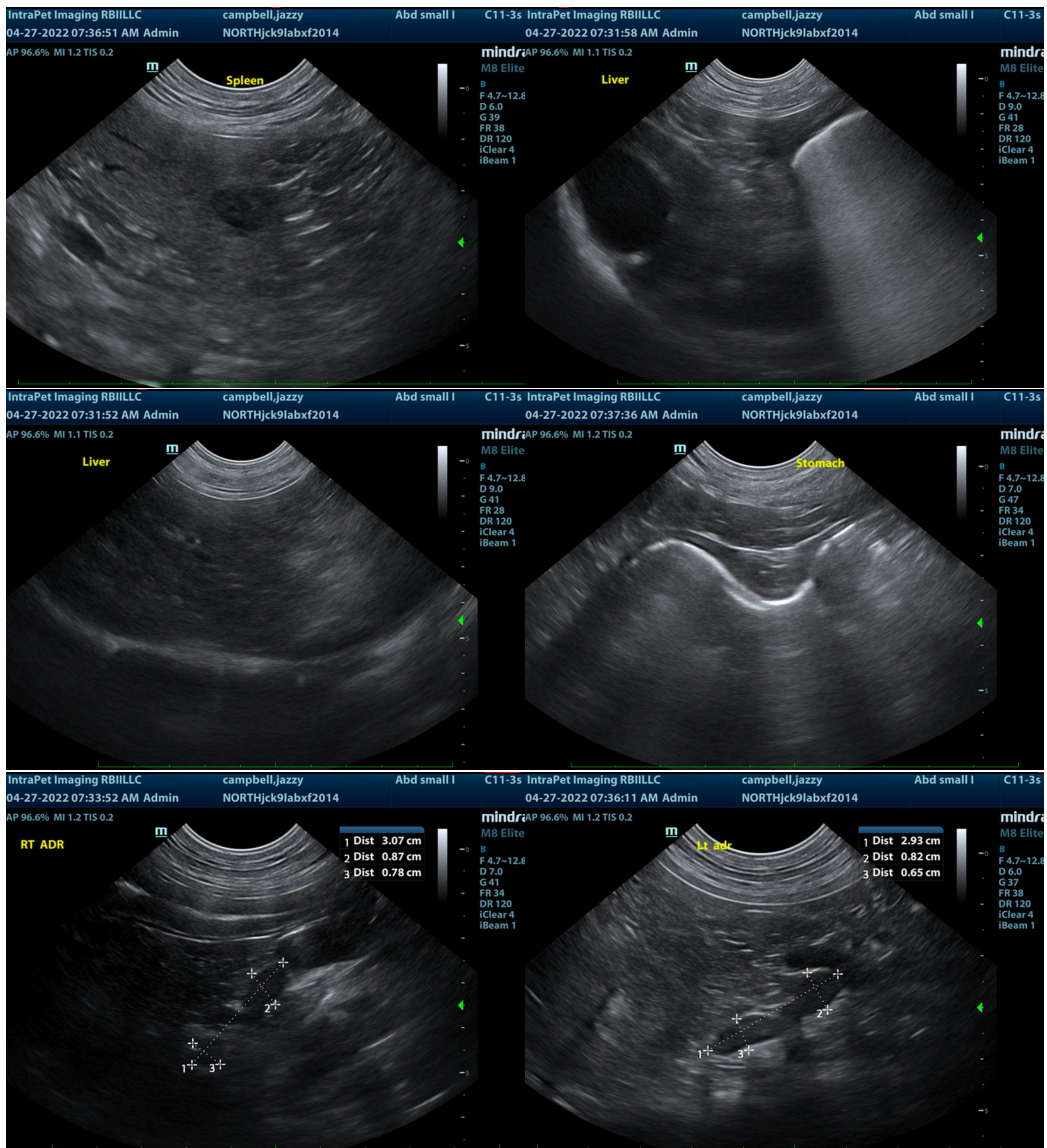
Rapid view of the heart revealed no evident pathology.

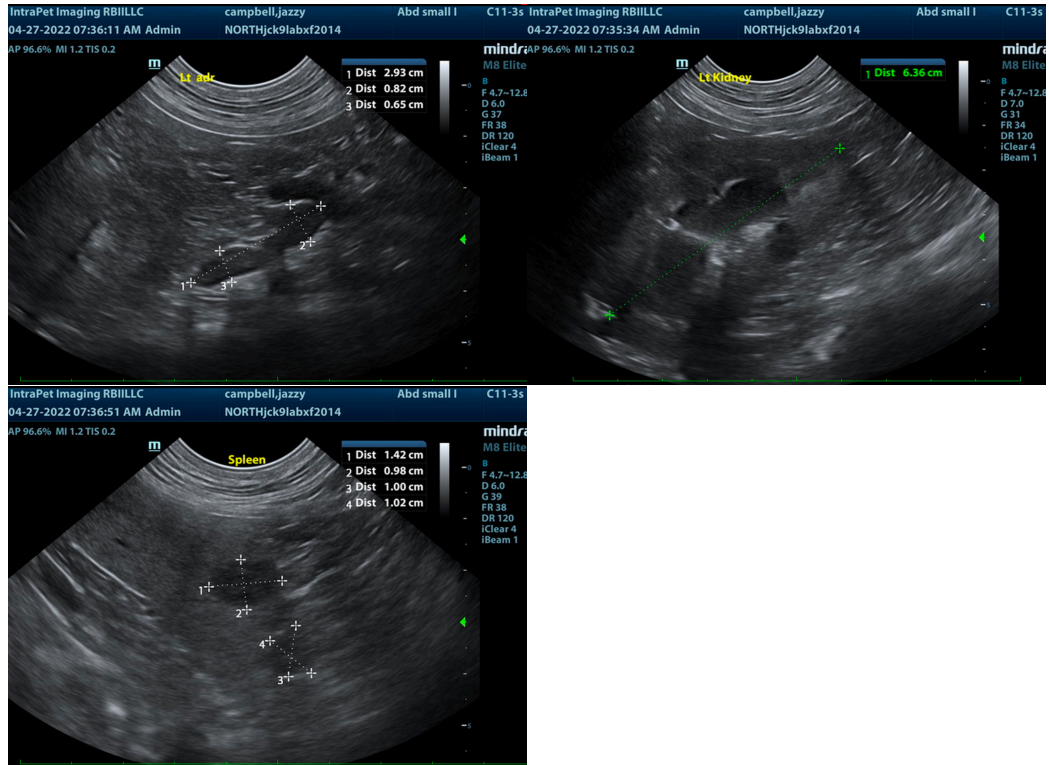
## ULTRASONOGRAPHIC FINDINGS

- Concerning splenic nodules - round cell neoplasia, emerging hemangiosarcoma, nodular hyperplasia all possible.

## INTERPRETATION OF THE FINDINGS & FURTHER RECOMMENDATIONS

FNA of the nodules or direct splenectomy indicated. Chest radiographs warranted to assess for metastatic disease. The nodules are not particularly large. However, my concern is for an emerging neoplastic event at a very early stage.





The information and recommendations provided are based on the images presented by the referring veterinarian/sonographer. No evaluation can be communicated regarding pathology that was not visible in the image/video clips provided.

Thank you for this referral. If the clinical or image interpretation does not parallel your findings or if I can be of any further assistance please contact me.

Eric Lindquist, DMV, DABVP, Cert. IVUSS, CEO of SonoPath.com  
[info@SonoPath.com](mailto:info@SonoPath.com)