

PATIENT

Jasmine Shook

SPECIES

Feline

BREED

Domestic Medium Hair

SEX

Spayed Female

AGE

10 years

WEIGHT

9 lbs

INTERPRETED BY

Eric Lindquist, DMV
DABVP, Cert. IVUSS

IMAGING PERFORMED BY

Dr. Mack

HOSPITAL NAME

Northside VC

REFERRING VET

Dr. Mack

INVOICE

99984

DATE

4/27/22

PRESENTING CLINICAL SIGNS

Patient has chronic urinary issues x 5 years. Patient has been treated with Clavamox, Convenia, Enrofloxacin and Cosequin, however symptoms always return. Patient has been on C/D diet since 2017. Abnormal PE/Chem/CBC/UA Results: CHEM 10 4/27/22: WNL U/A 4/27/22: SQ 1.034, pH 6.0, WBC and RBC <1/HPF, nsEPI <1/HPF, WNL otherwise.

ULTRASONOGRAPHIC EXAMINATION OF THE ABDOMEN

Urinary System

The **urinary bladder**, trigone, and pelvic urethra presented normal thicknesses and normal tone. The pelvic urethra was imaged 2.0 cm beyond the cystourethral junction. The ureters were not visible which is normal. No uroliths or sediment were visualized and anechoic urine was present. No evidence of inflammatory or neoplastic changes was noted. Ureteral papillae were normal.

The **kidneys** revealed largely normal size and structure, corticomedullary definition and ratio (cortex 1/3 of medulla) were essentially maintained with some age-related loss of curvilinear patterns regarding the capsule and C/M junction. The cortices presented largely uniform texture with some increased echogenicity expected for this age patient. Medullary structure differed distinctly from that of the cortex and no evidence of pelvic dilation was present. Cortical infarcts were noted at the cranial dorsal cortex of the left kidney. The left kidney measured 3.0 cm. Dorsal infarcts were noted at the right kidney. There was no evidence of active inflammation. The right kidney measured 3.0 cm.

Adrenal Glands

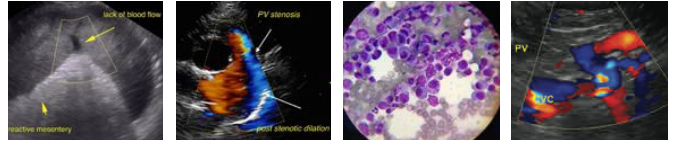
Both **adrenal glands** were visualized and recognized as having normal shape, size, position and echogenicity for this breed. The phrenic vasculature, glandular echogenicity and detail were unremarkable. Capsule, cortex, and medullary definition were normal for this age patient. The right adrenal gland measured 0.3 cm.

Spleen

The **spleen** presented a smooth homogeneous parenchyma hyperechoic to liver and renal cortical parenchyma. The capsule was smooth without noticeable expansion or deviation from within the spleen or adjacent pathology. The splenic vasculature demonstrated normal volume without signs of congestion or thrombosis. No sonographic evidence of acute or chronic inflammatory, neoplastic, or infarctual changes was noted.

Liver

The **liver** images from right and left intercostal as well as subcostal views revealed subjectively normal liver size, contour, and structure. Some age-related parenchymal remodeling was noted but likely not clinically significant at this time. Vascular and biliary tracts were of normal volume and no evidence of congestion was noted. The gallbladder wall was slightly echogenic.



PATIENT

Gastrointestinal

Jasmine Shook

Minor fluid filled **gastric** lumen was noted. Minor pyloric thickening was noted without loss of mural detail. The small intestine and colon were unremarkable.

SPECIES

Feline

Pancreas

The base and limbs of the **pancreas** were observed to be largely isoechoic to surrounding omental fat. Pancreatic duct and capsular contour were acceptably normal and parenchyma respected normal curvilinear patterns. No overt evidence of active inflammatory or neoplastic disease was noted.

BREED

Domestic Medium Hair

SEX

Spayed Female

ULTRASONOGRAPHIC FINDINGS

Minor, degenerative renal changes with cortical infarcts.

AGE

10 years

INTERPRETATION OF THE FINDINGS & FURTHER RECOMMENDATIONS

There is no evidence of lower urinary tract disease.

WEIGHT

9 lbs

INTERPRETED BY

Eric Lindquist, DMV
DABVP, Cert. IVUSS

IMAGING PERFORMED BY

Dr. Mack

HOSPITAL NAME

Northside VC

REFERRING VET

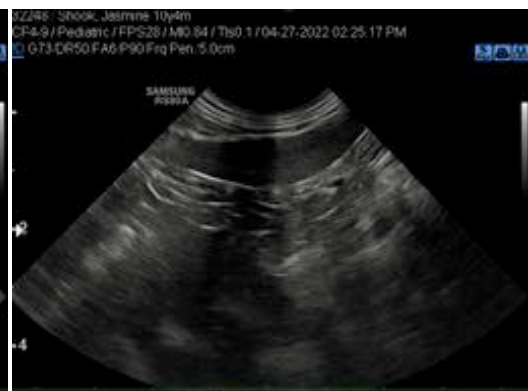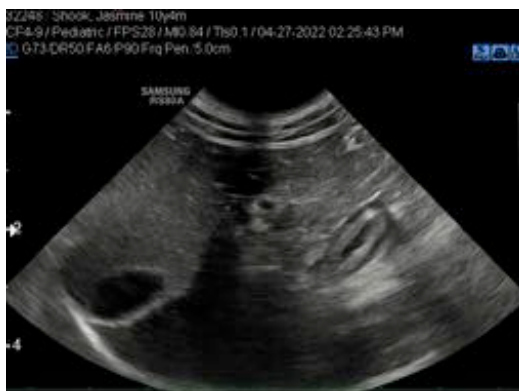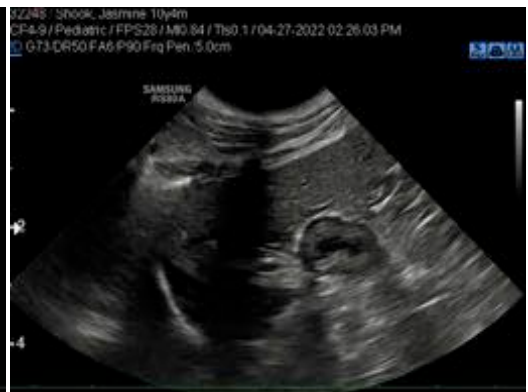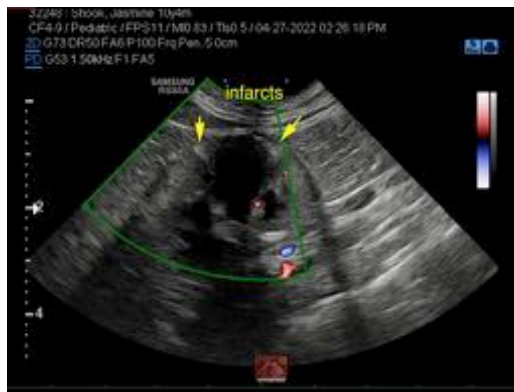Dr. Mack

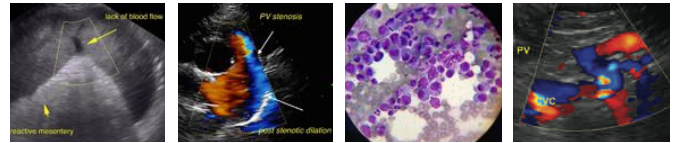
INVOICE

99984

DATE

4/27/22





PATIENT

Jasmine Shook

SPECIES

Feline

BREED

Domestic Medium Hair

SEX

Spayed Female

AGE

10 years

WEIGHT

9 lbs

INTERPRETED BY

Eric Lindquist, DMV
DABVP, Cert. IVUSS

IMAGING PERFORMED BY

Dr. Mack

HOSPITAL NAME

Northside VC

REFERRING VET

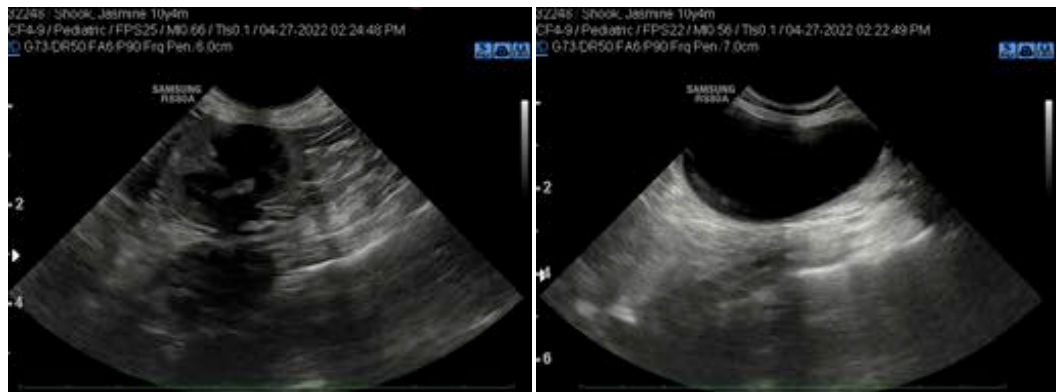
Dr. Mack

INVOICE

99984

DATE

4/27/22



The information and recommendations provided are based on the images presented by the referring veterinarian/sonographer. No evaluation can be communicated regarding pathology that was not visible in the image/video clips provided.

Thank you for this referral. If the clinical or image interpretation does not parallel your findings or if I can be of any further assistance please contact me.

Eric Lindquist, DMV, DABVP, Cert. IVUSS, CEO of SonoPath.com
info@SonoPath.com