



DATE PRESENTING CLINICAL SIGNS

4/26/26

Patient History: Ivory has had a decreased appetite for the last two weeks. She has lost about 2 pounds. She has been lethargic and not acting like herself. she has had blood work checked and an abdominal ultrasound. There has no been definitive diagnosis. The blood work from rDVM on April 24th has worsened. She now is severely azotemic, anemic, and icteric.

PATIENT

Ivory Layton

No vomiting, no diarrhea.

SPECIES

Feline

She was transferred to MDAEH for additional care and diagnostics.

Ivory was icteric on presentation. She was 8-10 % dehydrated and lethargic.

BREED

DSH

Current Medications: Continue iv fluids

Continue unasyn 25 mg/kg iv q 8 h Continue enrofloxacin 5 mg/kg iv 24 h Continue metronidazole 10

mg/kg iv q 12 h Continue ondansetron 0.5 mg/kg iv q 8 h Add vitamin K1 2.5 mg/kg sq q 24 h esophageal tube with feeding q 6 h

SEX

Spayed Female

Lab Results: attached.

Date of Previous IntraPet Ultrasound: No previous. Previous SonoPath ultrasound attached 4/15/26.

AGE

10/24/16

Sedation: Not required to complete full diagnostic ultrasound.

Stat Report: STAT requested.

Imaging Performed by: Rachel Brillhart, RDMS.

WEIGHT

4.7 kg

ULTRASONOGRAPHIC EXAMINATION OF THE ABDOMEN

INTERPRETED BY

Eric Lindquist, DMV,
DABVP (CFM), Cert.
IVUSS

Urinary System

The **urinary bladder**, trigone, and pelvic urethra presented normal thicknesses and normal tone. The ureters were not visible which is normal. No uroliths or sediment were visualized and anechoic urine was present. No evidence of inflammatory or neoplastic changes were noted. Ureteral papillae were normal.

The **right kidney** was significantly subnormal in size, measuring approximately 2.2 cm. Dystrophic changes, mineralization, and minor pelvic dilation were noted.

HOSPITAL NAME

Mason Dixon AEH

The **left kidney** was mildly enlarged (5.18 cm) with pericapsular swelling, slight pyelectasia, enhanced surrounding fat and slight free fluid.

Adrenal Glands

REFERRING VET

Dr. McCafferty

Both **adrenal glands** were visualized and recognized as having normal shape, size, position and echogenicity for this breed. The phrenic vasculature, glandular echogenicity and detail were unremarkable. Capsule, cortex, and medullary definition were normal for this age patient. The right adrenal gland measured 0.42 cm. The left adrenal gland measured 0.58 cm.

INVOICE

36810

Spleen

The **spleen** in this patient was uniform, yet volume contracted. Hydration status should be assessed.

Liver

The **liver** revealed hepatic lipidosis pattern. The gallbladder and common bile duct were unremarkable.

Gastrointestinal

Examination of the **gastrointestinal tract** revealed a stomach and intestine free of stasis, of normal wall thickness, acceptable curvilinear mural detail, and peristaltic activity. Small and large intestine demonstrated normal luminal chyme and stool consistency respectively. No obstructive or overt infiltrative disease was noted. No associated abnormal lymphatic activity was noted.

Pancreas

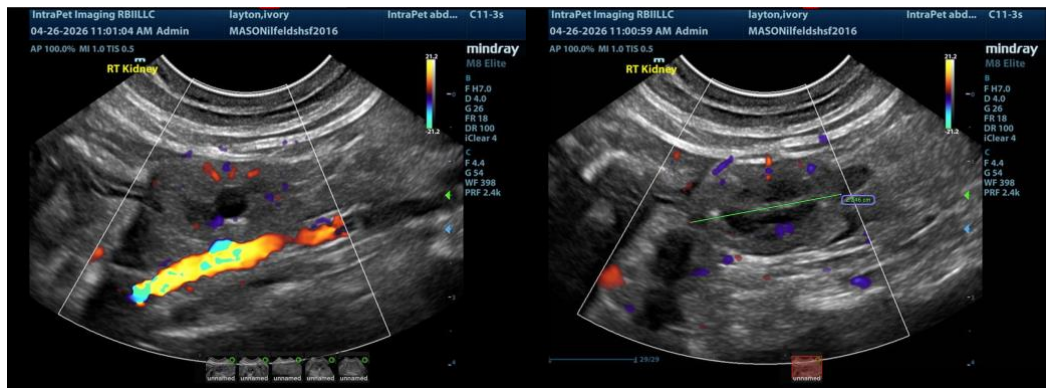
The base and limbs of the **pancreas** were observed to be largely isoechoic to surrounding omental fat. Pancreatic duct and capsular contour were acceptably normal and parenchyma respected normal curvilinear patterns. No overt evidence of active inflammatory or neoplastic disease was noted.

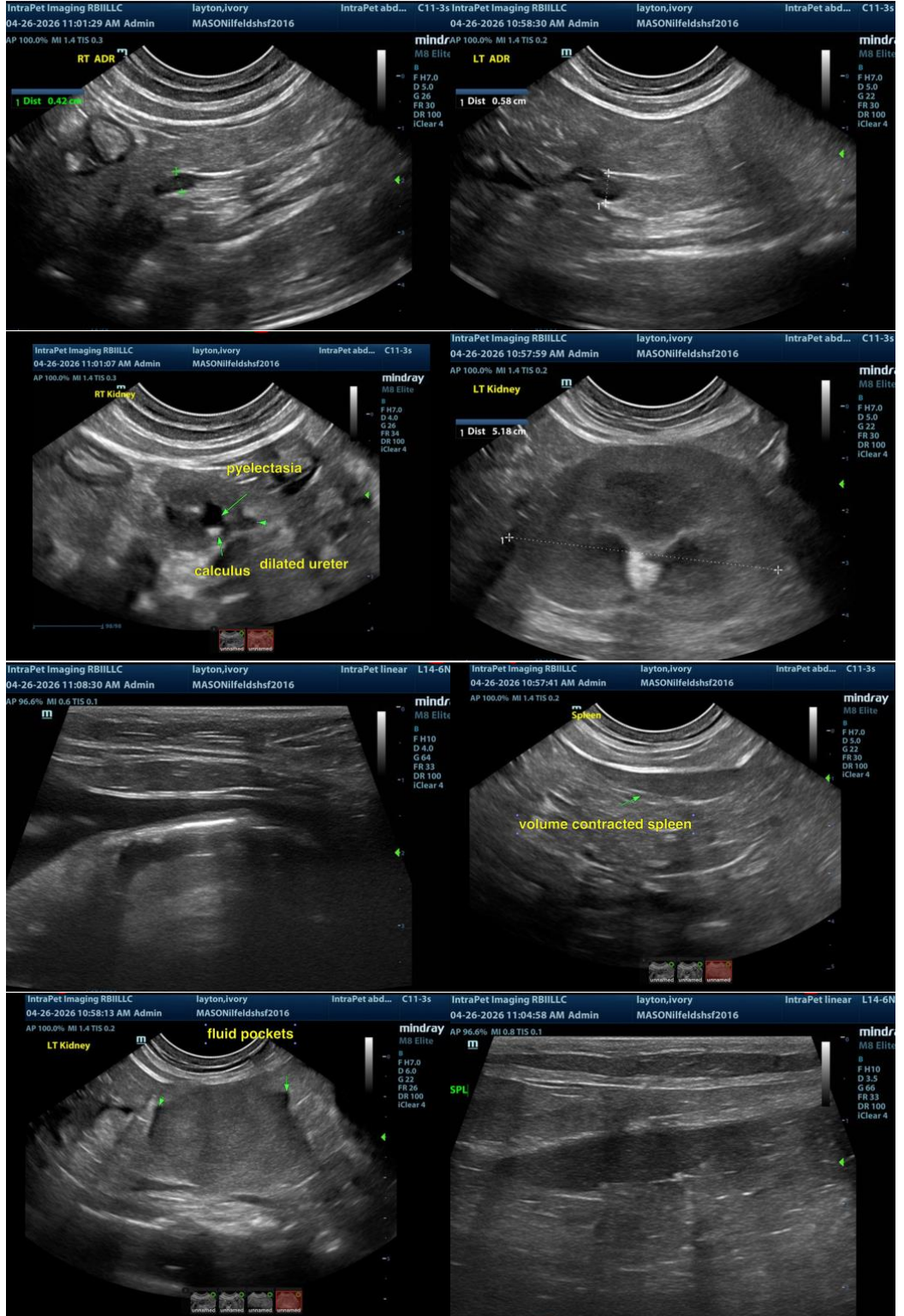
ULTRASONOGRAPHIC FINDINGS

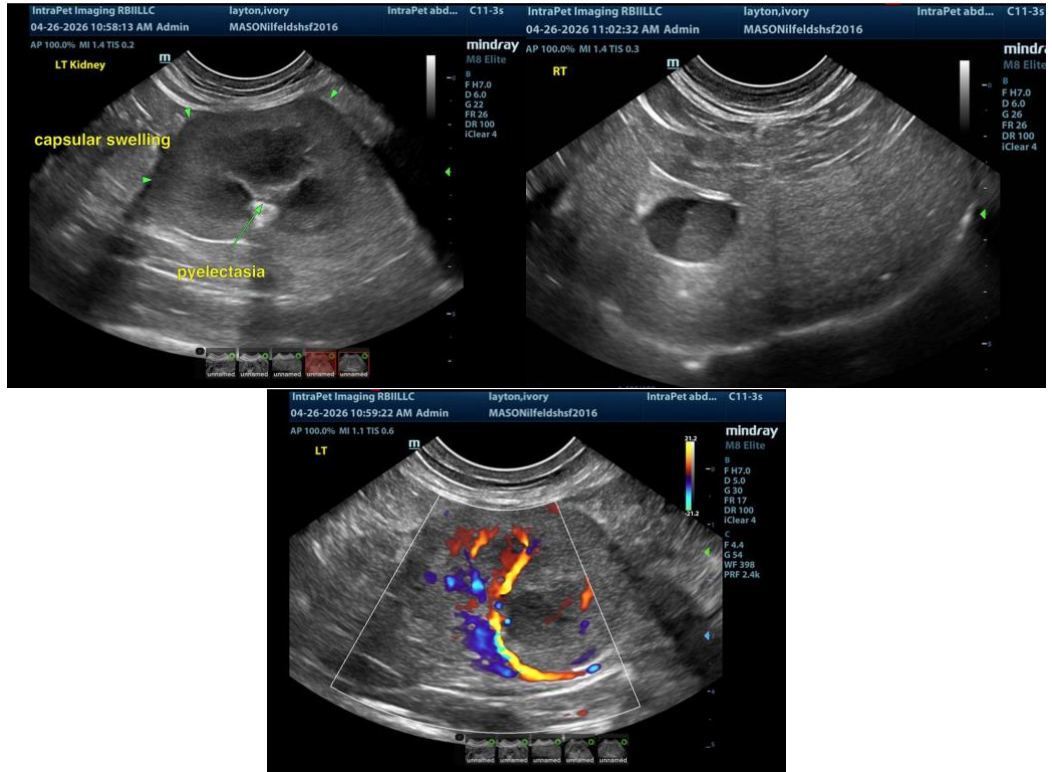
- Dystrophic right kidney with subnormal size,
- Compensatory hypertrophy and inactive nephritis of the left kidney
- Hepatic lipidosis pattern
- Volume contracted spleen

INTERPRETATION OF THE FINDINGS & FURTHER RECOMMENDATIONS

This is nonspecific presentation. The patient may be passing calculi periodically and this is a secondary result or undefined nephritis from infectious or toxic origin all possible. 72-hour IV fluid protocol and urine culture are indicated. Note: A prior report by a separate sonography service revealed both kidneys were normal size and an undefined structure was noted in the cranial abdomen, that undefined structure is actually dystrophic small right kidney. At times, in cats, excessive probe pressure can image the left kidney both from the right and left approaches, however, the left kidney is enlarged, and right kidney is subnormal and dystrophic in size, which is likely owing to chronic end-stage degenerative renal changes, owing to chronic obstruction by calculus and ureteral stricture.







The information and recommendations provided are based on the images presented by the referring veterinarian/sonographer. No evaluation can be communicated regarding pathology that was not visible in the image/video clips provided.

Thank you for this referral. If the clinical or image interpretation does not parallel your findings or if I can be of any further assistance please contact me.

Eric Lindquist, DMV, DABVP(CFM), Cert. IVUSS,
CEO, Owner, Founder -- SonoPath.com
info@SonoPath.com