

**PATIENT PRESENTING CLINICAL SIGNS**

Buzz Callahan

History: Murmur noted on initial exam. No clinical signs of heart disease. Markedly elevated proBNP  
 Abnormal PE/Chem/CBC/UA Results: grade iii/vi left parasternal systolic murmur

**SPECIES**

Feline

**ULTRASONOGRAPHIC EXAMINATION OF THE HEART**

The echocardiogram in this patient presented concentric, irregular, ventricular thickening with excessive left ventricular free wall papillary. Moderate mitral insufficiency was noted. The hepatic veins are not dilated.

**BREED**

Domestic Shorthair

**SEX**

Neutered male

**AGE**

1 year

**WEIGHT**

13 lbs

**INTERPRETED BY**

Eric Lindquist, DMV  
 DABVP, Cert. IVUSS

**IMAGING PERFORMED BY**

Dr. Green

**HOSPITAL NAME**

Healing Spirit

**REFERRING VET**

Dr. Green

**INVOICE**

422021

**DATE**

4/26/23

FELINE CARDIAC PARAMETERS	BODY WEIGHT (kg)	HR (BPM)	IVSd (cm)	LVIDd (cm)	LVWd (cm)	FS (%)	EF (%)
NORMAL PARAMETER	-----	150-240	0.3-0.6	1.0-2.1	0.25-0.6	35-67	80-100
PATIENT		NM	0.68	1.56	0.69	45	
FELINE CARDIAC PARAMETERS	LA/AO (Boon)	LA/AO HEART BASE (Sisson)	LA 2D 4-chamber long axis AS to FW (Sisson) (cm)	LVOT VEL. (m/s)	RVOT VEL. (m/s)	IVRT (m/)	
NORMAL PARAMETER	<1.5	0.88-1.79	0.7-1.7	<1.6	<1.3	40-60	
PATIENT	1.4	1.3	1.38		1.1	NM	

Adapted from June Boon, Veterinary Echocardiography, 1998  
 Sisson D et al. JVIM 1991; 5: 232, Jacobs et al. Am J Vet Res 1985; 46:1705

**ULTRASONOGRAPHIC FINDINGS**

Hypertrophied left ventricle with mitral insufficiency.

**INTERPRETATION OF THE FINDINGS & FURTHER RECOMMENDATIONS**

Hypertrophic cardiomyopathy; however a more complex congenital lesion cannot be completely ruled out. This is compensated at this time.



**PATIENT**

Buzz Callahan

**SPECIES**

Feline

**BREED**

Domestic Shorthair

**SEX**

Neutered male

**AGE**

1 year

**WEIGHT**

13 lbs

**INTERPRETED BY**

Eric Lindquist, DMV  
DABVP, Cert. IVUSS

**IMAGING PERFORMED BY**

Dr. Green

**HOSPITAL NAME**

Healing Spirit

**REFERRING VET**

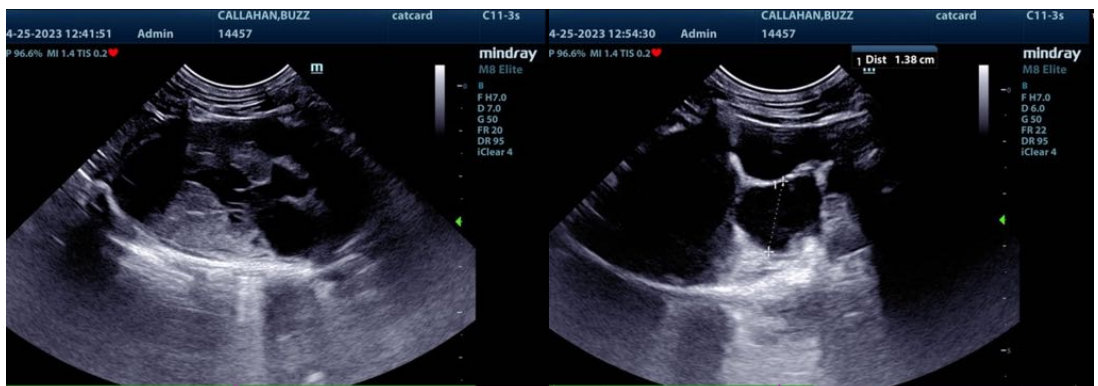
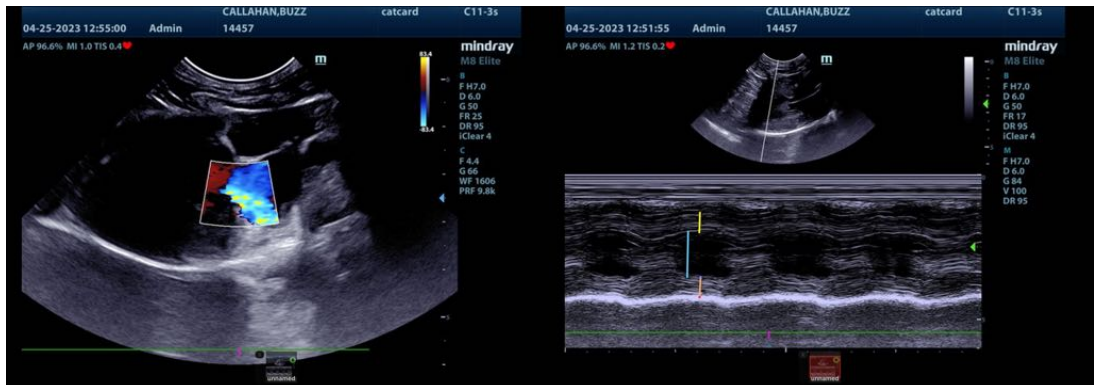
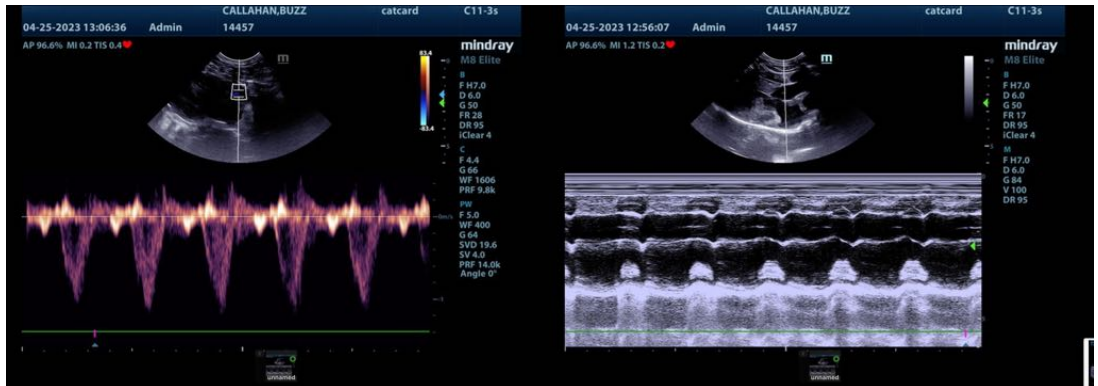
Dr. Green

**INVOICE**

422021

**DATE**

4/26/23



The information and recommendations provided are based on the images presented by the referring veterinarian/sonographer. No evaluation can be communicated regarding pathology that was not visible in the image/video clips provided.

Thank you for this referral. If the clinical or image interpretation does not parallel your findings or if I can be of any further assistance please contact me.

Eric Lindquist, DMV, DABVP, Cert. IVUSS, CEO of SonoPath.com  
info@SonoPath.com