

IMAGING PERFORMED BY

IntraPet.com



Clinical Sonography & Telectology

EDUCATIONAL TELECONSULTATION SERVICES™

1-800-838-4268 info@sonopath.com SonoPath.com

DATE

4/26/22

PATIENT

Shishka Bobbitt

SPECIES

Canine

BREED

German Shepherd

SEX

Intact Male

AGE

12/2/16

WEIGHT

73 Pounds

INTERPRETED BY

Eric Lindquist, DMV
DABVP, Cert. IVUSS

IMAGING PERFORMED BY

Andi Parkinson RDMS

HOSPITAL NAME

Greenbrier Vet Clinic

REFERRING VET

Dr. Boccanfuso

INVOICE

37176

PRESENTING CLINICAL SIGNS

DVM felt prostate was irregular/enlarged. Urinary recheck.

Current Medications: Baytril 136mg SID, Dasuquin Advanced.
Date of Previous IntraPet Ultrasound: 3/22/22. See attached.
Sedation: Not required to complete full diagnostic ultrasound.
Stat Report: Not requested.

LIMITED ULTRASONOGRAPHIC EXAMINATION

The urinary bladder, trigone, and pelvic urethra presented normal thicknesses and normal tone. The ureters were not visible which is normal. No uroliths or sediment were visualized and anechoic urine was present. No evidence of inflammatory or neoplastic changes were noted. Ureteral papillae were normal.

The prostate appeared reduced in size at 3.0 cm, uniform. No evidence of cysts, masses or inflammation. Mild BPH pattern.

The testicles were found to be uniform with no evident pathology.

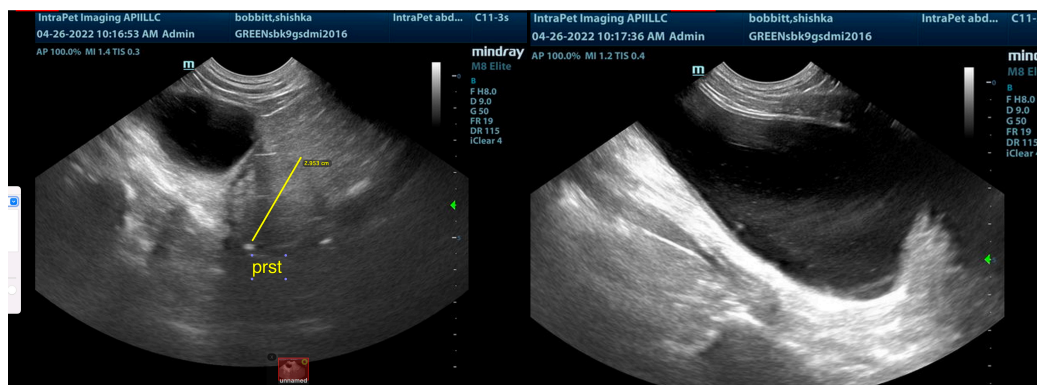
The kidneys revealed normal size and structure, corticomedullary definition and ratio for this age. The cortices presented largely uniform texture with normal echogenic relationship to liver and spleen. Medullary structure differed distinctly from the cortex and no evidence of pelvic dilation was present. The capsules were acceptably uniform without significant irregularities. The left kidney measured 8.4 cm. The right kidney measured 7.5 cm.

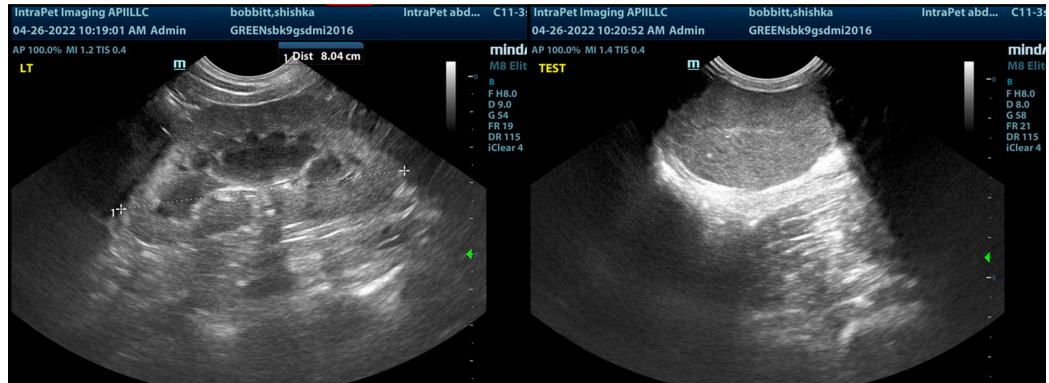
ULTRASONOGRAPHIC FINDINGS

- Reduced prostatic size with mild BPH pattern
- Stable urinary tract and reproductive organs

INTERPRETATION OF THE FINDINGS & FURTHER RECOMMENDATIONS

The prostate is uniform and roughly unchanged in size.





The information and recommendations provided are based on the images presented by the referring veterinarian/sonographer. No evaluation can be communicated regarding pathology that was not visible in the image/video clips provided.

Thank you for this referral. If the clinical or image interpretation does not parallel your findings or if I can be of any further assistance please contact me.

Eric Lindquist, DMV, DABVP, Cert. IVUSS, CEO of SonoPath.com
info@SonoPath.com