



**PATIENT**

Quincey Jacobus

**SPECIES**

Canine

**BREED**

Golden Retriever

**SEX**

Intact male

**AGE**

10 years

**WEIGHT**

81.5 lbs

**INTERPRETED BY**

Eric Lindquist, DMV  
DABVP, Cert. IVUSS

**IMAGING PERFORMED BY**

Shari Reffi, CVT

**HOSPITAL NAME**

American AH

**REFERRING VET**

Dr. Arculli

**INVOICE**

99958

**DATE**

4/25/22

**PRESENTING CLINICAL SIGNS**

Hyporexia, lethargic. Radiographs show hepatomegaly, possible splenomegaly and mid abdominal mass. Current meds: Galliprant, gabapentin  
Abnormal PE/Chem/CBC/UA Results: Chem/CBC=normal  
Radiographs reveal irregular spleen, hepatomegaly

**ULTRASONOGRAPHIC EXAMINATION OF THE ABDOMEN**

**Urinary System**

The **urinary bladder**, trigone, and pelvic urethra presented normal thicknesses and normal tone. The ureters were not visible which is normal. No uroliths or sediment were visualized and anechoic urine was present. No evidence of inflammatory or neoplastic changes was noted. Ureteral papillae were normal.

The right testicle revealed a 1.34 cm isoechoic nodule. A separate similar nodule was noted in the left testicle and measured 1.14 cm.

The **prostate** was uniformly enlarged with lobar swelling appeared to impinge upon the urethra and mildly deviate the descending colon. The prostatic tissue was hyperechoic containing focal areas of decreased echogenicity. These changes are suggestive of either chronic inflammatory episodes, benign cystic pathology or both. Underlying neoplasia cannot be completely ruled-out but is lower on the differential list. This presentation is most consistent with benign prostatic hyperplasia with possible active prostatitis. Neutering or off-label Finasteride (Propecia) (0.1-0.5 mg/kg Sid) treatment is indicated +/- FNA or prostatic wash cytology and culture. An anechoic cyst in the prostate was noted and measured 0.5 cm. The prostate measures 3.5 cm.

Both **kidneys** were enlarged. The left kidney measured 8.43 cm with a hypoechoic expansive mass that measured 3.24 cm at the dorsal cortex. The right kidney measured 8.03 cm. Pericapsular inflammatory pattern was noted around both kidneys owing to capsular expansion and infiltrative pattern.

**Adrenal Glands**

Both **adrenal glands** were visualized and recognized as having largely normal shape, size, position and acceptable echogenicity for this age group and breed. Some heterogeneity was noted within the adrenal parenchyma without concerning capsular distortion. These changes are likely age related but should be monitored by sonogram should the patient be suspected of having adrenal disease. The left adrenal gland measured 2.61 x 0.71 cm at the cranial pole and 0.68 cm at the caudal pole. The right adrenal gland measured 2.84 x 1.14 cm at the cranial pole and 0.73 cm at the caudal pole.

**Spleen**

The **spleen** was enlarged with scalloping contour and heterogenous parenchymal changes.

**Liver**

The **liver** revealed coarse architecture with increased portal markings. The gallbladder revealed slight, irregular contour. The cystic and common bile ducts were normal. The hepatic lymph nodes were enlarged and rounded measuring up to 2.0 cm.



**PATIENT**

**Gastrointestinal**

Quincey Jacobus

Examination of the **gastrointestinal tract** revealed a stomach and intestine free of stasis, of normal wall thickness, acceptable curvilinear mural detail, and peristaltic activity. Small and large intestine demonstrated normal luminal chyme and stool consistency respectively. No obstructive or overt infiltrative disease was noted.

**SPECIES**

Canine

**BREED**

Golden Retriever

**Pancreas**

The base and limbs of the **pancreas** were observed to be largely isoechoic to surrounding omental fat. Pancreatic duct and capsular contour were acceptably normal and parenchyma respected normal curvilinear patterns. No overt evidence of active inflammatory or neoplastic disease was noted.

**SEX**

Intact male

**Free Abdomen**

A cranial abdominal lymph node mass was noted and measured 3.5 cm.

**AGE**

10 years

**ULTRASONOGRAPHIC FINDINGS**

**WEIGHT**

81.5 lbs

Infiltrative pattern. Round cell neoplasia is suspected in the spleen, kidneys, likely liver and hepatic lymph nodes.

Concurrent testicular nodules, likely unrelated.

Cranial abdominal lymph node mass was noted.

**INTERPRETED BY**

Eric Lindquist, DMV  
DABVP, Cert. IVUSS

BPH Prostate.

**IMAGING PERFORMED BY**

Shari Reffi, CVT

**INTERPRETATION OF THE FINDINGS & FURTHER RECOMMENDATIONS**

FNA of the spleen, kidneys and liver would be ideal for staging purposes. The prognosis is poor. However, this may be responsive to chemotherapy. Round cell neoplasia is likely.

**HOSPITAL NAME**

American AH

**REFERRING VET**

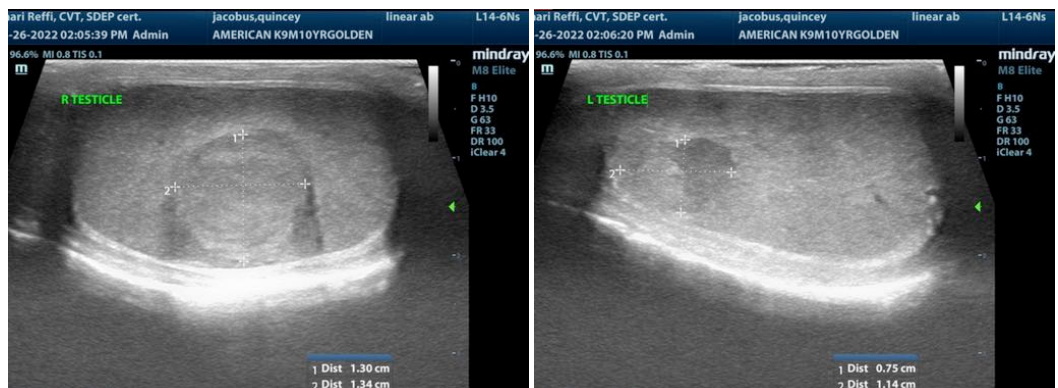
Dr. Arculli

**INVOICE**

99958

**DATE**

4/25/22





**PATIENT**

Quincey Jacobus

**SPECIES**

Canine

**BREED**

Golden Retriever

**SEX**

Intact male

**AGE**

10 years

**WEIGHT**

81.5 lbs

**INTERPRETED BY**

Eric Lindquist, DMV  
DABVP, Cert. IVUSS

**IMAGING PERFORMED BY**

Shari Reffi, CVT

**HOSPITAL NAME**

American AH

**REFERRING VET**

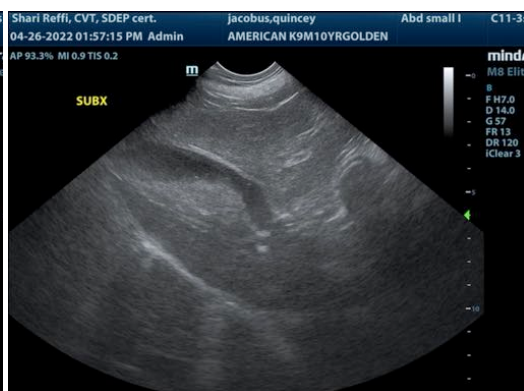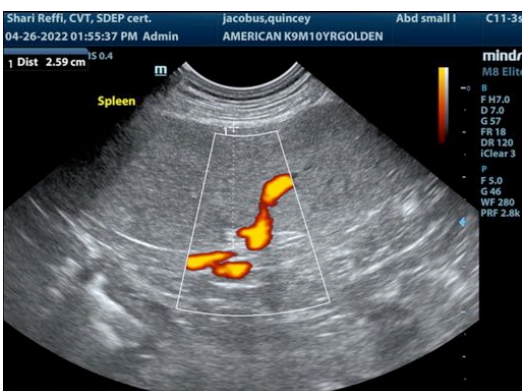
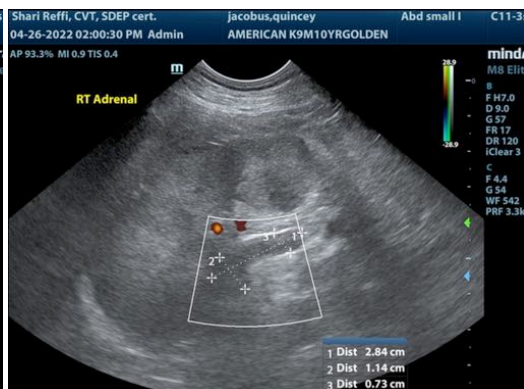
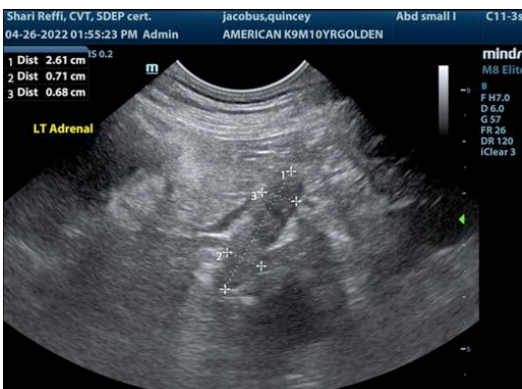
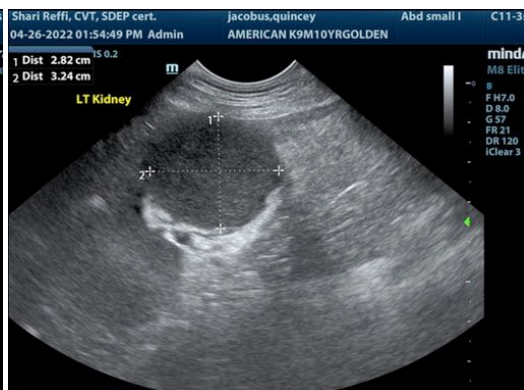
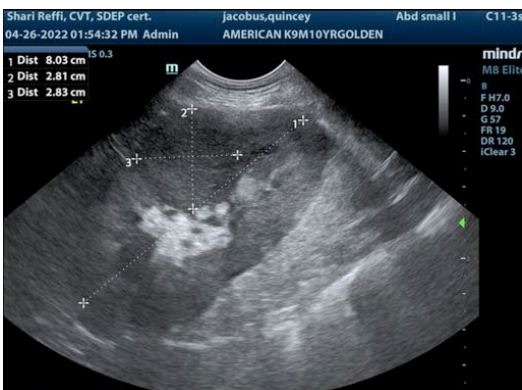
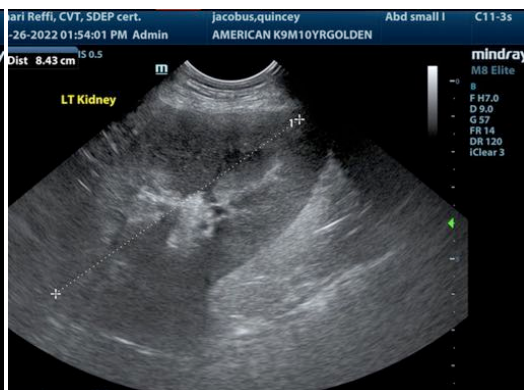
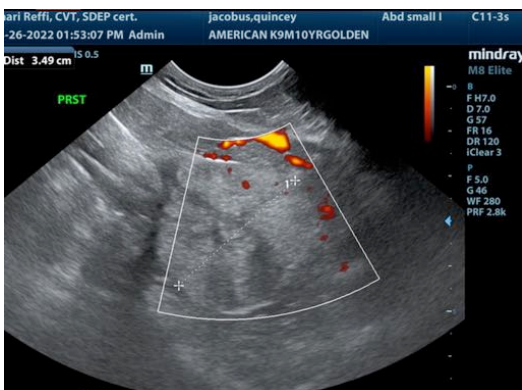
Dr. Arculli

**INVOICE**

99958

**DATE**

4/25/22





**PATIENT**

Quincey Jacobus

**SPECIES**

Canine

**BREED**

Golden Retriever

**SEX**

Intact male

**AGE**

10 years

**WEIGHT**

81.5 lbs

**INTERPRETED BY**

Eric Lindquist, DMV  
DABVP, Cert. IVUSS

**IMAGING PERFORMED BY**

Shari Reffi, CVT

**HOSPITAL NAME**

American AH

**REFERRING VET**

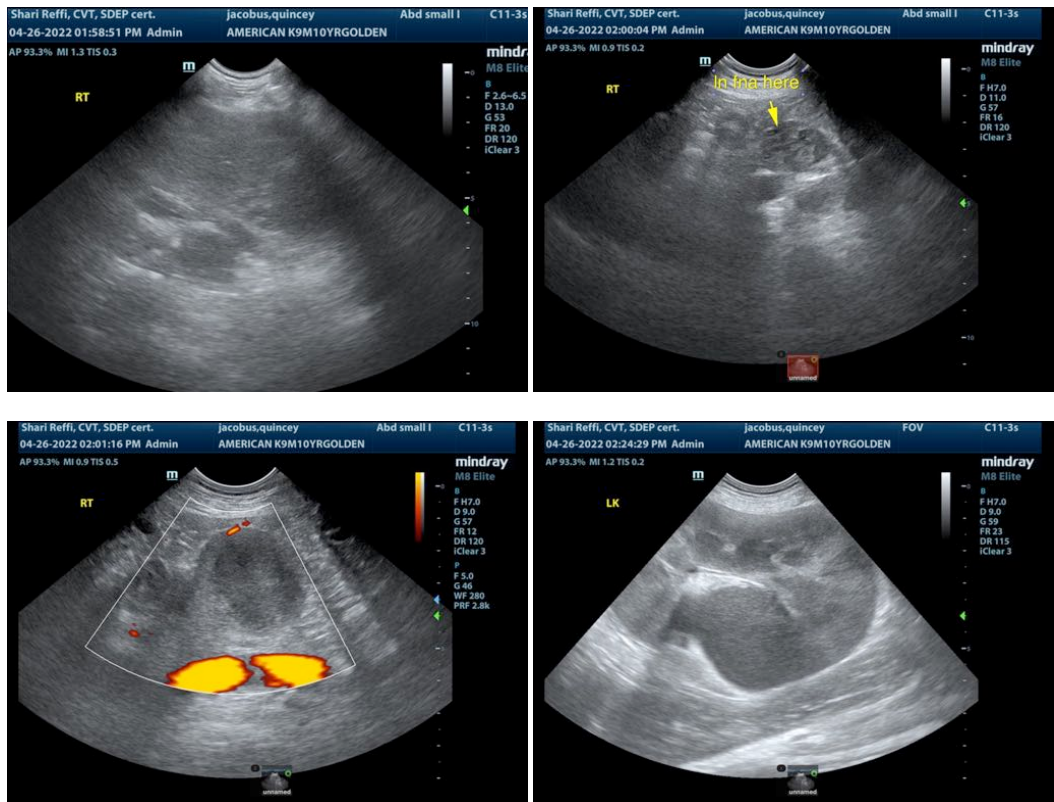
Dr. Arculli

**INVOICE**

99958

**DATE**

4/25/22



The information and recommendations provided are based on the images presented by the referring veterinarian/sonographer. No evaluation can be communicated regarding pathology that was not visible in the image/video clips provided.

Thank you for this referral. If the clinical or image interpretation does not parallel your findings or if I can be of any further assistance please contact me.

**Eric Lindquist, DMV, DABVP, Cert. IVUSS, CEO of SonoPath.com**  
Info@SonoPath.com