



PATIENT

Jack Fredericksen

SPECIES

Canine

BREED

Airedale Terrier

SEX

Neutered Male

AGE

1.5

WEIGHT

36.8

INTERPRETED BY

Eric Lindquist, DMV,
DABVP(CFM), Cert.
IVUSS

IMAGING PERFORMED BY

Dr. Stephanie
Permenter

HOSPITAL NAME

Viking Veterinary
Hospital- Moscow

REFERRING VET

Dr. Stephanie
Permenter

INVOICE

15478

DATE

04/25/26

PRESENTING CLINICAL SIGNS

History of eating less or not interested in food in the morning and seems lethargic to owner. Bloodwork and barium study unremarkable according to rDVM. No improvement on metoclopramide, some improvement on Cerenia. Intermittent vomiting. May have eaten some paper towels in December prior to onset of signs.

Abnormal PE/Chem/CBC/UA Results: P BAR and very energetic, good body condition.

ULTRASONOGRAPHIC EXAMINATION OF THE ABDOMEN

Urinary System

The **urinary bladder**, trigone, and pelvic urethra presented normal thicknesses and normal tone. The ureters were not visible which is normal. No uroliths or sediment were visualized, and anechoic urine was present. No evidence of inflammatory or neoplastic changes were noted. Ureteral papillae were normal.

The **kidneys** revealed normal size and structure, corticomedullary definition and ratio for this age. The cortices presented largely uniform texture with normal echogenic relationship to liver and spleen. Medullary structure differed distinctly from the cortex and no evidence of pelvic dilation was present. The capsules were acceptably uniform without significant irregularities. The left kidney measured 6.1 cm in length. The right kidney measured 7.5 cm in length.

Adrenal Glands

Both **adrenal glands** were visualized and recognized as having normal shape, size, position and echogenicity for this breed. The phrenic vasculature, glandular echogenicity and detail were unremarkable. Capsule, cortex, and medullary definition were normal for this age patient. The left adrenal gland measured 2.86 cm x 0.74 cm width. The right adrenal gland measured 1.5 cm width at the cranial pole and 0.76 cm width at the caudal pole.

Spleen

The **spleen** presented a smooth homogeneous parenchyma hyperechoic to liver and renal cortical parenchyma. The capsule was smooth without noticeable expansion or deviation from within the spleen or adjacent pathology. The splenic vasculature demonstrated normal volume without signs of congestion or thrombosis. No sonographic evidence of acute or chronic inflammatory, neoplastic, or infarctual changes were noted. The spleen was folded upon itself caudally.

Liver

The **liver** images submitted revealed subjectively normal liver size, contour, and structure. Parenchymal echogenicity was naturally coarse and hypoechoic to the spleen. Vascular and biliary tracts were of normal volume with no evidence of congestion. The gallbladder presented acceptably thin walls with primarily anechoic content. The cystic and common bile ducts were normal. No pathological hepatic lymphadenopathy was evident. No overt structural evidence of inflammatory, infiltrative or regenerative pathology was evident.

Gastrointestinal

Examination of the **gastrointestinal tract** revealed a stomach and intestine free of stasis, of normal wall thickness, acceptable curvilinear mural detail, and peristaltic activity. Small and large intestine



PATIENT

Jack Fredericksen

SPECIES

Canine

BREED

Airedale Terrier

SEX

Neutered Male

AGE

1.5

WEIGHT

36.8

INTERPRETED BY

Eric Lindquist, DMV,
DABVP(CFM), Cert.
IVUSS

IMAGING PERFORMED BY

Dr. Stephanie
Permenter

HOSPITAL NAME

Viking Veterinary
Hospital- Moscow

REFERRING VET

Dr. Stephanie
Permenter

INVOICE

15478

DATE

04/25/26

demonstrated normal luminal chyme and stool consistency respectively. No obstructive or overt infiltrative disease was noted. No associated abnormal lymphatic activity was noted.

Pancreas

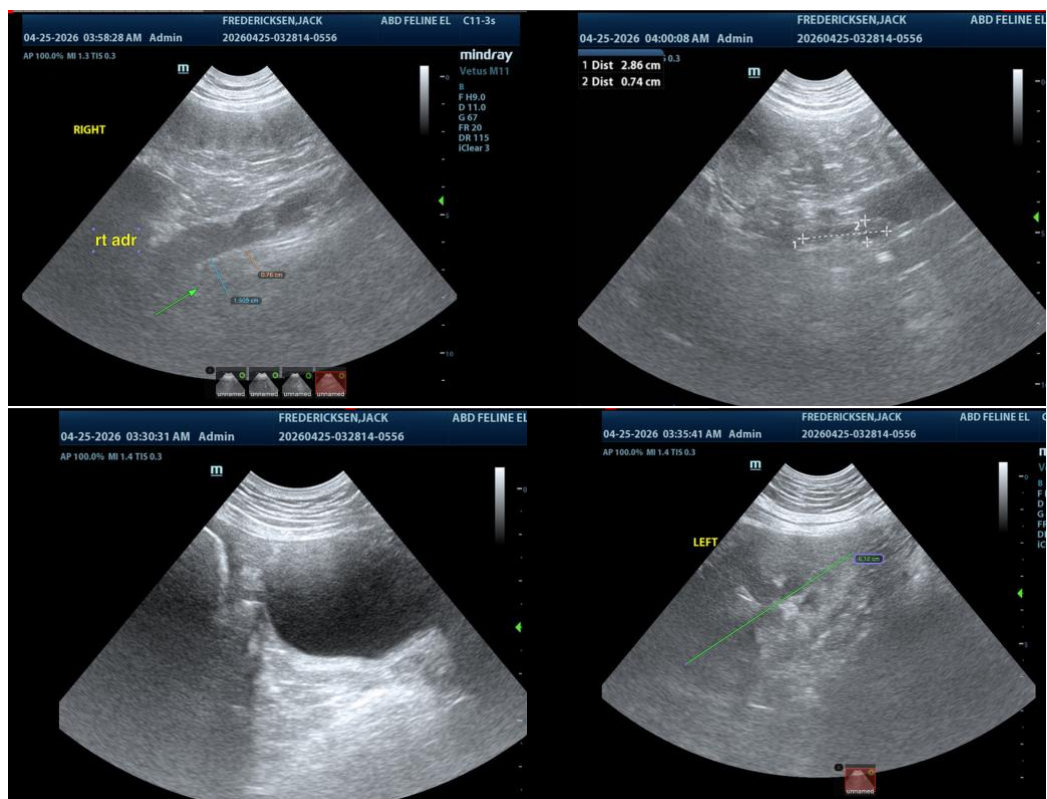
The base and limbs of the **pancreas** were observed to be largely isoechoic to surrounding omental fat. Pancreatic duct and capsular contour were acceptably normal and parenchyma respected normal curvilinear patterns. No overt evidence of active inflammatory or neoplastic disease was noted.

ULTRASONOGRAPHIC FINDINGS

- Structurally unremarkable abdomen.

INTERPRETATION OF THE FINDINGS & FURTHER RECOMMENDATIONS

No evidence of pathology. The cause of clinical signs is not evident. Screening for occult Addison's is warranted, even though the adrenals measure normal.





PATIENT

Jack Fredericksen

SPECIES

Canine

BREED

Airedale Terrier

SEX

Neutered Male

AGE

1.5

WEIGHT

36.8

INTERPRETED BY

Eric Lindquist, DMV,
DABVP(CFM), Cert.
IVUSS

IMAGING PERFORMED BY

Dr. Stephanie
Permenter

HOSPITAL NAME

Viking Veterinary
Hospital- Moscow

REFERRING VET

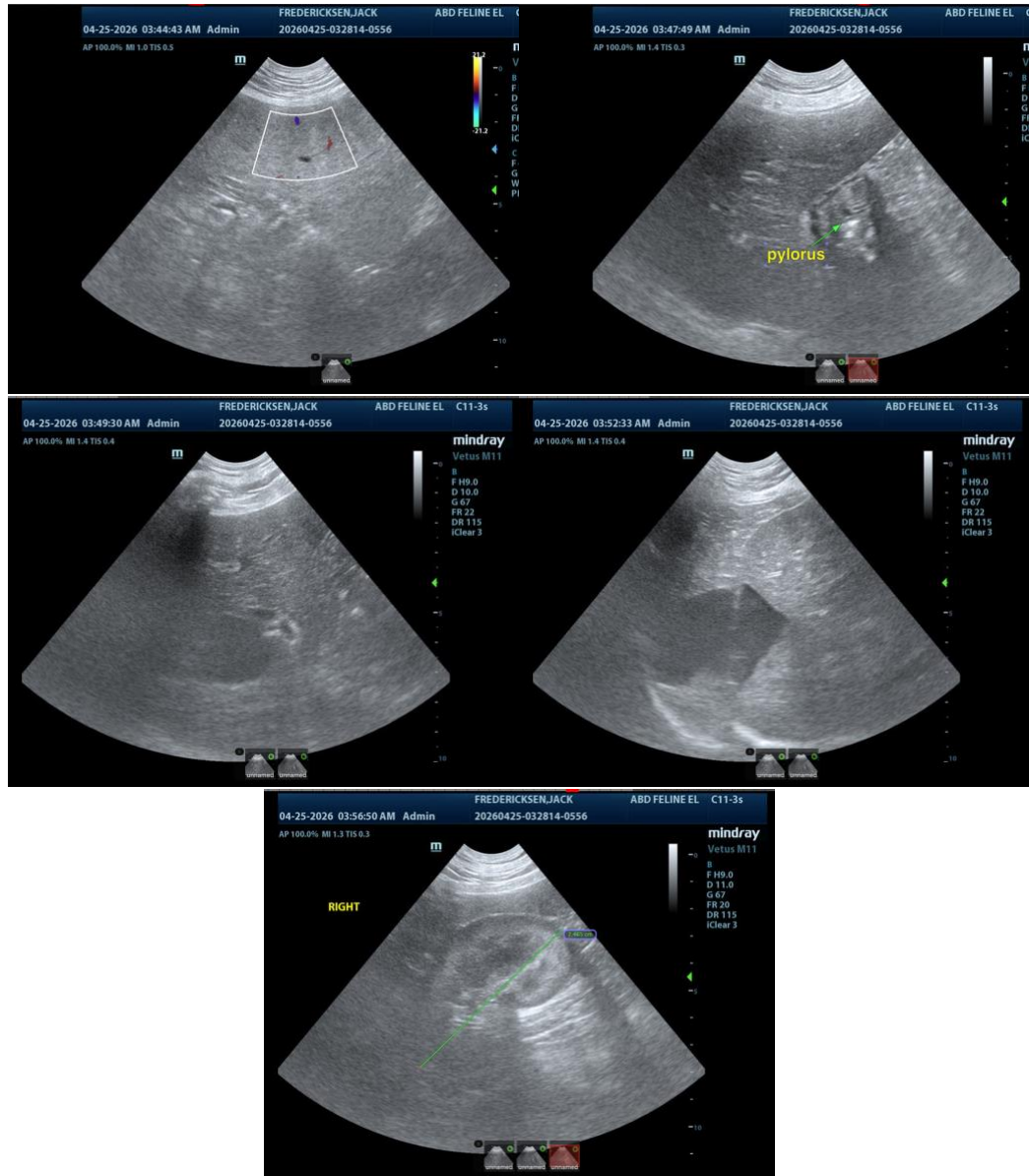
Dr. Stephanie
Permenter

INVOICE

15478

DATE

04/25/26



The information and recommendations provided are based on the images presented by the referring veterinarian/sonographer. No evaluation can be communicated regarding pathology that was not visible in the image/video clips provided.

Thank you for this referral. If the clinical or image interpretation does not parallel your findings or if I can be of any further assistance, please contact me.

Eric Lindquist, DMV, DABVP(CFM), Cert. IVUSS,

CEO, Owner, Founder -- SonoPath.com

info@SonoPath.com



PATIENT

Jack Fredericksen

SPECIES

Canine

BREED

Airedale Terrier

SEX

Neutered Male

AGE

1.5

WEIGHT

36.8

INTERPRETED BY

Eric Lindquist, DMV,
DABVP(CFM), Cert.
IVUSS

IMAGING PERFORMED BY

Dr. Stephanie
Permenter

HOSPITAL NAME

Viking Veterinary
Hospital- Moscow

REFERRING VET

Dr. Stephanie
Permenter

INVOICE

15478

DATE

04/25/26