



PATIENT

Meow Meow
Shuanping

SPECIES

Feline

BREED

Domestic Longhair

SEX

Spayed female

AGE

12 years

WEIGHT

9.6 lbs

INTERPRETED BY

Eric Lindquist, DMV
DABVP, Cert. IVUSS

IMAGING PERFORMED BY

Jenn

HOSPITAL NAME

Rockaway AH

REFERRING VET

Dr. Maniar

INVOICE

43974

DATE

4/25/23

PRESENTING CLINICAL SIGNS

History: lethargic decreased appetite for 2 days Hx of diabetes

ULTRASONOGRAPHIC EXAMINATION OF THE HEART

The echocardiogram in this patient demonstrated volume overload and subnormal contractility with dilation of all four chambers. Mitral and tricuspid insufficiency was present. Trace pericardial effusion was noted and moderate pleural effusion was noted.

FELINE CARDIAC PARAMETERS	BODY WEIGHT (kg)	HR (BPM)	IVSd (cm)	LVIDd (cm)	LVWd (cm)	FS (%)	EF (%)
NORMAL PARAMETER	-----	150-240	0.3-0.6	1.0-2.1	0.25-0.6	35-67	80-100
PATIENT		NM	0.46	2.17		25	
FELINE CARDIAC PARAMETERS	LA/AO (Boon)	LA/AO HEART BASE (Sisson)	LA 2D 4-chamber long axis AS to FW (Sisson) (cm)	LVOT VEL. (m/s)	RVOT VEL. (m/s)	IVRT (m/)	
NORMAL PARAMETER	<1.5	0.88-1.79	0.7-1.7	<1.6	<1.3	40-60	
PATIENT	1.0	1.8	1.86		0.6	NM	
Adapted from June Boon, Veterinary Echocardiography, 1998 Sisson D et al. JVIM 1991; 5: 232, Jacobs et al. Am J Vet Res 1985; 46:1705							

ULTRASONOGRAPHIC FINDINGS

Consistent with DCM or end stage unclassified cardiomyopathy.

INTERPRETATION OF THE FINDINGS & FURTHER RECOMMENDATIONS

I recommend Lasix at 6.25 mg b.i.d., Pimobendan off label at 0.3 mg/kg b.i.d. and ace inhibitor at 0.5 mg/kg s.i.d. Plavix therapy is also recommended. Palliative pleurocentesis can be considered. The prognosis is guarded. Taurine supplementation and testing would be indicated. Blood pressure measurements, BUN and creatinine are recommended. Basal respiratory rate target < 25 as well as follow-up radiographs is warranted in 5-7 days. The prognosis is guarded. Recheck echocardiogram in 10-14 days if the patient is able to be stabilized.



PATIENT

Meow Meow
Shuanping

SPECIES

Feline

BREED

Domestic Longhair

SEX

Spayed female

AGE

12 years

WEIGHT

9.6 lbs

INTERPRETED BY

Eric Lindquist, DMV
DABVP, Cert. IVUSS

IMAGING PERFORMED BY

Jenn

HOSPITAL NAME

Rockaway AH

REFERRING VET

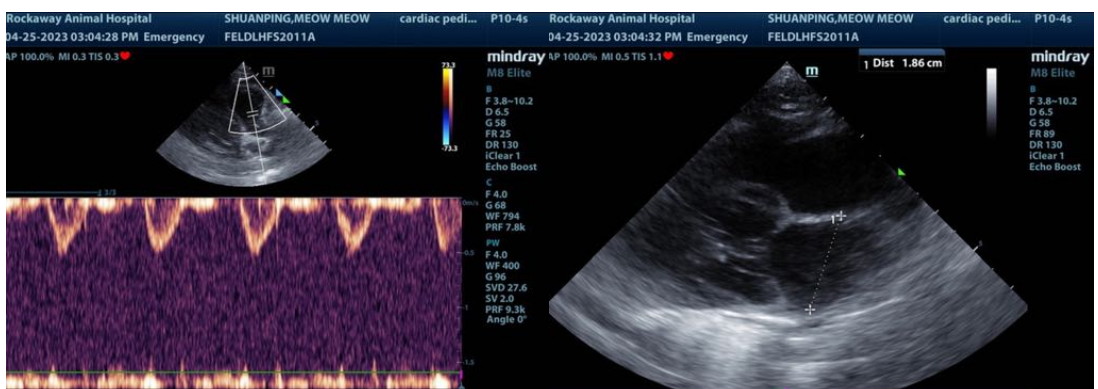
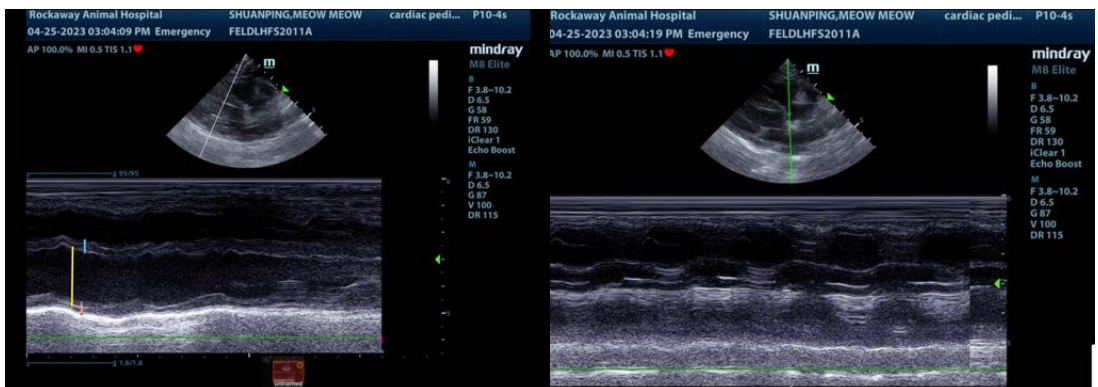
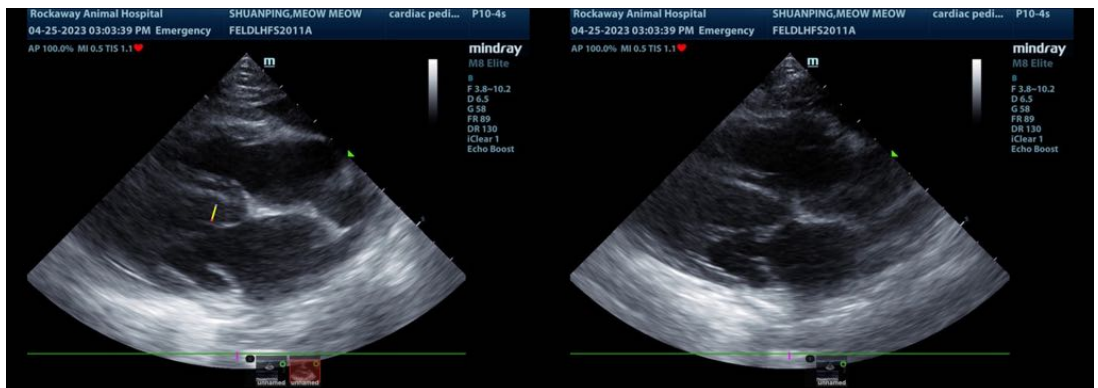
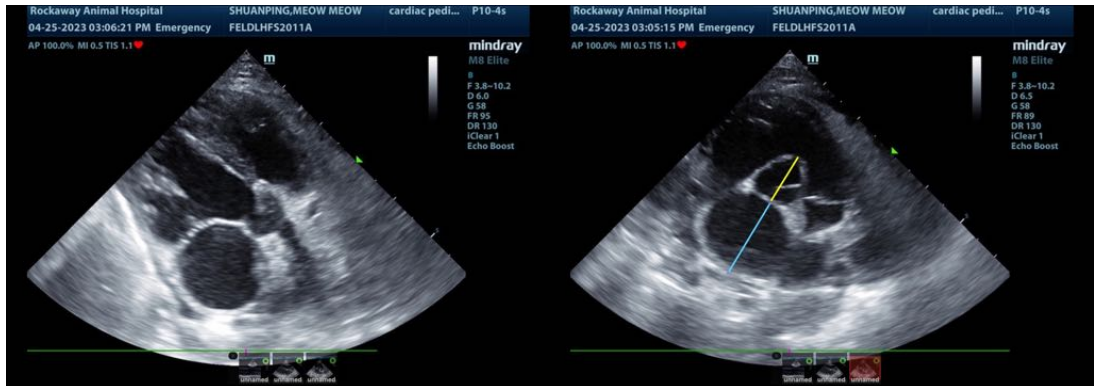
Dr. Maniar

INVOICE

43974

DATE

4/25/23





PATIENT

Meow Meow
Shuanping

SPECIES

Feline

BREED

Domestic Longhair

SEX

Spayed female

AGE

12 years

WEIGHT

9.6 lbs

INTERPRETED BY

Eric Lindquist, DMV
DABVP, Cert. IVUSS

**IMAGING
PERFORMED BY**

Jenn

HOSPITAL NAME

Rockaway AH

REFERRING VET

Dr. Maniar

INVOICE

43974

DATE

4/25/23

The information and recommendations provided are based on the images presented by the referring veterinarian/sonographer. No evaluation can be communicated regarding pathology that was not visible in the image/video clips provided.

Thank you for this referral. If the clinical or image interpretation does not parallel your findings or if I can be of any further assistance please contact me.

Eric Lindquist, DMV, DABVP, Cert. IVUSS, CEO of SonoPath.com
info@SonoPath.com