



**PATIENT PRESENTING CLINICAL SIGNS**

**Echo Sackett**  
History: P first had elevated ALT April 2022. Monitored over the past year and gradually increasing, but more marked increase in the last 3 months (was 200 U/L and then jumped to 624 U/L. No v/d/c/s, no pu/pd.

**SPECIES**  
Abnormal PE/Chem/CBC/UA Results: PE - TPR wnl, mod distended abdomen but comfortable on palpation CBC - wnl Chem - ALT 624 U/L (ALP, GGT, TBili all well wnl), Cholesterol 356 mg/dL T4 - 2.3 ug/dL 4dx - neg x 4 Fecal - NOS

Canine

**BREED ULTRASONOGRAPHIC EXAMINATION OF THE ABDOMEN**

Golden Doodle

**Urinary System**

**SEX**  
The **urinary bladder**, trigone, and pelvic urethra presented normal thicknesses and normal tone. The ureters were not visible which is normal. No uroliths or sediment were visualized and anechoic urine was present. No evidence of inflammatory or neoplastic changes was noted. Ureteral papillae were normal.

Spayed female

**AGE**

9 years

The **kidneys** revealed largely normal size and structure, corticomedullary definition and ratio (cortex 1/3 of medulla) were essentially maintained with some age-related loss of curvilinear patterns regarding the capsule and C/M junction. The cortices presented largely uniform texture with some increased echogenicity expected for his age patient. Medullary structure differed distinctly from that of the cortex and no evidence of pelvic dilation was present. Pinpoint mineralization was noted. The right kidney measured 8.92 cm. The left kidney measured 6.9 cm.

**WEIGHT**

90.9 lbs

**INTERPRETED BY**

Eric Lindquist, DMV  
DABVP, Cert. IVUSS

**Adrenal Glands**

Both **adrenal glands** were visualized and recognized as having normal shape, size, position and echogenicity for this breed. The phrenic vasculature, glandular echogenicity and detail were unremarkable. Capsule, cortex, and medullary definition were normal for this age patient. The left adrenal gland measured 0.5 cm. The right adrenal gland measured 0.8 cm at the cranial pole and 0.5 cm at the caudal pole.

**IMAGING PERFORMED BY**

Dr. Fritz

**HOSPITAL NAME**

Waterbury VH

**Spleen**

The **spleen** revealed an expansive, hypoechoic nodule measuring 1.5 cm. The nodule disrupted architecture.

**REFERRING VET**

Dr. Fritz

**Liver**

The **liver** images from right and left intercostal as well as subcostal views revealed subjectively normal liver size, contour, and structure. Some age-related parenchymal remodeling was noted but likely not clinically significant at this time. Vascular and biliary tracts were of normal volume and no evidence of congestion was noted. The gallbladder presented some dependent debris with essentially normal contour. The cystic and common bile ducts were normal. No overt evidence of active inflammatory, infiltrative or regenerative pathology was noted but should be paired with current or past LE elevations regarding any clinical significance to this presentation. The hepatic lymph nodes were unremarkable.

**INVOICE**

43993

**DATE**

4/25/23



**PATIENT**

Echo Sackett

**SPECIES**

Canine

**BREED**

Golden Doodle

**SEX**

Spayed female

**AGE**

9 years

**WEIGHT**

90.9 lbs

**INTERPRETED BY**

Eric Lindquist, DMV  
DABVP, Cert. IVUSS

**IMAGING PERFORMED BY**

Dr. Fritz

**HOSPITAL NAME**

Waterbury VH

**REFERRING VET**

Dr. Fritz

**INVOICE**

43993

**DATE**

4/25/23

**Gastrointestinal**

Examination of the **gastrointestinal tract** revealed a stomach and intestine free of stasis, of normal wall thickness, acceptable curvilinear mural detail, and peristaltic activity. Small and large intestine demonstrated normal luminal chyme and stool consistency respectively. No obstructive or overt infiltrative disease was noted. No associated abnormal lymphatic activity was noted.

**Pancreas**

The base and limbs of the **pancreas** were observed to be largely isoechoic to surrounding omental fat. Pancreatic duct and capsular contour were acceptably normal and parenchyma respected normal curvilinear patterns. No overt evidence of active inflammatory or neoplastic disease was noted.

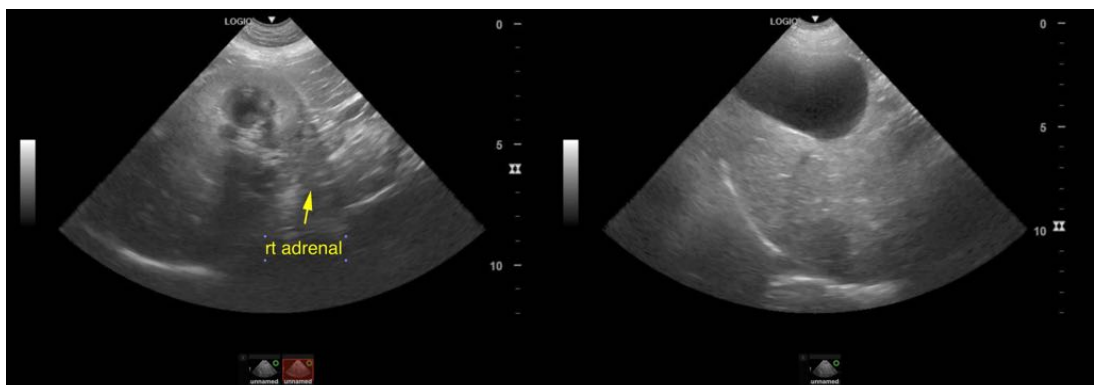
**ULTRASONOGRAPHIC FINDINGS**

Expansive splenic nodule. Strong concern for round cell neoplasia or hemangiosarcoma. Nodular hyperplasia is possible, yet less likely.

Non-specific inflammatory hepatopathy.

**INTERPRETATION OF THE FINDINGS & FURTHER RECOMMENDATIONS**

There is no evidence of metastatic disease. Chest radiographs and echocardiogram are warranted for metastatic screening followed by splenectomy, liver inspection and biopsy. There was no evidence of metastatic disease. This is an incidental finding, yet concerning.





**PATIENT**

Echo Sackett

**SPECIES**

Canine

**BREED**

Golden Doodle

**SEX**

Spayed female

**AGE**

9 years

**WEIGHT**

90.9 lbs

**INTERPRETED BY**

Eric Lindquist, DMV  
DABVP, Cert. IVUS

**IMAGING PERFORMED BY**

Dr. Fritz

**HOSPITAL NAME**

Waterbury VH

**REFERRING VET**

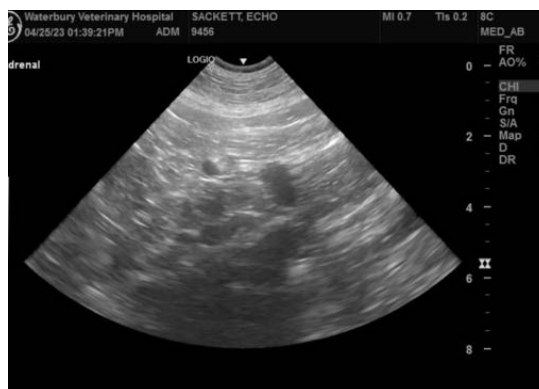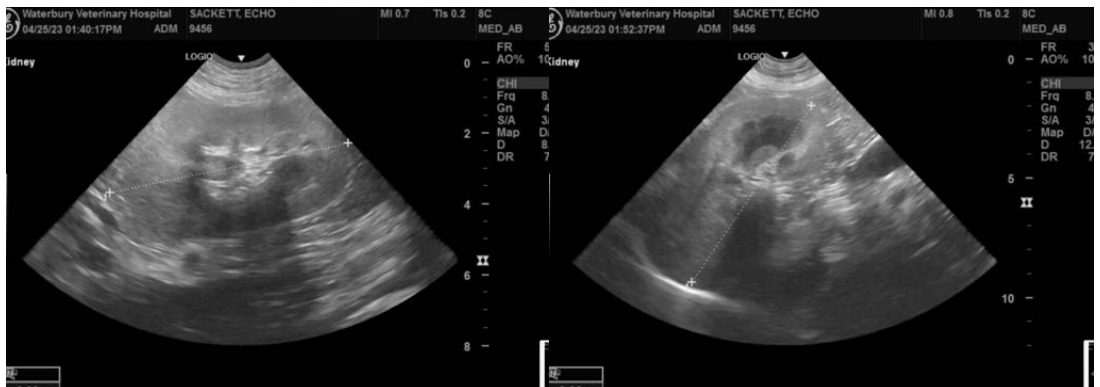
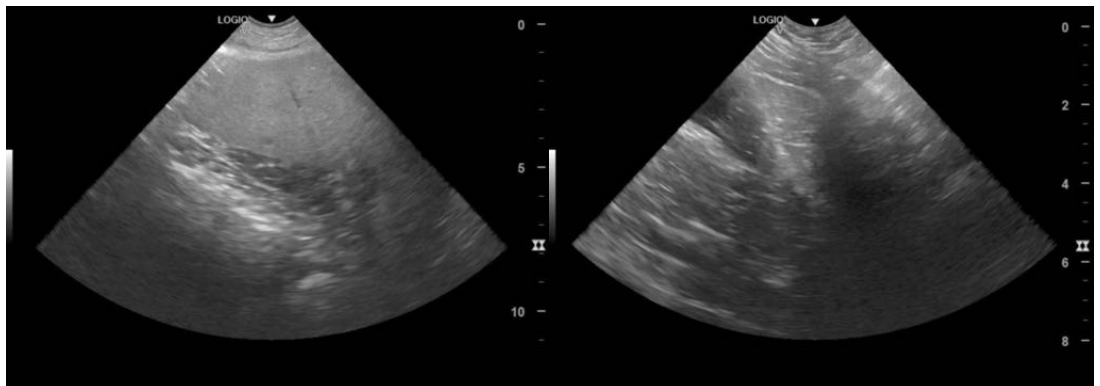
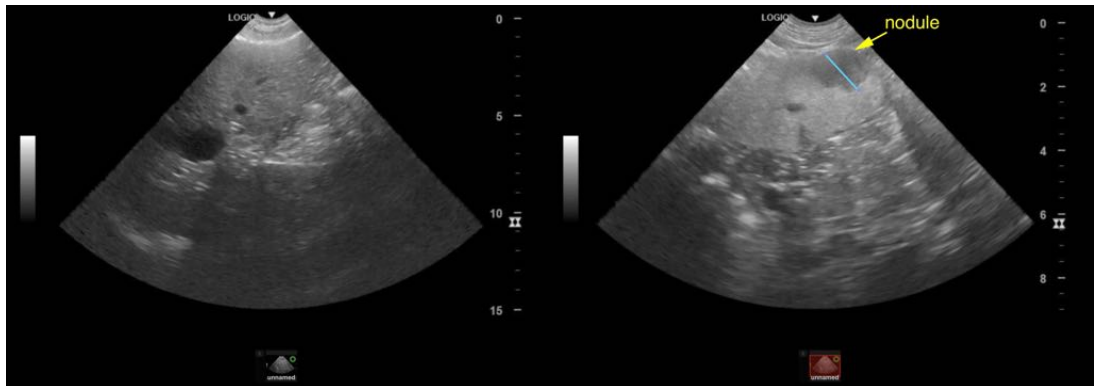
Dr. Fritz

**INVOICE**

43993

**DATE**

4/25/23





**PATIENT**

Echo Sackett

The information and recommendations provided are based on the images presented by the referring veterinarian/sonographer. No evaluation can be communicated regarding pathology that was not visible in the image/video clips provided.

**SPECIES**

Canine

Thank you for this referral. If the clinical or image interpretation does not parallel your findings or if I can be of any further assistance please contact me.

**BREED**

Golden Doodle

**Eric Lindquist**, DMV, DABVP, Cert. IVUSS, CEO of SonoPath.com  
info@SonoPath.com

**SEX**

Spayed female

**AGE**

9 years

**WEIGHT**

90.9 lbs

**INTERPRETED BY**

Eric Lindquist, DMV  
DABVP, Cert. IVUSS

**IMAGING  
PERFORMED BY**

Dr. Fritz

**HOSPITAL NAME**

Waterbury VH

**REFERRING VET**

Dr. Fritz

**INVOICE**

43993

**DATE**

4/25/23