



PATIENT

Sophie Marchigiano

PRESENTING CLINICAL SIGNS

History: current spindle cell hx of mast cell

SPECIES

Feline

ULTRASONOGRAPHIC EXAMINATION OF THE ABDOMEN

Urinary System

BREED

Domestic Shorthair

The **urinary bladder**, trigone, and pelvic urethra presented normal thicknesses and normal tone. The ureters were not visible which is normal. No uroliths or sediment were visualized and anechoic urine was present. No evidence of inflammatory or neoplastic changes was noted. Ureteral papillae were normal.

SEX

Spayed Female

The **kidneys** revealed largely normal size and structure, corticomedullary definition and ratio (cortex 1/3 of medulla) were essentially maintained with some age-related loss of curvilinear patterns regarding the capsule and C/M junction. The cortices presented largely uniform texture with some increased echogenicity expected for this age patient. Medullary structure differed distinctly from that of the cortex and no evidence of pelvic dilation was present. The left kidney measured 5.83 cm. The right kidney measured 7.19 cm.

AGE

9 years

WEIGHT

71.2 lbs

Adrenal Glands

The left **adrenal gland** was uniform and measured 0.5 cm. The right adrenal gland was slightly irregular, heterogenous and measured 1.2 cm.

INTERPRETED BY

Eric Lindquist, DMV
DABVP, Cert. IVUSS

Spleen

The **spleen** in this patient was mildly enlarged with uniform parenchyma and was folded upon itself cranially. This is a positional variant and is not pathological. There was no evidence of significant disease.

IMAGING PERFORMED BY

Evanna

Liver

HOSPITAL NAME

Animal Care Clinic of
Flanders

The **liver** images submitted revealed subjectively normal liver size, contour, and structure. Parenchymal echogenicity was naturally coarse and hypoechoic to the spleen. Vascular and biliary tracts were of normal volume with no evidence of congestion. The gallbladder presented acceptably thin walls with primarily anechoic content. The cystic and common bile ducts were normal. No pathological hepatic lymphadenopathy was evident. No overt structural evidence of inflammatory, infiltrative or regenerative pathology was evident.

REFERRING VET

Dr. Villari

INVOICE

99509

Gastrointestinal

Examination of the **gastrointestinal tract** revealed a stomach and intestine free of stasis, of normal wall thickness, acceptable curvilinear mural detail, and peristaltic activity. Small and large intestine demonstrated normal luminal chyme and stool consistency respectively. No obstructive or overt infiltrative disease was noted. No associated abnormal lymphatic activity was noted.

DATE

4/25/22



PATIENT

Pancreas

Sophie Marchigiano

The base and limbs of the **pancreas** were observed to be largely isoechoic to surrounding omental fat. Pancreatic duct and capsular contour were acceptably normal and parenchyma respected normal curvilinear patterns. No overt evidence of active inflammatory or neoplastic disease was noted.

SPECIES

Feline

ULTRASONOGRAPHIC FINDINGS

BREED

Domestic Shorthair

Heterogenous right adrenal gland.

Otherwise, unremarkable abdomen.

SEX

Spayed Female

INTERPRETATION OF THE FINDINGS & FURTHER RECOMMENDATIONS

There was no evidence of lesions that would be consistent with mast cell disease.

AGE

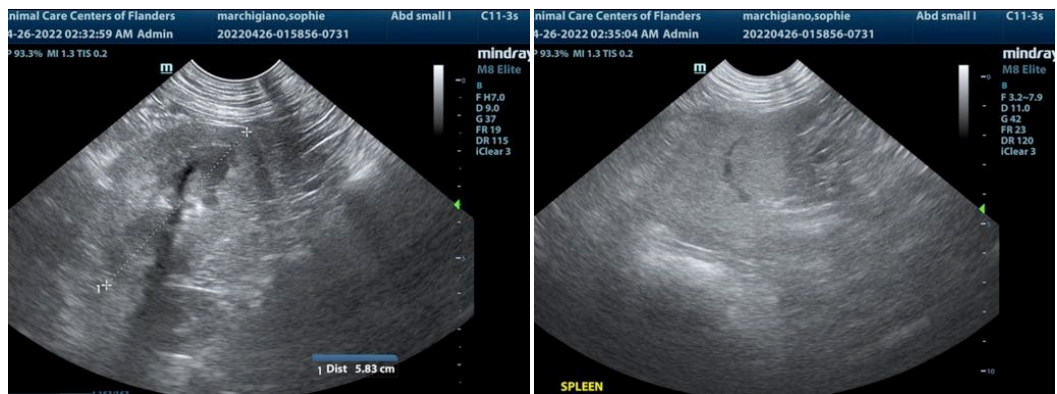
9 years

WEIGHT

71.2 lbs

INTERPRETED BY

Eric Lindquist, DMV
DABVP, Cert. IVUSS



IMAGING PERFORMED BY

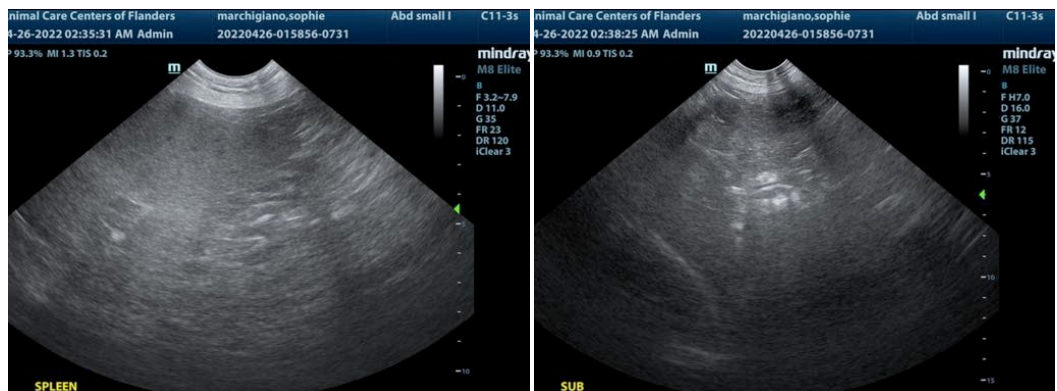
Evanna

HOSPITAL NAME

Animal Care Clinic of
Flanders

REFERRING VET

Dr. Villari



INVOICE

99509

DATE

4/25/22



PATIENT

Sophie Marchigiano

SPECIES

Feline

BREED

Domestic Shorthair

SEX

Spayed Female

AGE

9 years

WEIGHT

71.2 lbs

INTERPRETED BY

Eric Lindquist, DMV
DABVP, Cert. IVUSS

IMAGING PERFORMED BY

Evanna

HOSPITAL NAME

Animal Care Clinic of
Flanders

REFERRING VET

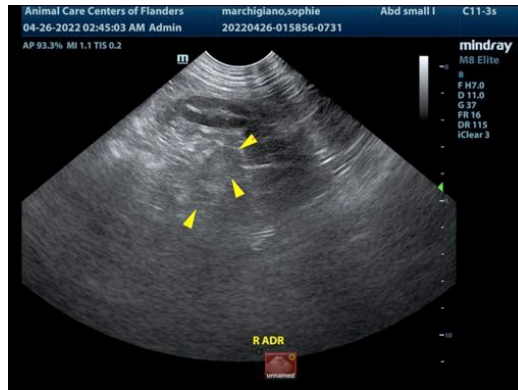
Dr. Villari

INVOICE

99509

DATE

4/25/22



The information and recommendations provided are based on the images presented by the referring veterinarian/sonographer. No evaluation can be communicated regarding pathology that was not visible in the image/video clips provided.

Thank you for this referral. If the clinical or image interpretation does not parallel your findings or if I can be of any further assistance please contact me.

Eric Lindquist, DMV, DABVP, Cert. IVUSS, CEO of SonoPath.com
info@SonoPath.com