



PATIENT

Rita Chirstopher

PRESENTING CLINICAL SIGNS

Chronic vomiting - every other day
Abnormal PE/Chem/CBC/UA Results: CBC, CHEM, T4, UA, blood pressure normal

SPECIES

Feline

ULTRASONOGRAPHIC EXAMINATION OF THE ABDOMEN

Urinary System

BREED

Siamese Cross

The **urinary bladder**, trigone, and pelvic urethra presented normal thicknesses and normal tone. The ureters were not visible which is normal. No uroliths or sediment were visualized and anechoic urine was present. No evidence of inflammatory or neoplastic changes was noted. Ureteral papillae were normal.

SEX

Spayed Female

The **kidneys** revealed normal size and structure, corticomedullary definition and ratio for this age. The cortices presented largely uniform texture with normal echogenic relationship to liver and spleen. Medullary structure differed distinctly from the cortex and no evidence of pelvic dilation was present. The capsules were acceptably uniform without significant irregularities. The left kidney measured 3.77 cm. The right kidney measured 4.0 cm with slight pinpoint mineralization.

AGE

15 years

WEIGHT

6.5 lbs

Adrenal Glands

Both **adrenal glands** were visualized and recognized as having normal shape, size, position and echogenicity for this breed. The phrenic vasculature, glandular echogenicity and detail were unremarkable. Capsule, cortex, and medullary definition were normal for this age patient. The left adrenal gland measured 0.39 cm. The right adrenal gland measured 0.4 cm.

INTERPRETED BY

Eric Lindquist, DMV
DABVP, Cert. IVUSS

Spleen

IMAGING PERFORMED BY

Dr. Gunther

The **spleen** presented a smooth homogeneous parenchyma hyperechoic to liver and renal cortical parenchyma. The capsule was smooth without noticeable expansion or deviation from within the spleen or adjacent pathology. The splenic vasculature demonstrated normal volume without signs of congestion or thrombosis. No sonographic evidence of acute or chronic inflammatory, neoplastic, or infarctual changes was noted.

HOSPITAL NAME

New Frontier AMC

Liver

REFERRING VET

Dr. Gunther

The **liver** revealed a cystic and parenchymal mass that measured 3.8 x 2.4 cm and occupied the left medial liver. The mass appeared to be a coalescence of the cystic changes. Other cystic and nodular changes were noted throughout the liver. The gallbladder was unremarkable.

INVOICE

99514

DATE

4/25/22



PATIENT

Gastrointestinal

Rita Christoph

The **stomach** revealed a fluid filled lumen. This was structurally unremarkable. The small intestine was fluid filled with mild thickening, yet there was no evidence of masses or foreign bodies. Spastic bowel was noted in portions of the small intestine. The colon was unremarkable.

SPECIES

Feline

Pancreas

BREED

Siamese Cross

The **pancreas** was heterogenous and nodular without significant disruption of architecture.

SEX

Spayed Female

Primary polycystic liver with the possibility of carcinoma.

AGE

15 years

Fluid filled stomach and small intestine noted. Non-specific gastrointestinal upset. Regional stasis.

Heterogenous and nodular pancreas.

INTERPRETATION OF THE FINDINGS & FURTHER RECOMMENDATIONS

WEIGHT

6.5 lbs

FNA of the various nodular changes noted in the liver are recommended. Underlying inflammatory bowel and history of pancreatitis is likely. However, the level of active inflammation is debatable. A clinical trial of the following is recommended. Bile acid profile is warranted given the diffuse hepatic changes to assess if any early dysfunction is an issue.

INTERPRETED BY

Eric Lindquist, DMV
DABVP, Cert. IVUSS

IMAGING PERFORMED BY

Dr. Gunther

HOSPITAL NAME

New Frontier AMC

REFERRING VET

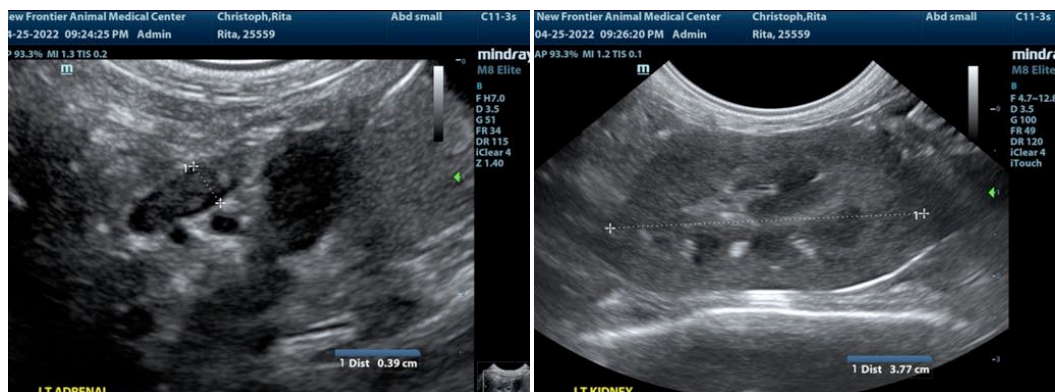
Dr. Gunther

INVOICE

99514

DATE

4/25/22





PATIENT

Rita Christoph

SPECIES

Feline

BREED

Siamese Cross

SEX

Spayed Female

AGE

15 years

WEIGHT

6.5 lbs

INTERPRETED BY

Eric Lindquist, DMV
DABVP, Cert. IVUSS

IMAGING PERFORMED BY

Dr. Gunther

HOSPITAL NAME

New Frontier AMC

REFERRING VET

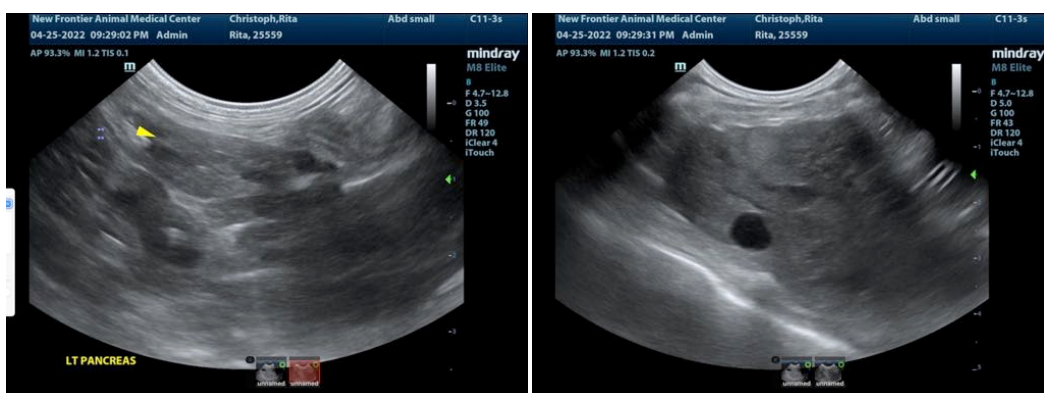
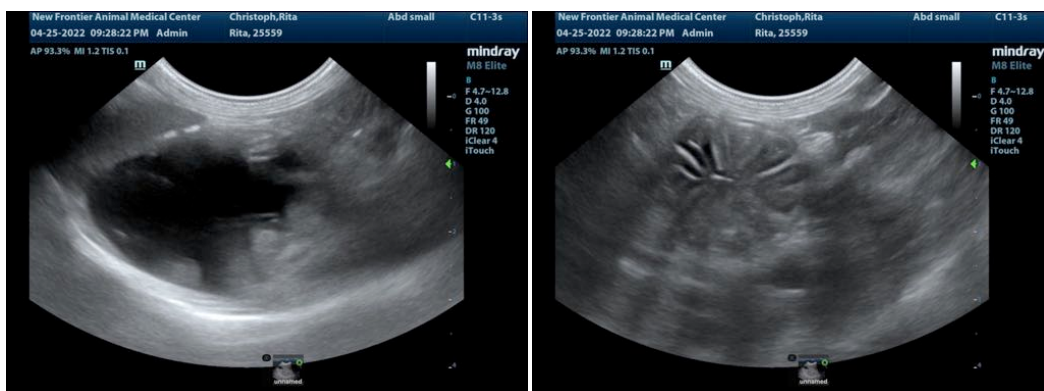
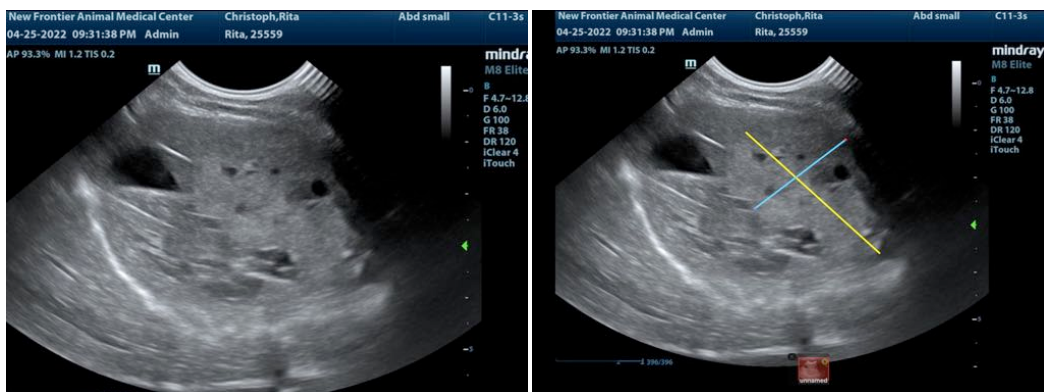
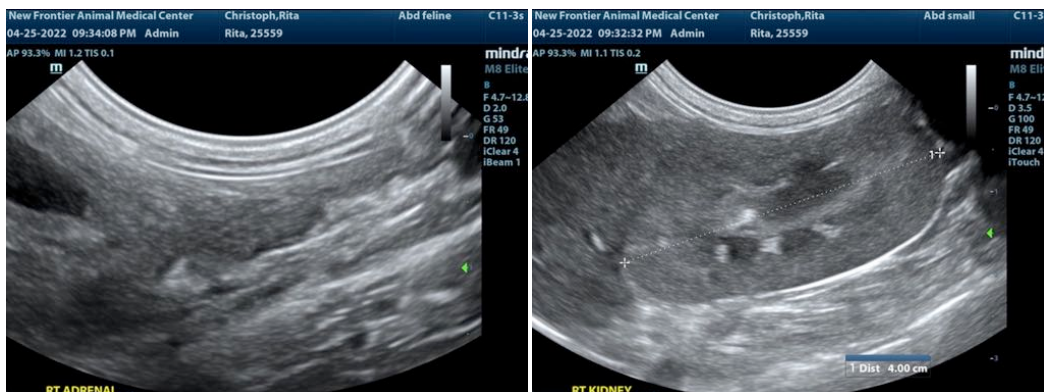
Dr. Gunther

INVOICE

99514

DATE

4/25/22





PATIENT

Rita Christoph

SPECIES

Feline

BREED

Siamese Cross

SEX

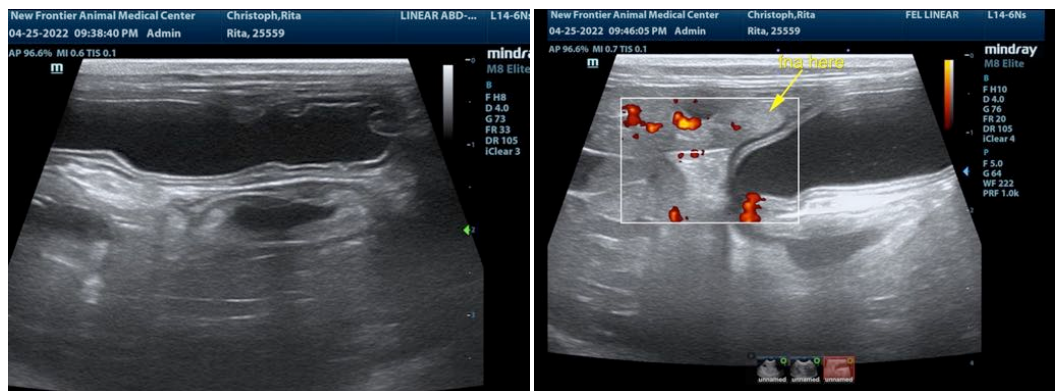
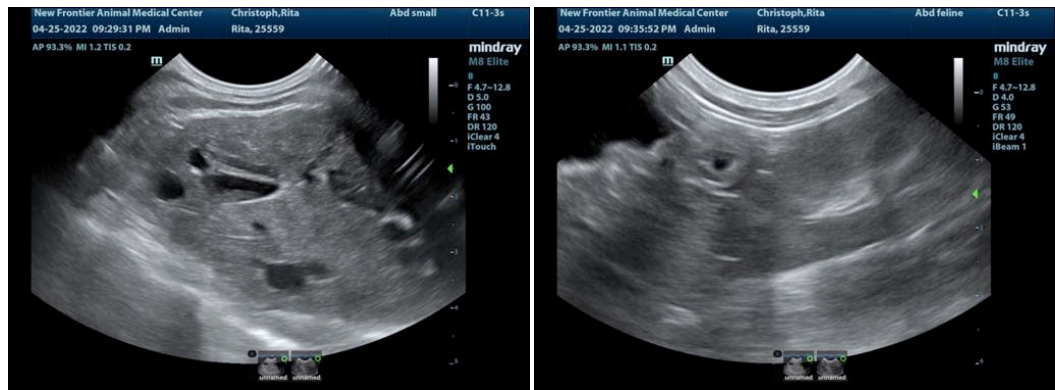
Spayed Female

AGE

15 years

WEIGHT

6.5 lbs



INTERPRETED BY

Eric Lindquist, DMV
DABVP, Cert. IVUSS

IMAGING PERFORMED BY

Dr. Gunther

HOSPITAL NAME

New Frontier AMC

REFERRING VET

Dr. Gunther

INVOICE

99514

DATE

4/25/22

The information and recommendations provided are based on the images presented by the referring veterinarian/sonographer. No evaluation can be communicated regarding pathology that was not visible in the image/video clips provided.

Thank you for this referral. If the clinical or image interpretation does not parallel your findings or if I can be of any further assistance please contact me.

Eric Lindquist, DMV, DABVP, Cert. IVUSS, CEO of SonoPath.com
info@SonoPath.com