



PATIENT

Louie Sessa

SPECIES

Canine

BREED

Yorkie

SEX

Neutered male

AGE

10 years

WEIGHT

11 lbs

INTERPRETED BY

Eric Lindquist, DMV
DABVP, Cert. IVUSS

IMAGING PERFORMED BY

Dr. Gabriel

HOSPITAL NAME

Central Jersey AH

REFERRING VET

Dr. Gabriel

INVOICE

99515

DATE

4/25/22

PRESENTING CLINICAL SIGNS

History: presented 2 days ago for not eating, lethargic and acting sluggish, owner reported that he is walking wobbly and disoriented at home and cant stand steady, has hx of proteinuria and currently is taking benazepril also has hx of allergy and on apoquel. patient was admitted for iv supportive care with cerenia, famotidine, ondasetron, buprenex and metronidazole, ampicillin
Abnormal PE/Chem/CBC/UA Results: cbc,chem: wnl u/a: 3+ protein in urine cpl: positive xray: splenomegaly sever abdominal pain on palpation temp 104 f initially, now it is normal

ULTRASONOGRAPHIC EXAMINATION OF THE ABDOMEN

Urinary System

The **urinary bladder**, trigone, and pelvic urethra presented normal thicknesses and normal tone. The ureters were not visible which is normal. Small bladder calculus was noted and measured 0.4 cm. Non-obstructive at the time of the sonogram. No evidence of inflammatory or neoplastic changes was noted. Ureteral papillae were normal.

The **kidneys** revealed largely normal size and structure, corticomedullary definition and ratio (cortex 1/3 of medulla) were essentially maintained with some age-related loss of curvilinear patterns regarding the capsule and C/M junction. The cortices presented largely uniform texture with some increased echogenicity expected for this age patient. Medullary structure differed distinctly from that of the cortex and no evidence of pelvic dilation was present. The left kidney measured 4.0 cm.

Adrenal Glands

The left **adrenal gland** is slightly enlarged at the caudal pole measuring 0.66 cm and 0.43 cm at the cranial pole. The right adrenal gland was uniform and measured 0.6 cm.

Spleen

The **spleen** was folded upon itself caudally with uniform enlargement. This is likely reactive state. There is no disruption of architecture. If any weight loss is present FNA is indicated.

Liver

The **liver** images submitted revealed subjectively normal liver size, contour, and structure. Parenchymal echogenicity was naturally coarse and hypoechoic to the spleen. Hepatic veins were dilated in this patient. This may be normal if the patient was sedated. However, this may be normal if the patient was sedated. However, if not sedated an echocardiogram and thoracic radiographs are recommended to assess for causes of passive congestion. The gallbladder presented acceptably thin walls with primarily anechoic content. The cystic and common bile ducts were normal. Lung consolidations were noted through the diaphragm.



PATIENT

Gastrointestinal

Louie Sessa

Examination of the **gastrointestinal tract** revealed a stomach and intestine free of stasis, of normal wall thickness, acceptable curvilinear mural detail, and peristaltic activity. Small and large intestine demonstrated normal luminal chyme and stool consistency respectively. No obstructive or overt infiltrative disease was noted. No associated abnormal lymphatic activity was noted.

SPECIES

Canine

BREED

Yorkie

Pancreas

The base and limbs of the **pancreas** were observed to be largely isoechoic to surrounding omental fat. Pancreatic duct and capsular contour were acceptably normal and parenchyma respected normal curvilinear patterns. No overt evidence of active inflammatory or neoplastic disease was noted.

SEX

Neutered male

ULTRASONOGRAPHIC FINDINGS

Passive congestion liver pattern.

AGE

10 years

Lung consolidation noted through the diaphragm.

Small bladder calculi.

WEIGHT

11 lbs

INTERPRETATION OF THE FINDINGS & FURTHER RECOMMENDATIONS

Chest radiographs are warranted to assess for pulmonary disease that may be related to the clinical signs. Thoracic disease is suspected as the primary cause of the clinical signs. Echocardiogram is recommended as well.

INTERPRETED BY

Eric Lindquist, DMV
DABVP, Cert. IVUSS

IMAGING PERFORMED BY

Dr. Gabriel

HOSPITAL NAME

Central Jersey AH

REFERRING VET

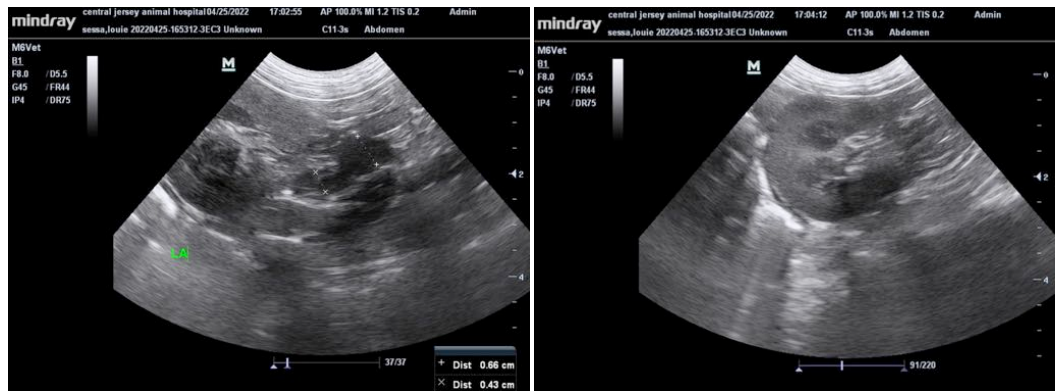
Dr. Gabriel

INVOICE

99515

DATE

4/25/22





PATIENT

Louie Sessa

SPECIES

Canine

BREED

Yorkie

SEX

Neutered male

AGE

10 years

WEIGHT

11 lbs

INTERPRETED BY

Eric Lindquist, DMV
DABVP, Cert. IVUSS

IMAGING PERFORMED BY

Dr. Gabriel

HOSPITAL NAME

Central Jersey AH

REFERRING VET

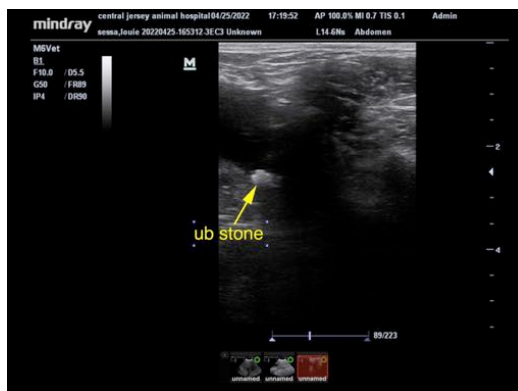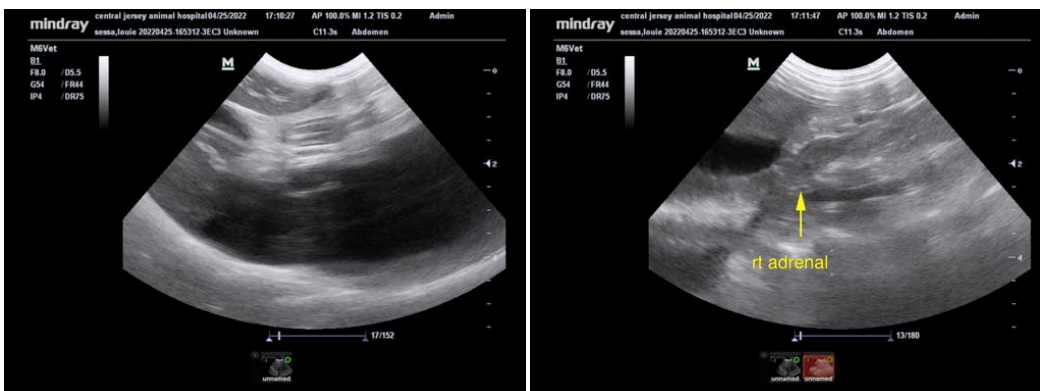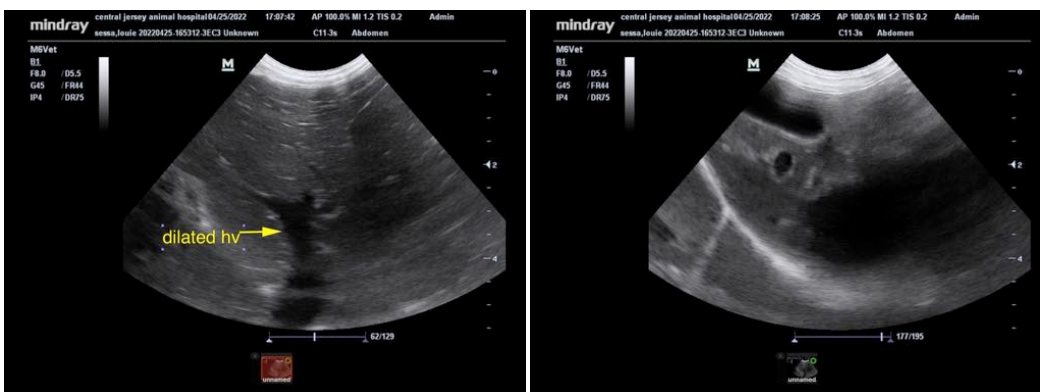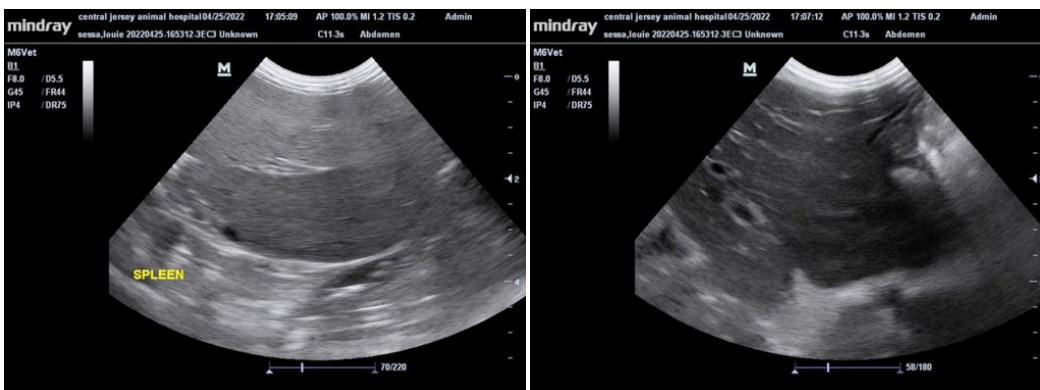
Dr. Gabriel

INVOICE

99515

DATE

4/25/22





PATIENT

Louie Sessa

The information and recommendations provided are based on the images presented by the referring veterinarian/sonographer. No evaluation can be communicated regarding pathology that was not visible in the image/video clips provided.

SPECIES

Canine

Thank you for this referral. If the clinical or image interpretation does not parallel your findings or if I can be of any further assistance please contact me.


BREED

Yorkie

Eric Lindquist, DMV, DABVP, Cert. IVUSS, CEO of SonoPath.com
info@SonoPath.com

SEX

Neutered male



The following is an applicable excerpt from the *Curbside Guide to Diagnosis & Treatment of Sonographic Disease* offered by [SonoPath.com](http://sonopath.com) Lindquist, Frank, Lobetti, and Modler.

An essential quick guide for every general practitioner and sonographer.

<https://sonopath.com/products/curbside-guide-editing-due-release-12012015>

AGE

10 years

Fever of Unknown Origin

<http://www.sonopath.com/FUO>

WEIGHT

11 lbs

INTERPRETED BY

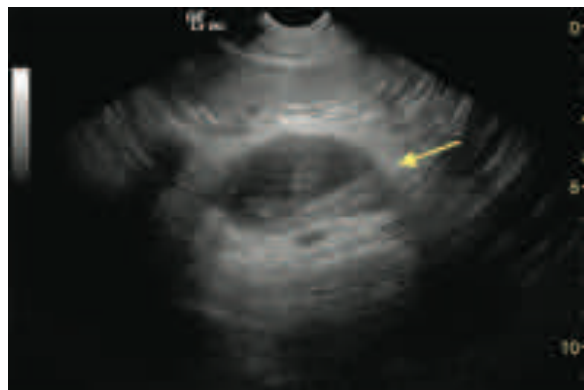Eric Lindquist, DMV
DABVP, Cert. IVUSS

IMAGING PERFORMED BY

Dr. Gabriel

HOSPITAL NAME

Central Jersey AH



Long axis of the mid-abdomen in a dog with an omental abscess after foreign body penetration from the gastrointestinal tract. The hypoechoic necrotic center of the lesion is surrounded by a thick echogenic capsule and hyperechoic mesenteric fat (arrow) indicating focal peritonitis. The linear echogenic needle (5 cm depth) is barely visible owing to the density of the purulent material contained within the abscess.

REFERRING VET

Dr. Gabriel

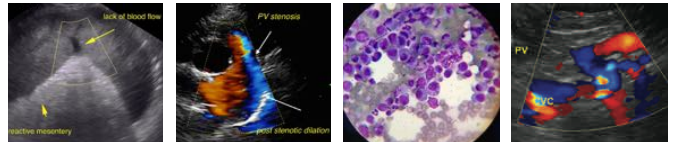
Description: The definition of a fever of unknown origin (FUO) has not been clearly defined for animals. Currently, it is either understood to be a fever that does not resolve within the period one would expect for a “self-limiting infection” being treated with appropriate antimicrobial therapy, or that for which an underlying diagnosis has not been determined despite considerable diagnostic effort. The common causes of FUO were summarized concisely in a presentation at the American College of Veterinary Internal Medicine 2004 Forum. The presenters synthesized information from three veterinary papers on the subject, which suggested the following:

INVOICE

99515

DATE

4/25/22



| PATIENT | Final Diagnosis | Bennett (dogs & cats) | Dunn and Dunn (dogs only) | Lunn (dogs & one cat) | Total | Percent |
|----------------|----------------------------|-----------------------|---------------------------|-----------------------|-------|---------|
| Louie Sessa | Infection | 21 | 16 | 10 | 47 | 28 |
| SPECIES | Immune | 18 | 22 | 6 | 46 | 27 |
| Canine | Bone marrow disease | 4 | 22 | 2 | 28 | 16 |
| BREED | Neoplasia (outside marrow) | 0 | 10 | 2 | 12 | 7 |
| Yorkie | Miscellaneous | 2 | 12 | 2 | 16 | 9 |
| SEX | No diagnosis | 0 | 19 | 2 | 21 | 12 |
| Neutered male | TOTALS | 45 | 101 | 24 | 170 | 99 |

WEIGHT
11 lbs

INTERPRETED BY

Eric Lindquist, DMV
DABVP, Cert. IVUSS

IMAGING PERFORMED BY

Dr. Gabriel

HOSPITAL NAME

Central Jersey AH

REFERRING VET

Dr. Gabriel

INVOICE

99515

DATE

4/25/22

The types of infection diagnosed in this case series were varied, ranging from discospondylitis (8 cases), blastomycosis (6), and bacterial endocarditis (4), to leishmaniasis (1), prostatitis (1), and *Ehrlichia canis* infection (1); a multitude of other infectious causes also fell within the spectrum. Of the cases in which immune-mediated disease was found, 44% had immune-mediated polyarthritis. Bone marrow diseases included myeloproliferative disease, myelodysplasia (8), lymphocytic leukemia (8), myeloma (3), chronic granulocytic leukemia (3), lymphoblastic leukemia, and malignant histiocytosis. The types of neoplasia located outside the bone marrow included lymphoma (6), metastatic disease (2), and neoplasms of the lung, spleen, and stomach. Finally, miscellaneous diseases included hypertrophic osteodystrophy (6), meningitis (3), portosystemic shunt (3), lymphadenitis (2), panosteitis, and intervertebral disc disease. Overall, the most common causes across all cases were polyarthritis (44), lymphoid neoplasia (15), discospondylitis (8), myelodysplasia (8), hypertrophic osteodystrophy (6), and blastomycosis (6).

Clinical Signs: Animals usually present with either persistent or waxing and waning fevers ranging from 103°F to 106°F. Other clinical signs depend on the underlying cause of the fever. Careful and thorough physical examination is required to assess potential causes.

Diagnostics: FUO etiologies are partly related to geography, and thus locale or travel history should factor into a practitioner's diagnostic approach. A patient's lifestyle may also provide clues regarding exposure to certain etiologic agents. Therefore, conducting a thorough history can unveil important pieces of the diagnostic puzzle. Physical examination is especially important and should include an inspection of all accessible lymph nodes, palpation and movement of the joints, a fundic examination, a neurological evaluation, spinal and limb palpation and range of motion tests, and a rectal examination.

A minimum database should include a CBC reviewed by a clinical pathologist, as well as a biochemical profile and urinalysis. Retroviral testing should also be considered in cats. In areas where tick-borne disease is prevalent, in-house testing should be performed early. Advanced laboratory work can include: urine culture, blood culture, and infectious disease panels (PCR and/or serology). In dogs, one may screen for the following infectious agents: *Ehrlichia* spp., *Borrelia burgdorferi*, Rock Mountain Spotted Fever, *Bartonella* spp. (culture and PCR), and *Leptospira* spp. in cases of hepatic or renal involvement. In cats, one should evaluate for FeLV, FIV, feline infectious peritonitis (FIP) virus, toxoplasmosis, *Hemoplasma* spp. (*Mycoplasma*), and *Bartonella* spp. (culture and PCR). Testing for *Ehrlichia* spp., *Rickettsia* spp., and *Anaplasma phagocytophilum* can also be considered. A fungal assay is indicated if the patient



PATIENT

Louie Sessa

lives in or has had exposure to a region with a higher incidence of fungal disease. Other infectious disease tests may be performed depending on the geographical location of the pet. Screening for *Brucella* should be done in breeding dogs. Immune-mediated disease screening can include a Coomb's test, a slide agglutination test (if the patient is anemic), and an antinuclear antibody (ANA) test. Immune disease is often a diagnosis of exclusion.

SPECIES

Canine

Imaging should include thoracic radiographs, abdominal ultrasound, and/or abdominal radiographs. Ultrasound can be very useful for assessing evidence of cholangiohepatitis, pyelonephritis, chronic urinary tract infection, abscess formation, peritonitis, and neoplasia; it also permits an examination of the intra-abdominal lymph nodes. An echocardiogram can offer assessment for vegetative endocarditis, whereas spinal radiographs offer assessment for discospondylitis. In cases where all other testing has proven negative and the patient has not responded to broad-spectrum antibiotics and supportive care, arthrocentesis should be considered to evaluate for septic joint disease, immune-mediated polyarthritis, and infectious disease. Finally, one can consider assessing the cerebrospinal fluid for meningoencephalitis, GME, and meningitis/arteritis. A bone marrow exam should be performed if blood dyscrasias are noted on the CBC.

BREED

Yorkie

SEX

Neutered male

Treatment: Treatment of the fever depends entirely on the underlying cause. Ideally, a thorough diagnostic plan will yield a diagnosis that will guide the appropriate therapeutic course. However, if an exhaustive approach has not produced a definitive diagnosis and there is no response to broad-spectrum antibiotics, trial therapy with immunosuppressive agents such as prednisolone can be considered to treat presumed immune-mediated diseases. Given the potential for negative sequelae should an underlying infection be present, one must be certain that the investigation is thorough and monitor the patient's response carefully.

AGE

10 years

WEIGHT

11 lbs

Conclusion: If a documented fever has not responded to antibiotics, antipyretics, or general nursing care, it is important to obtain a diagnosis to guide more specific treatment. A systematic physical examination and thorough history-taking will help inform further diagnostics in addition to what is revealed by the minimum database.

INTERPRETED BY

Eric Lindquist, DMV
DABVP, Cert. IVUSS

IMAGING PERFORMED BY

Dr. Gabriel

HOSPITAL NAME

Central Jersey AH

REFERRING VET

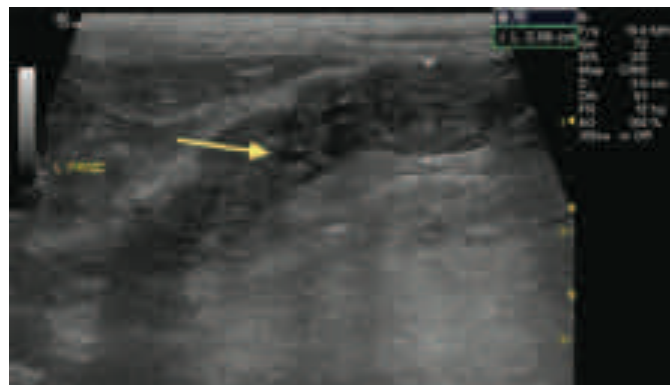
Dr. Gabriel

INVOICE

99515

DATE

4/25/22



Long axis of the left pancreatic limb (between calipers) in a cat with pancreatitis after undergoing a renal transplant. Note the decrease in echogenicity and mild loss of regular echotexture of the swollen and irregularly contoured pancreas. Also note the mild dilation of the pancreatic duct (arrow). Focal peritonitis is evident by increased echogenicity and loss of the linear echotexture of the surrounding mesentery.



PATIENT

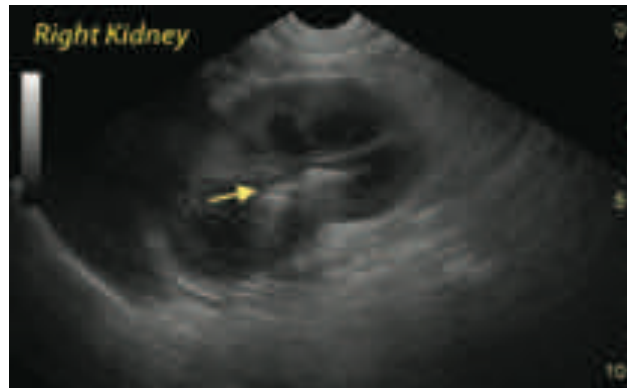Louie Sessa

SPECIES

Canine

BREED

Yorkie



Long axis of the right kidney in a dog with pyelonephritis. Note the increased echogenicity and irregular outline of the renal crest and diverticuli and the mild dilation of the renal pelvis (arrow).

SEX

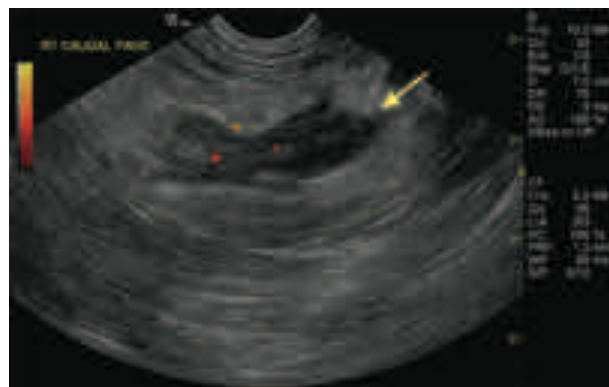Neutered male

AGE

10 years

WEIGHT

11 lbs



Long axis of the right pancreatic limb in a dog with acute pancreatitis. The swollen hypoechoic pancreas is embedded in hyperechoic mesenteric fat (arrow). Note the regional differences in blood flow intensity within the parenchyma as demonstrated by Power Doppler interrogation compatible with multifocal disruption of vascularization as a sequela of the severe inflammation.

INTERPRETED BY

Eric Lindquist, DMV
DABVP, Cert. IVUSS

IMAGING PERFORMED BY

Dr. Gabriel

HOSPITAL NAME

Central Jersey AH

REFERRING VET

Dr. Gabriel

INVOICE

99515

DATE

4/25/22

References:

Bennet D. Diagnosis of pyrexia of unknown origin. *In Practice* 1995;17(10):470-81.

Dunn KJ, Dunn JK. Diagnostic investigations in 101 dogs with pyrexia of unknown origin. *J Sm Anim Pract* 1998;39(12):574-80.

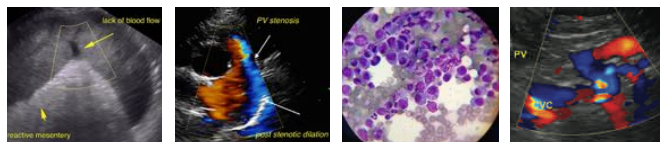
Flood J. The diagnostic approach to fever of unknown origin in cats. *Compend Contin Educ Vet* 2009;31(1):26-31.

Flood J. The diagnostic approach to fever of unknown origin in dogs. *Compend Contin Educ Vet* 2009;31(1):14-21.

Lappin MR. The role of blood borne pathogens in feline fever of unknown origin. Proceedings from the American College of Veterinary Internal Medicine, Denver, CO, June 15-18, 2011.

Lunn KF. Fever of unknown origin: a systematic approach to diagnosis. *Compend Contin Educ Vet* 2001;23(11):976-92.

Lunn KF. Fever of unknown origin: appropriate choice of diagnostic tests. Proceedings from the American College of Veterinary Internal Medicine, Minneapolis, MN, June 9-12, 2004.



PATIENT

Louie Sessa

SPECIES

Canine

BREED

Yorkie

SEX

Neutered male

AGE

10 years

WEIGHT

11 lbs

INTERPRETED BY

Eric Lindquist, DMV
DABVP, Cert. IVUSS

**IMAGING
PERFORMED BY**

Dr. Gabriel

HOSPITAL NAME

Central Jersey AH

REFERRING VET

Dr. Gabriel

INVOICE

99515

DATE

4/25/22