



PATIENT

Lacey Chumbley

SPECIES

Canine

BREED

Schnauzer

SEX

Spayed Female

AGE

10 years

WEIGHT

19 lbs

INTERPRETED BY

Eric Lindquist, DMV
DABVP, Cert. IVUSS

IMAGING PERFORMED BY

Dr. Anderson

HOSPITAL NAME

Elizabeth AH

REFERRING VET

Dr. Anderson

INVOICE

99517

DATE

4/25/22

PRESENTING CLINICAL SIGNS

Emergency spay for pyometra one year ago. Has put on a lot of weight since then. Firm abdominal distention noticed over the last few days and she is hiding and resists going outside. She cries when picked up.

PE: Full soft abdomen, overweight, sclerosis of lenses, stage II dental disease, stable otherwise. UA: SG 1.048, pH 7.0 Trace protein, 50mg/dL Glucose, RBC's (cysto) Full panel pending.

ULTRASONOGRAPHIC EXAMINATION OF THE ABDOMEN

Urinary System

The **urinary bladder**, trigone, and pelvic urethra presented normal thicknesses and normal tone. The pelvic urethra was imaged 3.0 cm beyond the cystourethral junction. The ureters were not visible which is normal. No uroliths or sediment were visualized and anechoic urine was present. No evidence of inflammatory or neoplastic changes was noted. Ureteral papillae were normal.

The **kidneys** revealed normal size and structure, corticomedullary definition and ratio for this age. The cortices presented largely uniform texture with normal echogenic relationship to liver and spleen. Medullary structure differed distinctly from the cortex and no evidence of pelvic dilation was present. The capsules were acceptably uniform without significant irregularities. The left kidney measured 4.53 cm. The right kidney measured 5.0 cm.

Adrenal Glands

Both **adrenal glands** were visualized and recognized as having normal shape, size, position and echogenicity for this breed. The phrenic vasculature, glandular echogenicity and detail were unremarkable. Capsule, cortex, and medullary definition were normal for this age patient. The right adrenal gland measured 1.5 x 0.54 cm at the caudal pole and 0.45 cm at the cranial pole. The left adrenal gland measured 1.73 x 0.56 cm at the caudal pole and 0.52 cm at the cranial pole.

Spleen

The **spleen** was normal size and relatively normal contour with multifocal hyperechoic areas of mineralization. This is a benign change; however, can be related to Cushing's disease or other endocrinopathies.

Liver

The **liver** images from right and left intercostal as well as subcostal views revealed subjectively normal liver size, contour, and structure. Some age-related parenchymal remodeling was noted but likely not clinically significant at this time. Vascular and biliary tracts were of normal volume and no evidence of congestion was noted. The gallbladder presented some dependent debris with essentially normal contour. The cystic and common bile ducts were normal. No overt evidence of active inflammatory, infiltrative or regenerative pathology was noted but should be paired with current or past LE elevations regarding any clinical significance to this presentation. The hepatic lymph nodes were unremarkable.



PATIENT

Gastrointestinal

Lacey Chumbley

Examination of the **gastrointestinal tract** revealed a stomach and intestine free of stasis, of normal wall thickness, acceptable curvilinear mural detail, and peristaltic activity. Small and large intestine demonstrated normal luminal chyme and stool consistency respectively. No obstructive or overt infiltrative disease was noted. No associated abnormal lymphatic activity was noted.

SPECIES

Canine

BREED

Schnauzer

Pancreas

The base and limbs of the **pancreas** were observed to be largely isoechoic to surrounding omental fat. Pancreatic duct and capsular contour were acceptably normal and parenchyma respected normal curvilinear patterns. No overt evidence of active inflammatory or neoplastic disease was noted.

SEX

Spayed Female

ULTRASONOGRAPHIC FINDINGS

Structurally unremarkable abdomen.

AGE

10 years

INTERPRETATION OF THE FINDINGS & FURTHER RECOMMENDATIONS

WEIGHT

19 lbs

The changes are largely expected for this age and breed. There was no evidence of visceral disease. Maldigestion panel, three view chest radiographs and full CNS examination is recommended to examine for occult disease that could be responsible for the weight loss. Evaluation for competitive eating environments should also be considered.

INTERPRETED BY

Eric Lindquist, DMV
DABVP, Cert. IVUSS

IMAGING PERFORMED BY

Dr. Anderson

HOSPITAL NAME

Elizabeth AH

REFERRING VET

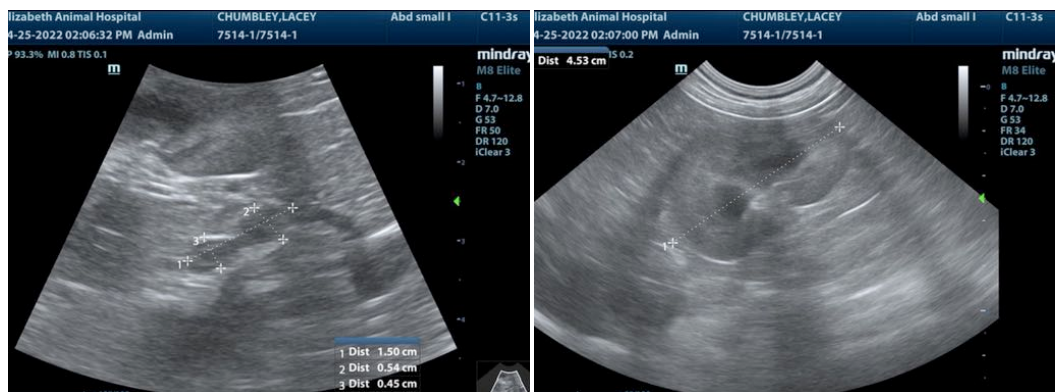
Dr. Anderson

INVOICE

99517

DATE

4/25/22





PATIENT

Lacey Chumbley

SPECIES

Canine

BREED

Schnauzer

SEX

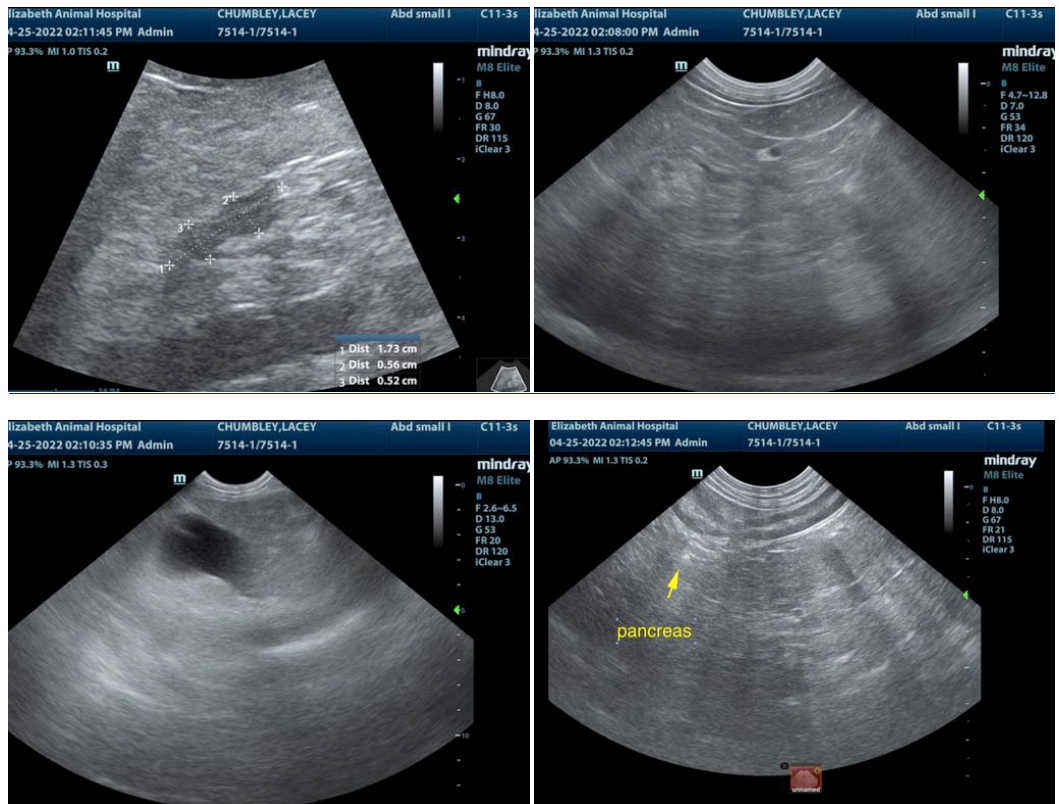
Spayed Female

AGE

10 years

WEIGHT

19 lbs



INTERPRETED BY

Eric Lindquist, DMV
DABVP, Cert. IVUSS

IMAGING PERFORMED BY

Dr. Anderson

HOSPITAL NAME

Elizabeth AH

REFERRING VET

Dr. Anderson

INVOICE

99517

DATE

4/25/22

The information and recommendations provided are based on the images presented by the referring veterinarian/sonographer. No evaluation can be communicated regarding pathology that was not visible in the image/video clips provided.

Thank you for this referral. If the clinical or image interpretation does not parallel your findings or if I can be of any further assistance please contact me.

Eric Lindquist, DMV, DABVP, Cert. IVUSS, CEO of SonoPath.com
info@SonoPath.com