

**DATE**

4/25/22

PRESENTING CLINICAL SIGNS

Seen here early april for straining to urinate/concern for obstruction; history of bladder stones and having bladder surgery xrays- no obvious stones- but opacity noted near the entry of the bladder bloodwork- normal had ear infection started to strain to urine- was surrendered to Pitties/Purrs owner did not bring in medications owner did give 600mg of gabapentin prior to coming
Current Medications: Carprofen, Enrofloxacin, Gabapentin, Trazodone.

PATIENT

Kasino Pitties and
Purrs Sullivan

Lab Results: See attached.

Radiographs: Mineralized opacity near the opening of the urethra- can see on previous films- did not see in bladder after u-cath had been

SPECIES

Canine

passed; no obvious stones in the urethra

Date of Previous IntraPet Ultrasound: No previous.

Sedation: IV Ace and Torb.

Stat Report: Not requested.

BREED

Pitbull

Imaging Performed By: Rachel Brillhart, RDMS.

SEX

Neutered male

ULTRASONOGRAPHIC EXAMINATION OF THE ABDOMEN**Urinary System**

The **urinary bladder** revealed minor micropolypoid changes. A minor amount of bladder debris was noted, yet no residual calculi. The Foley catheter is placed in proper position.

AGE

4/23/13

The residual prostate measured 2.04 cm, yet uniform.

WEIGHT

110.1 lbs

The **kidneys** revealed normal size and structure, corticomedullary definition and ratio for this age. The cortices presented largely uniform texture with normal echogenic relationship to liver and spleen. Medullary structure differed distinctly from the cortex and no evidence of pelvic dilation was present. The capsules were acceptably uniform without significant irregularities. Slight pinpoint mineralization was noted. The left kidney measured 8.24 cm. The right kidney measured 8.21 cm.

INTERPRETED BY

Eric Lindquist, DMV
DABVP, Cert. IVUSS

Adrenal Glands

Both **adrenal glands** were visualized and recognized as having normal shape, size, position and echogenicity for this breed. The phrenic vasculature, glandular echogenicity and detail were unremarkable. Capsule, cortex, and medullary definition were normal for this age patient. The right adrenal gland measured 3.21 x 0.79 cm at the cranial pole and 0.75 cm at the caudal pole. Slight pinpoint mineralization was noted in the cranial pole of the left adrenal gland.

HOSPITAL NAME

Animal Emergency
Hospital

Spleen

The **spleen** was largely smooth with subtle heterogeneous parenchymal changes while maintaining normal echogenic relationship to the liver and kidney. The spleen was folded upon itself caudally. These changes are consistent with normal age-related alteration. The capsule was smooth without noticeable impingement from within the spleen or from pathology in the adjacent abdomen. The splenic vasculature demonstrated normal volume without signs of congestion or significant contraction. No evidence of active acute or chronic inflammatory, neoplastic, or infarctual changes was noted.

REFERRING VET

Dr. Willer

INVOICE

99500

Liver

The **liver** images submitted revealed subjectively normal liver size, contour, and structure. Parenchymal echogenicity was naturally coarse and hypoechoic to the spleen. Vascular and biliary tracts were of normal volume with no evidence of congestion. The gallbladder presented acceptably thin walls with primarily anechoic content. The cystic and common bile ducts were normal. No pathological hepatic lymphadenopathy

was evident. No overt structural evidence of inflammatory, infiltrative or regenerative pathology was evident.

Gastrointestinal

Examination of the **gastrointestinal tract** revealed a stomach and intestine free of stasis, of normal wall thickness, acceptable curvilinear mural detail, and peristaltic activity. Small and large intestine demonstrated normal luminal chyme and stool consistency respectively. No obstructive or overt infiltrative disease was noted. No associated abnormal lymphatic activity was noted.

Pancreas

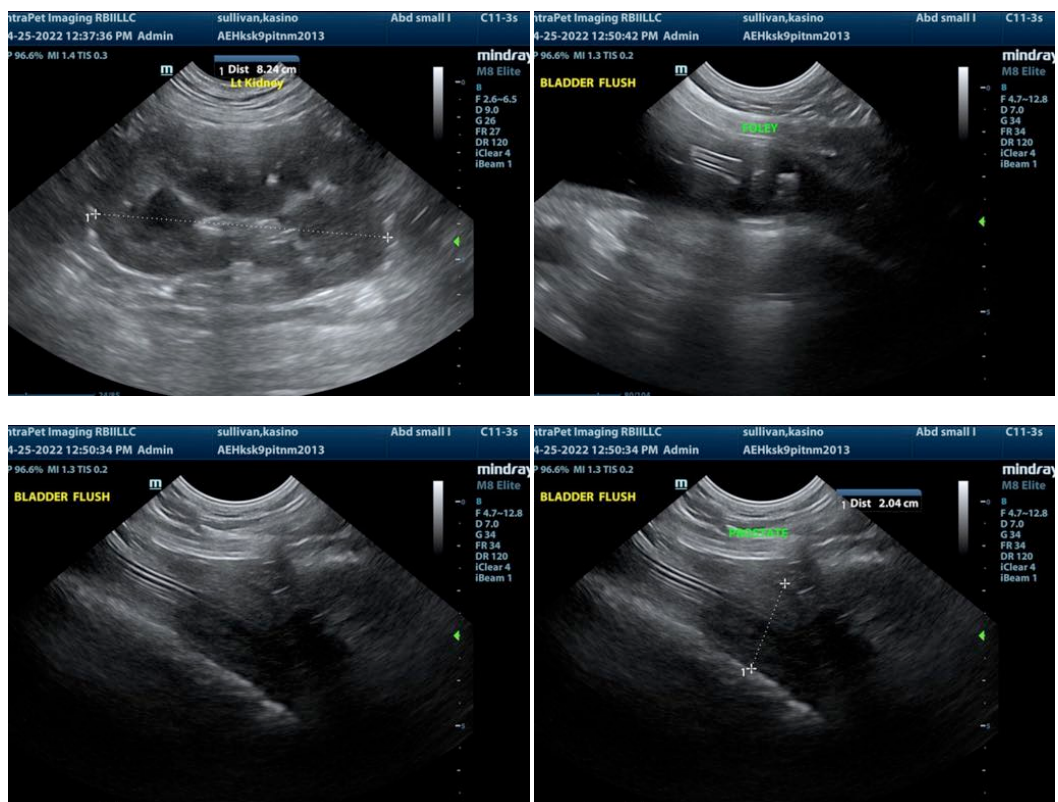
The base and limbs of the **pancreas** were observed to be largely isoechoic to surrounding omental fat. Pancreatic duct and capsular contour were acceptably normal and parenchyma respected normal curvilinear patterns. No overt evidence of active inflammatory or neoplastic disease was noted.

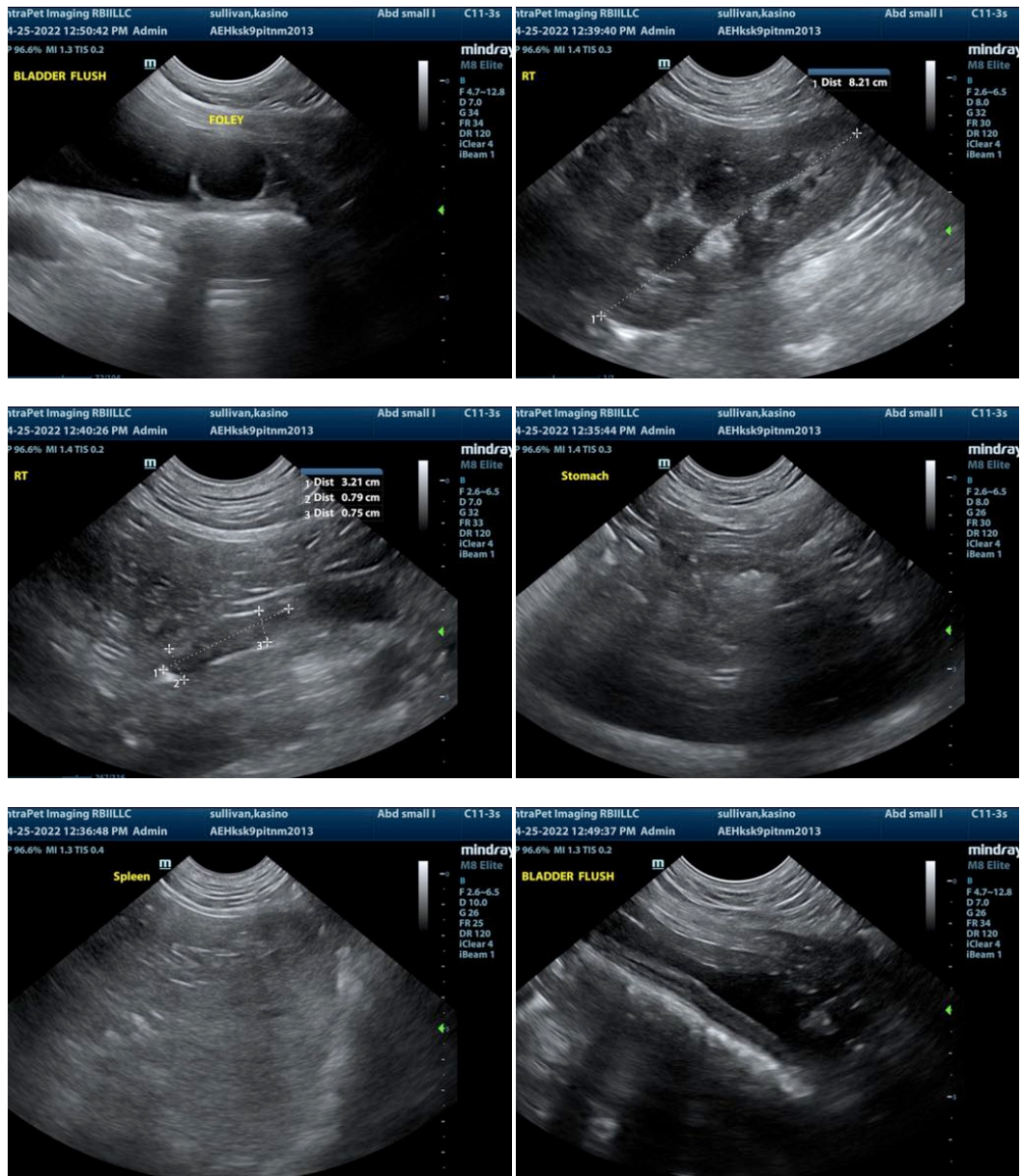
ULTRASONOGRAPHIC FINDINGS

Largely age related abdominal changes with slight renal mineralization. Bladder debris, yet no residual calculi.

INTERPRETATION OF THE FINDINGS & FURTHER RECOMMENDATIONS

There was no obstructive disease noted at the time of the sonogram in the lower urinary tract. The patient may be passing small calculi periodically.





The information and recommendations provided are based on the images presented by the referring veterinarian. No evaluation can be communicated regarding pathology that was not visible in the image/video clips provided.

Thank you for this referral. If the clinical or image interpretation does not parallel your findings or if I can be of any further assistance please contact me.

Eric Lindquist, DMV, DABVP, Cert. IVUSS, CEO of SonoPath.com
 Eric.Lindquist@SonoPath.com