



## PATIENT

Tara Dikengil

## SPECIES

Feline

## BREED

DSH

## SEX

Spayed Female

## AGE

16

## WEIGHT

5.7

## INTERPRETED BY

Eric Lindquist, DMV,  
DABVP(CFM), Cert.  
IVUSS

## IMAGING PERFORMED BY

Jenn

## HOSPITAL NAME

Rockaway Animal  
Hospital

## REFERRING VET

Dr. Harrs

## INVOICE

15436

## DATE

04/24/26

## PRESENTING CLINICAL SIGNS

Weight loss , chronic soft stool, intestinal thickening on rads , drooling

Abnormal PE/Chem/CBC/UA Results: WBC 21.49 TP 9.6 Glob 6.7

## ULTRASONOGRAPHIC EXAMINATION OF THE HEART & ABDOMEN

| FELINE CARDIAC PARAMETERS | BODY WEIGHT    | HR (BPM)                  | IVSd (cm)            | LVIDd (cm) | LVWd (cm)      | FS (%)         | EF (%)    |
|---------------------------|----------------|---------------------------|----------------------|------------|----------------|----------------|-----------|
| NORMAL PARAMETER          | -----          | 150-240                   | 0.3-0.6              | 1.0-2.1    | 0.25-0.6       | 35-67          | 80-100    |
| PATIENT                   | 5.7            | 200                       | 0.5                  | 1.4        | 0.45           | 50             | --        |
| FELINE CARDIAC PARAMETERS | LA/AO (M-mode) | LA/AO HEART BASE (Sisson) | LAD LA MAX 4 Chamber |            | LVOT VEL (m/s) | RVOT VEL (m/s) | IVRT (m/) |
| NORMAL PARAMETER          | <1.5           | 1.6                       | 0.7-1.7              |            | <1.6           | <1.3           | 40-60     |
| PATIENT                   | 1.0            | 1.1                       | 1.5                  |            | --             | 1.02           | NM        |

Adapted from June Boon, Veterinary Echocardiography, 1998

Sisson D et al. JVIM 1991; 5: 232, Jacobs et al. Am J Vet Res 1985; 46:1705

E-wave velocity: 0.9

## Cardiac Presentation

The echocardiogram in this patient demonstrated normal **left atrial** size based on 3 separate LA measurements. The cranial and caudal **mitral** valve leaflets presented normal linear structure and kinetics. The **left ventricle** presented normal thicknesses with linear contour and was not dilated nor restricted. The **myocardium** presented normal echogenicity without subjective evidence of significant fibrotic or ischemic disease. **Contractility** of the ventricular walls was adequate and in normal range for this patient evidenced by the fractional shortening measurement and subjective evaluation of the different regions and angles of the myocardium. The **left ventricular outflow** tract demonstrated normal laminar flow and subjective structural integrity. The **right atrium** and auricle revealed normal size, structure and content. No evidence of masses was noted or chamber overload. **Tricuspid** valvular assessment demonstrated adequate linear morphology and kinetics. The **right ventricle** was of normal size (1/3 diameter of LV), chordae structure, myocardial echogenicity and thickness. **Pulmonic** tract assessment revealed normal valve structure, laminar flow, and diameter (approx.1:1 pa/ao ratio). No visible **pericardial** or free pleura fluid was noted or extra cardiac pathology in the visible planes. The cranial **mediastinum and pericardial regions** were free of masses in the visible window.

## Urinary System

The **urinary bladder**, trigone, and pelvic urethra presented normal thicknesses and normal tone. The ureters were not visible which is normal. No uroliths or sediment were visualized, and anechoic urine was present. No evidence of inflammatory or neoplastic changes were noted. Ureteral papillae were normal.



## PATIENT

Tara Dikengil

## SPECIES

Feline

## BREED

DSH

## SEX

Spayed Female

## AGE

16

## WEIGHT

5.7

## INTERPRETED BY

Eric Lindquist, DMV,  
DABVP(CFM), Cert.  
IVUSS

## IMAGING PERFORMED BY

Jenn

## HOSPITAL NAME

Rockaway Animal  
Hospital

## REFERRING VET

Dr. Harrs

## INVOICE

15436

## DATE

04/24/26

The **kidneys** revealed largely normal size and structure, corticomedullary definition and ratio (cortex 1/3 of medulla) were essentially maintained with some moderate age-related loss of curvilinear patterns regarding the capsule and C/M junction. The cortices presented largely uniform texture with some increased echogenicity expected for his age patient. Medullary structure differed distinctly from that of the cortex and no evidence of pelvic dilation was present. The left kidney measured 4.78 cm in length. The right kidney measured 4.5 cm in length.

### *Adrenal Glands*

Both **adrenal glands** were not visualized.

### *Spleen*

The **spleen** presented a smooth homogeneous parenchyma hyperechoic to liver and renal cortical parenchyma. The capsule was smooth without noticeable expansion or deviation from within the spleen or adjacent pathology. The splenic vasculature demonstrated normal volume without signs of congestion or thrombosis. No sonographic evidence of acute or chronic inflammatory, neoplastic, or infarctual changes were noted.

### *Liver*

The **liver** presented mildly enlarged with hypoechoic nodular area measuring 1.0 cm in the left lateral lobe with diffusely hyperechoic parenchyma. The gallbladder and common bile duct were unremarkable.

### *Gastrointestinal*

The **gastrointestinal tract** revealed mild variable thickening and echogenic submucosal changes most consistent with low grade end result of chronic GI disease such as IBD and may be related to malassimilation of nutrients if any weight loss is present. No obvious neoplastic patterns were noted and luminal content as unremarkable.

### *Pancreas*

The base and limbs of the **pancreas** were observed to be largely isoechoic to surrounding omental fat. Some mild parenchymal remodeling, however, with mild deviation from curvilinear normalcy was observed. Pancreatic duct and capsular irregularities were present consistent with age related changes. If pain upon imaging (+ Murphy sign) was present or if the patient is focally painful in subxiphoid palpation then low-grade smoldering chronic pancreatitis should be suspected.

## ULTRASONOGRAPHIC FINDINGS

- Geriatric abdomen with chronic intestinal thickening.
- Chronic pancreatic changes.
- Age-related hepatic changes with nodule.

## INTERPRETATION OF THE FINDINGS & FURTHER RECOMMENDATIONS

FNA of the liver is indicated. Maldigestion panel, three view chest radiographs and full CNS examination is recommended to examine for occult disease that could be responsible for the weight loss. Evaluation for competitive eating environments should also be considered.



## PATIENT

Tara Dikengil

## SPECIES

Feline

## BREED

DSH

## SEX

Spayed Female

## AGE

16

## WEIGHT

5.7

## INTERPRETED BY

Eric Lindquist, DMV,  
DABVP(CFM), Cert.  
IVUS

## IMAGING PERFORMED BY

Jenn

## HOSPITAL NAME

Rockaway Animal  
Hospital

## REFERRING VET

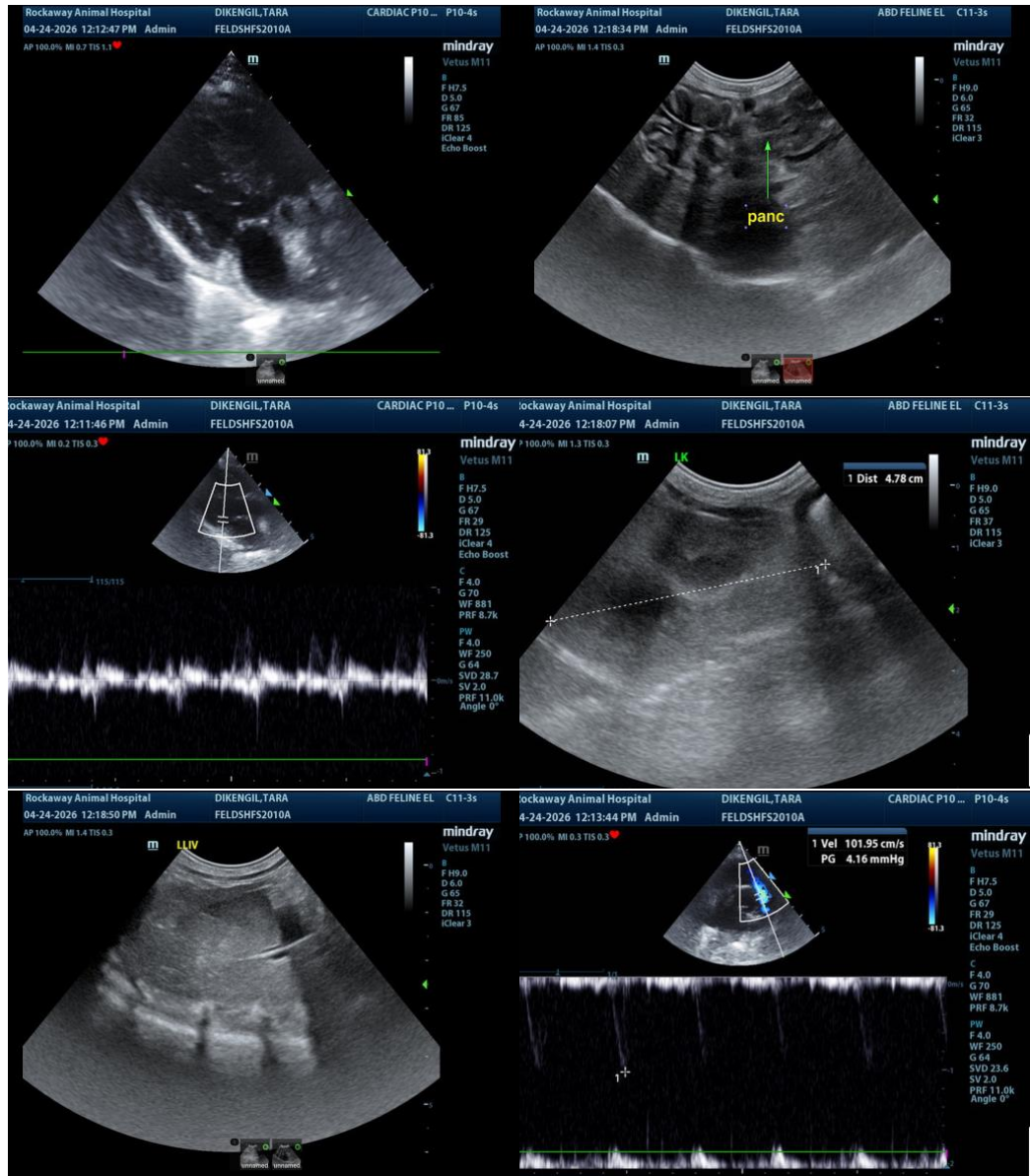
Dr. Harrs

## INVOICE

15436

## DATE

04/24/26





**PATIENT**

Tara Dikengil

**SPECIES**

Feline

**BREED**

DSH

**SEX**

Spayed Female

**AGE**

16

**WEIGHT**

5.7

**INTERPRETED BY**

Eric Lindquist, DMV,  
DABVP(CFM), Cert.  
IUUSS

**IMAGING PERFORMED BY**

Jenn

**HOSPITAL NAME**

Rockaway Animal  
Hospital

**REFERRING VET**

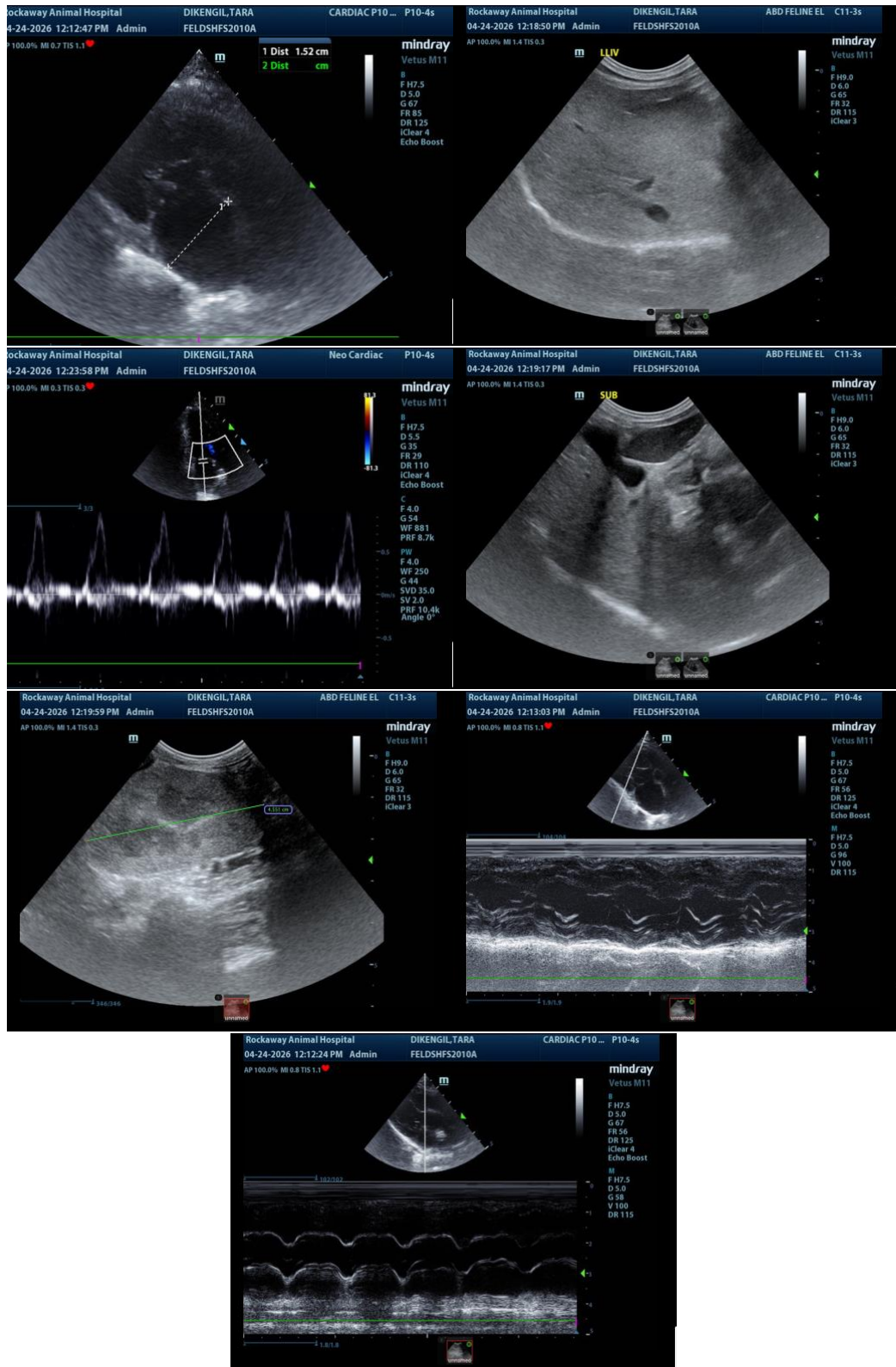
Dr. Harrs

**INVOICE**

15436

**DATE**

04/24/26





## PATIENT

Tara Dikengil

## SPECIES

Feline

## BREED

DSH

## SEX

Spayed Female

## AGE

16

## WEIGHT

5.7

## INTERPRETED BY

Eric Lindquist, DMV,  
DABVP(CFM), Cert.  
IVUSS

## IMAGING PERFORMED BY

Jenn

## HOSPITAL NAME

Rockaway Animal  
Hospital

## REFERRING VET

Dr. Harrs

## INVOICE

15436

## DATE

04/24/26

The information and recommendations provided are based on the images presented by the referring veterinarian/sonographer. No evaluation can be communicated regarding pathology that was not visible in the image/video clips provided.

Thank you for this referral. If the clinical or image interpretation does not parallel your findings or if I can be of any further assistance, please contact me.

**Eric Lindquist, DMV, DABVP(CFM), Cert. IVUSS,**

CEO, Owner, Founder -- SonoPath.com

[info@SonoPath.com](mailto:info@SonoPath.com)