



PATIENT

Mazikeen Mercado

SPECIES

Canine

BREED

Shih Tzu

SEX

Intact Female

AGE

5 years

WEIGHT

5.16 kg

INTERPRETED BY

Eric Lindquist, DMV
DABVP, Cert. IVUSS

IMAGING PERFORMED BY

Dr. Cory

HOSPITAL NAME

Brighton Veterinary
Clinic

REFERRING VET

Dr. Loewen

INVOICE

74826

DATE

4/24/26

PRESENTING CLINICAL SIGNS

History: Has not had visible heat cycle since last litter 2 years ago. Owner is hoping to breed her again- looking to find out if reproductive organs have any obvious abnormalities that would guide further testing. No bloodwork has been done. Owner declined sedation for the procedure.

ULTRASONOGRAPHIC EXAMINATION OF THE ABDOMEN

Urinary System

The **urinary bladder**, trigone, and pelvic urethra presented normal thicknesses and normal tone. The ureters were not visible which is normal. No uroliths or sediment were visualized and anechoic urine was present. No evidence of inflammatory or neoplastic changes was noted. Ureteral papillae were normal.

The **kidneys** revealed normal size and structure, corticomedullary definition and ratio for this age. The cortices presented largely uniform texture with normal echogenic relationship to liver and spleen. Medullary structure differed distinctly from the cortex and no evidence of pelvic dilation was present. The capsules were acceptably uniform without significant irregularities. The right kidney measured 3.47 cm with a slight, hyperechoic medullary rim sign noted. The left kidney measured 3.4 cm.

The **uterus** was uniform and empty measuring 0.57 cm. The ovaries were uniform.

Adrenal Glands

Both **adrenal glands** were visualized and recognized as having normal shape, size, position and echogenicity for this breed. The phrenic vasculature, glandular echogenicity and detail were unremarkable. Capsule, cortex, and medullary definition were normal for this age patient. The left adrenal gland measured 0.41 cm at the cranial pole and 0.36 cm at the caudal pole. The right adrenal gland measured 0.46 cm at the cranial pole and 0.42 cm at the caudal pole.

Spleen

The **spleen** presented a smooth homogeneous parenchyma hyperechoic to liver and renal cortical parenchyma. The capsule was smooth without noticeable expansion or deviation from within the spleen or adjacent pathology. The splenic vasculature demonstrated normal volume without signs of congestion or thrombosis. No sonographic evidence of acute or chronic inflammatory, neoplastic, or infarctual changes was noted.

Liver

The **liver** images submitted revealed subjectively normal liver size, contour, and structure. Parenchymal echogenicity was naturally coarse and hypoechoic to the spleen. Vascular and biliary tracts were of normal volume with no evidence of congestion. The gallbladder presented acceptably thin walls with



PATIENT

Mazikeen Mercado

SPECIES

Canine

BREED

Shih Tzu

SEX

Intact Female

AGE

5 years

WEIGHT

5.16 kg

INTERPRETED BY

Eric Lindquist, DMV
DABVP, Cert. IVUSS

IMAGING PERFORMED BY

Dr. Cory

HOSPITAL NAME

Brighton Veterinary
Clinic

REFERRING VET

Dr. Loewen

INVOICE

74826

DATE

4/24/26

primarily anechoic content. The cystic and common bile ducts were normal. No pathological hepatic lymphadenopathy was evident. No overt structural evidence of inflammatory, infiltrative or regenerative pathology was evident.

Gastrointestinal

There was some residual chyme and gas was noted in the **stomach**, yet not pathological. This is consistent with post prandial presentation. Transit of chyme into the small intestine was normal. Curvilinear patterns were maintained throughout the GI tract. No evidence of pathology. Small and large intestine demonstrated normal luminal chyme and stool consistency respectively. No obstructive or overt infiltrative disease was noted. No associated abnormal lymphatic activity was noted.

Pancreas

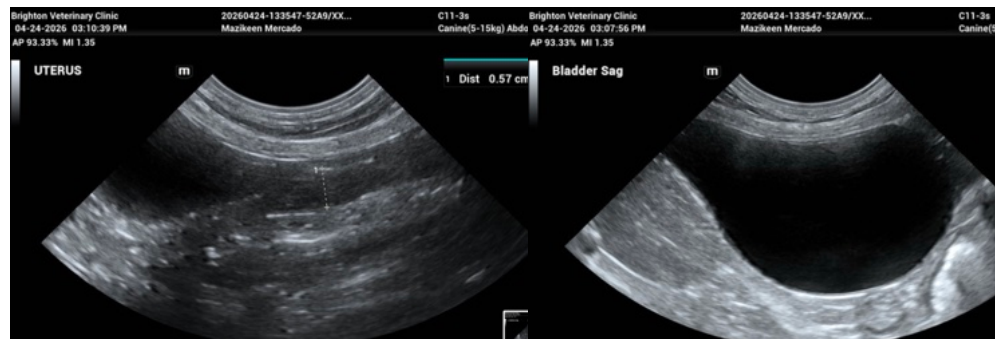
The base and limbs of the **pancreas** were observed to be largely isoechoic to surrounding omental fat. Pancreatic duct and capsular contour were acceptably normal and parenchyma respected normal curvilinear patterns. No overt evidence of active inflammatory or neoplastic disease was noted.

ULTRASONOGRAPHIC FINDINGS

Structurally unremarkable abdomen and reproductive tract.
Post prandial presentation.

INTERPRETATION OF THE FINDINGS & FURTHER RECOMMENDATIONS

There was no evidence of predisposing pathology influencing the lack of reproductive viability.





PATIENT

Mazikeen Mercado

SPECIES

Canine

BREED

Shih Tzu

SEX

Intact Female

AGE

5 years

WEIGHT

5.16 kg

INTERPRETED BY

Eric Lindquist, DMV
DABVP, Cert. IVUSS

IMAGING PERFORMED BY

Dr. Cory

HOSPITAL NAME

Brighton Veterinary
Clinic

REFERRING VET

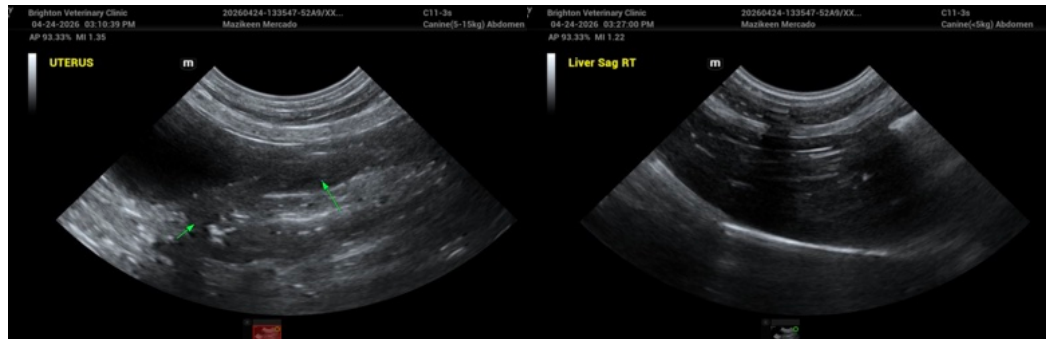
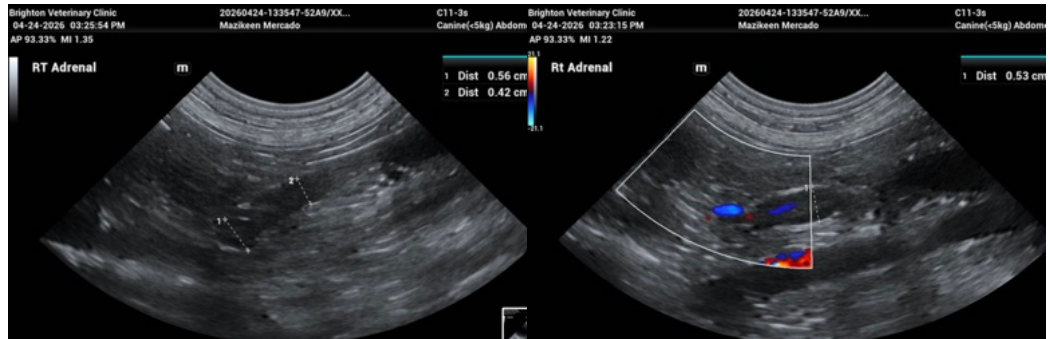
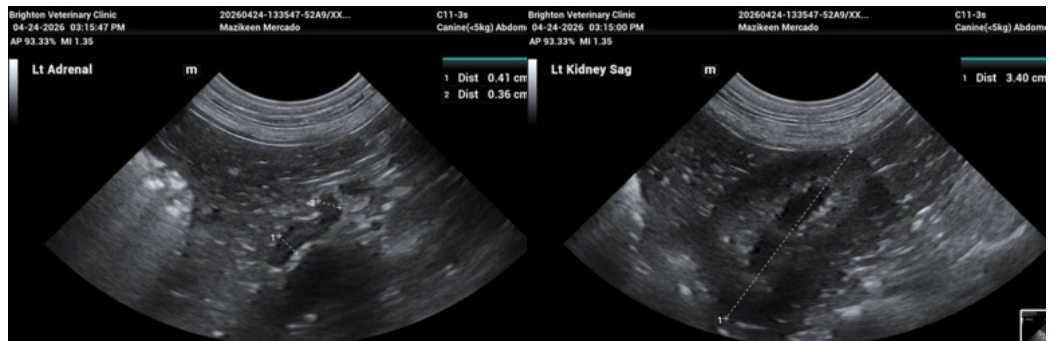
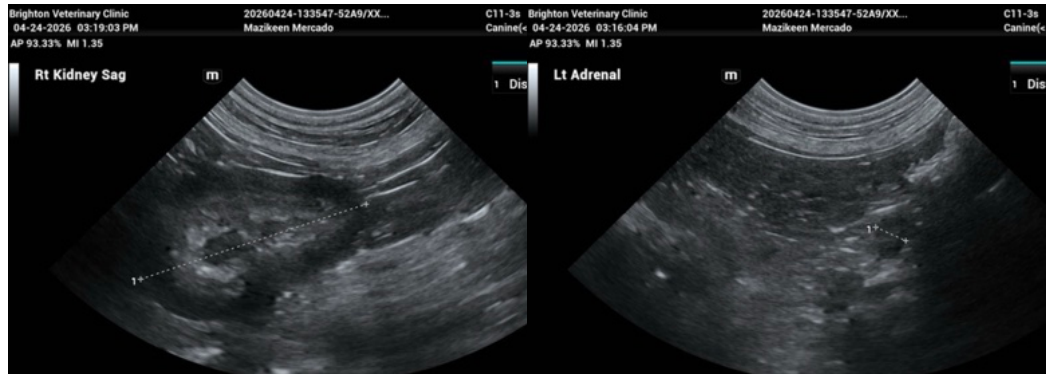
Dr. Loewen

INVOICE

74826

DATE

4/24/26





PATIENT

Mazikeen Mercado

SPECIES

Canine

BREED

Shih Tzu

SEX

Intact Female

AGE

5 years

WEIGHT

5.16 kg

INTERPRETED BY

Eric Lindquist, DMV
DABVP, Cert. IVUSS

IMAGING PERFORMED BY

Dr. Cory

HOSPITAL NAME

Brighton Veterinary
Clinic

REFERRING VET

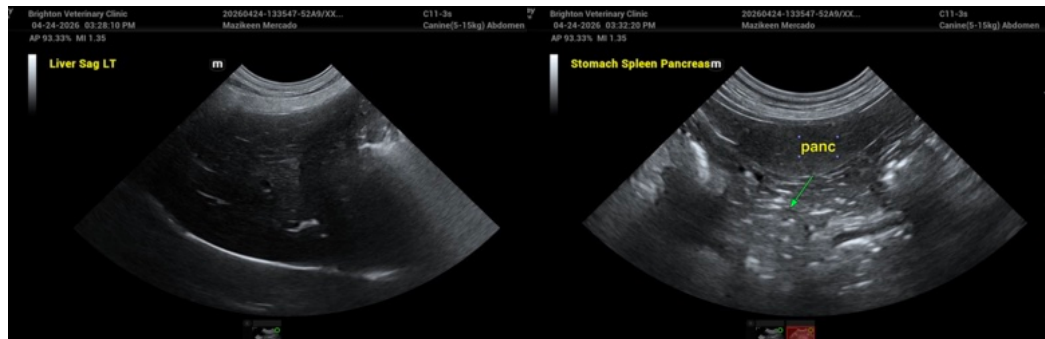
Dr. Loewen

INVOICE

74826

DATE

4/24/26



The information and recommendations provided are based on the images presented by the referring veterinarian/sonographer. No evaluation can be communicated regarding pathology that was not visible in the image/video clips provided.

Thank you for this referral. If the clinical or image interpretation does not parallel your findings or if I can be of any further assistance please contact me.

Eric Lindquist, DMV, DABVP (CFM), Cert. IVUSS, CEO of SonoPath.com

info@SonoPath.com