



PATIENT

Frankie Scozzari

SPECIES

Canine

BREED

Mixed

SEX

Neutered Male

AGE

13 Years

WEIGHT

9.6 Pounds

INTERPRETED BY

Eric Lindquist, DMV,
 DABVP (Canine &
 Feline), Cert. IVUSS

IMAGING PERFORMED BY

Vincent Ravancho,
 CVT

HOSPITAL NAME

Sova AH

REFERRING VET

Dr. Sova

INVOICE

36760

DATE

4/24/26

PRESENTING CLINICAL SIGNS

History: Recheck echocardiogram. Mitral and Tricuspid insufficiency.

Current medications - Insulin, Vetmedin, Thyrotabs, Spironolactone, Enalapril, gabapentin.

Abnormal PE/Chem/CBC/UA Results: AlkP 587, Magnesium 1.4, CI 97, PSL 328, Trigyl 637

ULTRASONOGRAPHIC EXAMINATION OF THE HEART

CANINE CARDIAC PARAMETERS	MR VMAX (m/s)	TR VMAX (m/s)	LA/AO (M-Mode)	LA/AO (Heart Base; Swe)	FS (%)	EF (%)	EPSS (cm)
NORMAL PARAMETER	4.5-5.5	<2.7	1.3	Up to 1.6	28-40	40-100	<0.6
PATIENT	5.03	2.9	1.8	1.44	60	90	0.1
CANINE CARDIAC PARAMETERS	HR (BPM)	AV VMAX (m/s)	PV MAX (m/s)	BODY WEIGHT (kg)	LAD LA MAX 4 Chamber	LVIDd Avg; 2D and m-mode short axis (cm)	LVIDs Avg; 2D and m-mode short axis (cm)
NORMAL PARAMETER	50-100	0.7-1.7	0.7-1.6				
PATIENT	142	1.50	.83	9.6 lbs	3.4	3.22	--

Cardiac Presentation

The cardiac presentation presented minor, essentially normal, to slightly residual, enlargement of the left atrium with prolapsed anterior mitral valve leaflet. Left ventricular volume appeared normal. Severe mitral sufficiency was noted with complete filling of the left atrium. Tricuspid insufficiency was noted. The hepatic veins were not dilated. No pericardial or pleural effusion was noted. Aortic insufficiency was noted; however, pulmonic and aortic outflow velocities were normal.

ULTRASONOGRAPHIC FINDINGS

- Fairly compensated valvular disease on current protocol

INTERPRETATION OF THE FINDINGS & FURTHER RECOMMENDATIONS

Monitoring BUN, creatinine, blood pressure, respiratory rate, and chest radiographs are all recommended. Recommend continuation of current protocol. Recheck echo is recommended in 6 months.



PATIENT

Frankie Scozzari

SPECIES

Canine

BREED

Mixed

SEX

Neutered Male

AGE

13 Years

WEIGHT

9.6 Pounds

INTERPRETED BY

Eric Lindquist, DMV,
 DABVP (Canine &
 Feline), Cert. IVUSS

**IMAGING
 PERFORMED BY**

Vincent Ravancho,
 CVT

HOSPITAL NAME

Sova AH

REFERRING VET

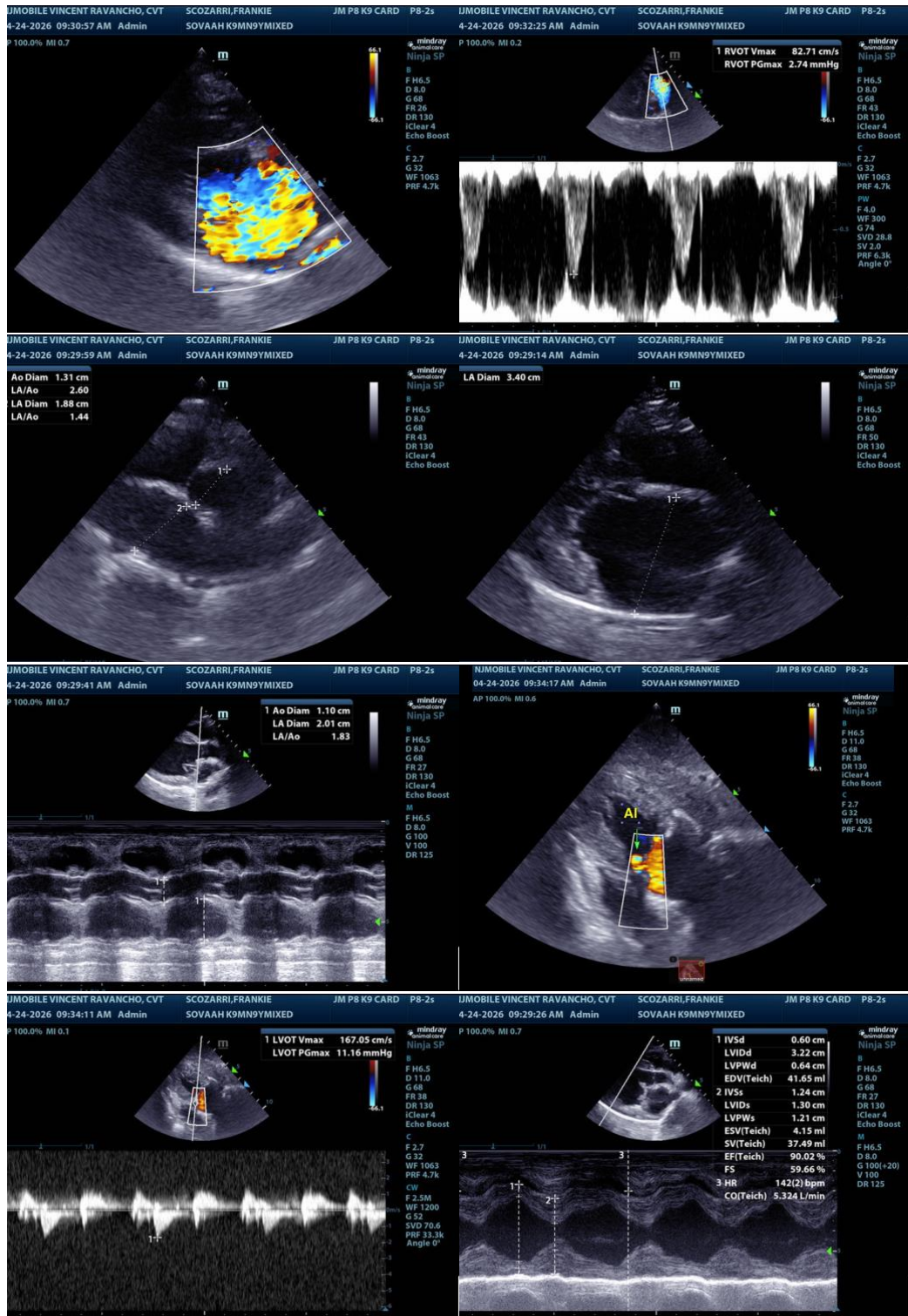
Dr. Sova

INVOICE

36760

DATE

4/24/26





PATIENT

Frankie Scozzari

SPECIES

Canine

BREED

Mixed

SEX

Neutered Male

AGE

13 Years

WEIGHT

9.6 Pounds

INTERPRETED BY

Eric Lindquist, DMV,
 DABVP (Canine &
 Feline), Cert. IVUSS

IMAGING PERFORMED BY

Vincent Ravancho,
 CVT

HOSPITAL NAME

Sova AH

REFERRING VET

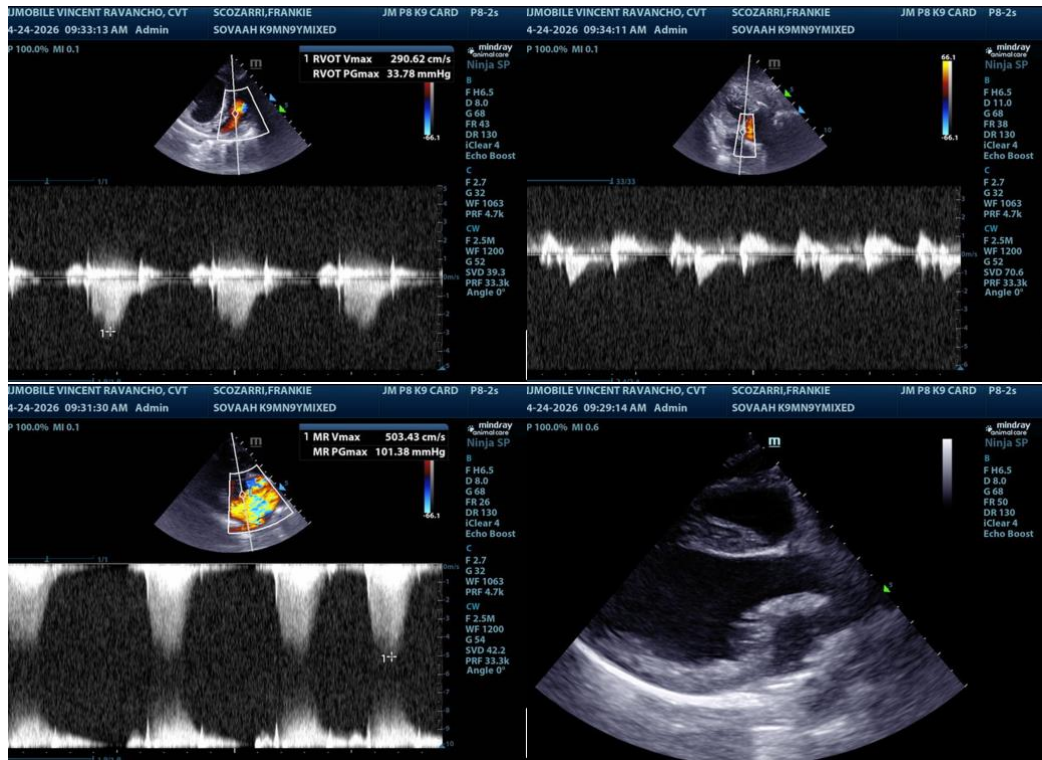
Dr. Sova

INVOICE

36760

DATE

4/24/26



The information and recommendations provided are based on the images presented by the referring veterinarian/sonographer. No evaluation can be communicated regarding pathology that was not visible in the image/video clips provided.

Thank you for this referral. If the clinical or image interpretation does not parallel your findings or if I can be of any further assistance please contact me.

Eric Lindquist, DMV, DABVP(CFM), Cert. IVUSS,
 CEO, Owner, Founder -- SonoPath.com
info@SonoPath.com