



## PATIENT

Boy Cat Rem

## SPECIES

Feline

## BREED

DSH

## SEX

Neutered Male

## AGE

13 Years 5 Months

## WEIGHT

12 Pounds

## INTERPRETED BY

Eric Lindquist, DMV,  
DABVP (Canine &  
Feline), Cert. IVUSS

## IMAGING PERFORMED BY

Heather

## HOSPITAL NAME

ACC Flanders

## REFERRING VET

Dr. Hallihan

## INVOICE

36768

## DATE

4/24/26

## PRESENTING CLINICAL SIGNS

History: Pre Dental work up due to elevated ProBNP, 3/20/26: Healthy senior patient with controlled hyperthyroidism presents for brief exam of teeth and heart for dental procedure. Medications: Trazodone 50mg - 1/2 tab po 2 hours prior to scan, Gabapentin 200mg po 2 hours prior to scan, Felinorm oral - 2.5mg po bid

Abnormal PE/Chem/CBC/UA Results: 3/31/26: ProBNP 121 Neutrophils 2,584 ALP 9 BP = 130

## ULTRASONOGRAPHIC EXAMINATION OF THE HEART

FELINE CARDIAC PARAMETERS	BODY WEIGHT (lbs)	HR (BPM)	IVSd (cm)	LVIDd (cm)	LVWd (cm)	FS (%)	EF (%)
<b>NORMAL PARAMETER</b>	-----	150-240	0.3-0.6	1.0-2.1	0.25-0.6	35-67	80-100
<b>PATIENT</b>	12	200	0.44	1.3	0.5	--	--
FELINE CARDIAC PARAMETERS	LA/AO (M-mode)	LA/AO HEART BASE (Sisson)	LAD LA MAX 4 Chamber		LVOT VEL. (m/s)	RVOT VEL. (m/s)	IVRT (m/)
<b>NORMAL PARAMETER</b>	<1.5	1.6	0.7-1.7		<1.6	<1.3	40-60
<b>PATIENT</b>	1.1	1.3	1.3		1.10	1.60	NM
Adapted from June Boon, Veterinary Echocardiography, 1998 Sisson D et al. JVIM 1991; 5: 232, Jacobs et al. Am J Vet Res 1985; 46:1705							

EPSS: 0.1

## Cardiac Presentation

The echocardiogram in this patient demonstrated normal **left atrial** size based on 3 separate LA measurements. Trivial mitral insufficiency was noted. The **left ventricle** presented normal thicknesses with linear contour and was not dilated nor restricted. Mild myocardial remodeling was noted in this patient. **Contractility** of the ventricular walls was adequate and in normal range for this patient evidenced by the fractional shortening measurement and subjective evaluation of the different regions and angles of the myocardium. The **left ventricular outflow** tract demonstrated normal laminar flow and subjective structural integrity. The **right atrium** and auricle revealed normal size, structure and content. No evidence of masses was noted or chamber overload. **Tricuspid** valvular assessment demonstrated adequate linear morphology and kinetics. The **right ventricle** was of normal size (1/3 diameter of LV), chordae structure, myocardial echogenicity and thickness. **Pulmonic** tract assessment revealed normal valve structure, laminar flow, and diameter (approx.1:1 pa/ao ratio). No visible **pericardial** or free pleura fluid was noted or extra cardiac pathology in the visible planes. The cranial **mediastinum and pericardial regions** were free of masses in the visible window.



## PATIENT

Boy Cat Rem

## SPECIES

Feline

## BREED

DSH

## SEX

Neutered Male

## AGE

13 Years 5 Months

## WEIGHT

12 Pounds

## INTERPRETED BY

Eric Lindquist, DMV,  
DABVP (Canine &  
Feline), Cert. IVUSS

## IMAGING PERFORMED BY

Heather

## HOSPITAL NAME

ACC Flanders

## REFERRING VET

Dr. Hallihan

## INVOICE

36768

## DATE

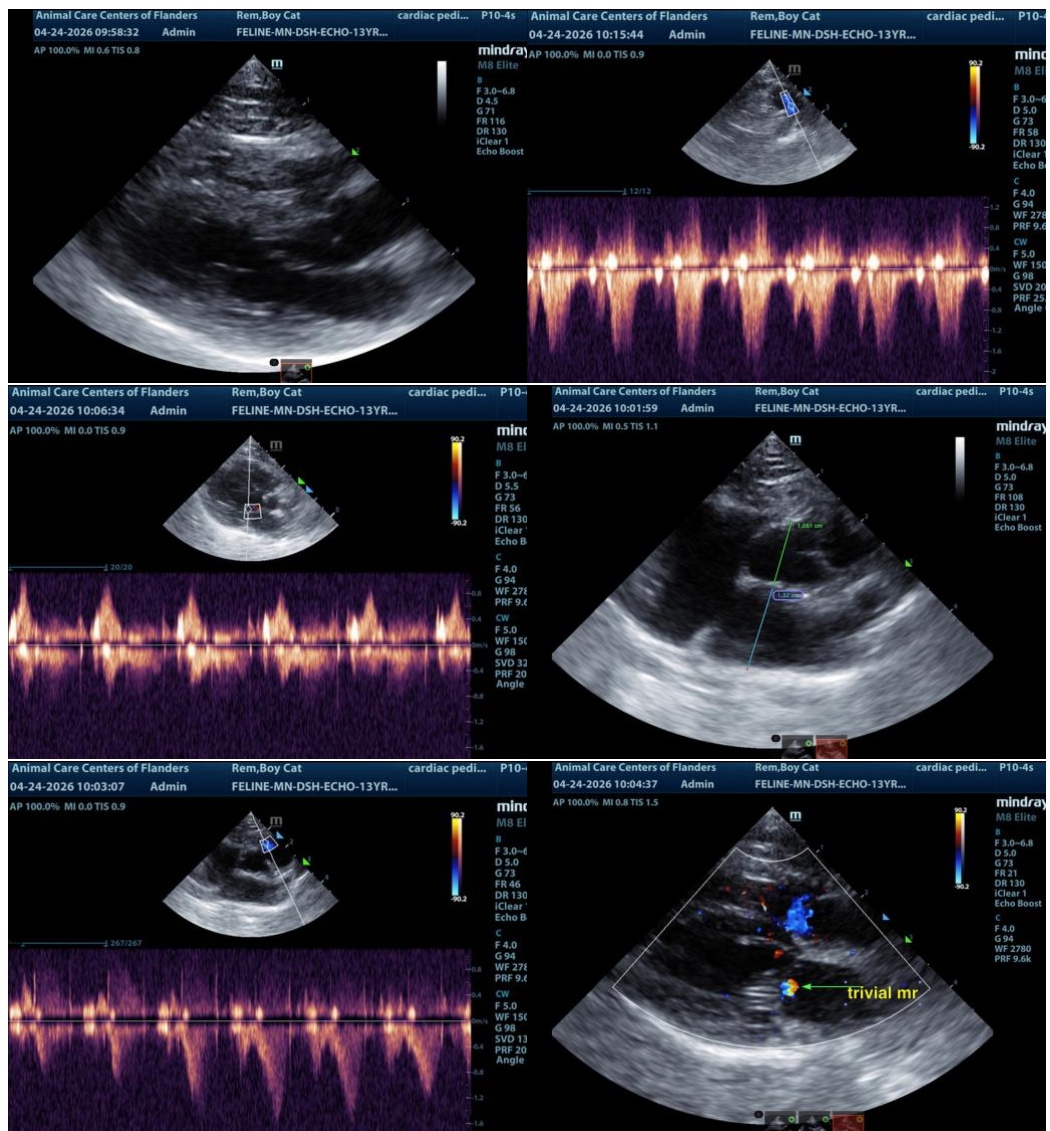
4/24/26

## ULTRASONOGRAPHIC FINDINGS

- Normal echocardiogram
- Trivial mitral insufficiency
- Mild myocardial remodeling

## INTERPRETATION OF THE FINDINGS & FURTHER RECOMMENDATIONS

No contraindication to anesthetic procedure.





**PATIENT**

Boy Cat Rem

**SPECIES**

Feline

**BREED**

DSH

**SEX**

Neutered Male

**AGE**

13 Years 5 Months

**WEIGHT**

12 Pounds

**INTERPRETED BY**

Eric Lindquist, DMV,  
DABVP (Canine &  
Feline), Cert. IVUSS

**IMAGING  
PERFORMED BY**

Heather

**HOSPITAL NAME**

ACC Flanders

**REFERRING VET**

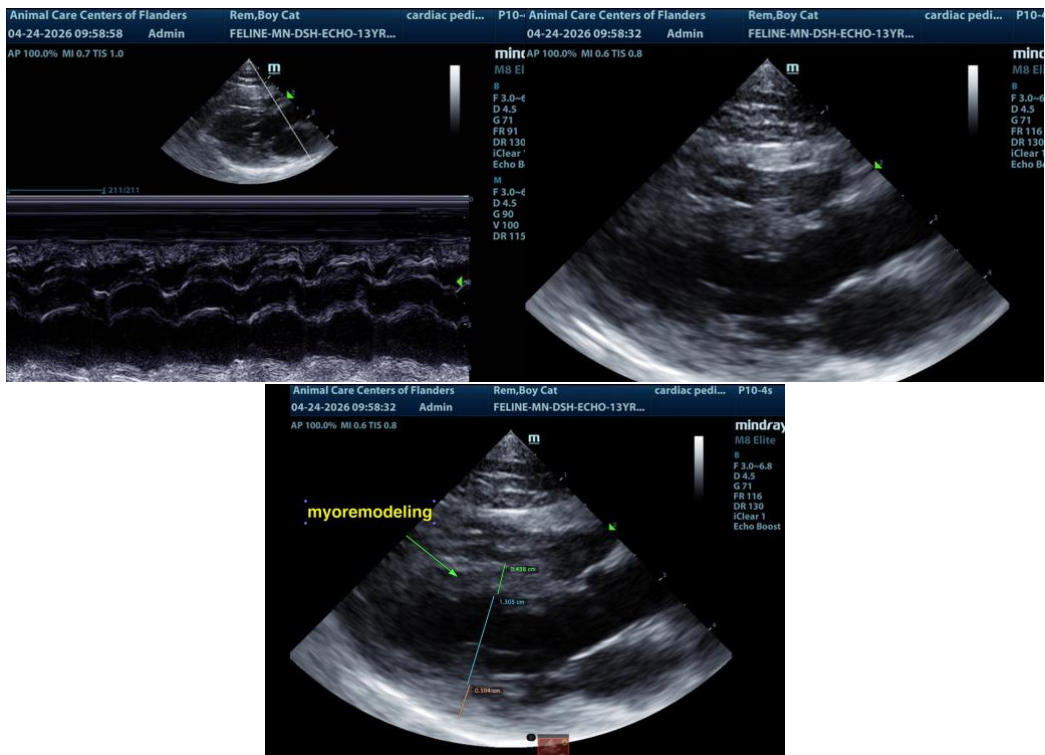
Dr. Hallihan

**INVOICE**

36768

**DATE**

4/24/26



The information and recommendations provided are based on the images presented by the referring veterinarian/sonographer. No evaluation can be communicated regarding pathology that was not visible in the image/video clips provided.

Thank you for this referral. If the clinical or image interpretation does not parallel your findings or if I can be of any further assistance please contact me.

**Eric Lindquist**, DMV, DABVP(CFM), Cert. IVUSS,  
CEO, Owner, Founder -- SonoPath.com  
[info@SonoPath.com](mailto:info@SonoPath.com)

**Biomarkers: NT-ProBNP Testing in Clinical Practice**

<http://www.sonopath.com/Biomarkers>

Natriuretic peptides have been widely demonstrated to be useful as markers of the presence and severity of cardiac disease. Brain natriuretic peptide (BNP) is secreted by the heart's ventricles in response to an increase in intracardiac hydrostatic pressure, increased cardiac wall stress, angiotensin II, myocardial hypoxia, and heightened sympathetic tone. BNP is synthesized as a prohormone precursor and is converted to the prohormone form in the ventricular myocytes. NT-proBNP is formed when its parent prohormone, proBNP, is cleaved into two molecules: NT-proBNP



**PATIENT**

Boy Cat Rem

**SPECIES**

Feline

**BREED**

DSH

**SEX**

Neutered Male

**AGE**

13 Years 5 Months

**WEIGHT**

12 Pounds

**INTERPRETED BY**

Eric Lindquist, DMV,  
DABVP (Canine &  
Feline), Cert. IVUSS

**IMAGING  
PERFORMED BY**

Heather

**HOSPITAL NAME**

ACC Flanders

**REFERRING VET**

Dr. Hallihan

**INVOICE**

36768

**DATE**

4/24/26

and C-BNP. In circulation, C-BNP rapidly degrades and is therefore difficult to measure in laboratory tests; however, NT-proBNP possesses a much longer half-life and is much easier to detect. Measuring NT-proBNP concentrations using the Cardiopet® proBNP test (IDEXX Laboratories) is recommended in the evaluation of heart failure in dogs and cats.

Several studies evaluating NT-proBNP in the veterinary population have documented its importance. In one study, NT-proBNP concentrations were significantly different for: healthy control dogs and dogs with cardiac disease; dogs with cardiac disease and congestive heart failure (CHF) and dogs with cardiac disease without CHF; and dogs with cardiac disease and cardiomegaly and dogs with cardiac disease without cardiomegaly. NT-proBNP levels have also been shown to offer a means of distinguishing between dogs diagnosed with cardiac disease and those diagnosed with respiratory disease but with no evidence of cardiac disease. In dogs with cardiomyopathy, the proBNP test demonstrated adequate sensitivity and specificity to be of diagnostic use.

**Indications for use:**

The proBNP test can be used to screen dogs with murmurs that are preclinical and as a guide for determining whether additional and more expensive diagnostic tests are required. In one study, NT-proBNP increased in proportion to the grade of murmur and degree of cardiac disease. Using NT-proBNP as a screening mechanism would be especially useful in at-risk breeds, such as Cavalier King Charles Spaniels, Cocker Spaniels, Dobermans, and Boxers.

One should evaluate NT-proBNP levels in puppies with severe murmurs and cases of patent ductus arteriosus (PDA), which can cause cardiomegaly in very young dogs. Elevated levels in a young dog would indicate the need for further testing.

Since auscultation is not very sensitive, assessing NT-proBNP levels may be especially useful for detecting subclinical heart disease in cats. If NT-proBNP is high, then additional imaging, such as radiographs and ultrasound, would be indicated. Reports indicate that NT-proBNP is higher in feline patients with systemic hypertension, severe renal failure, and hyperthyroidism. Therefore, blood pressures, renal parameters, and thyroid levels should be assessed to complete the interpretation of the results. Evaluating NT-proBNP may provide better screening information than standard auscultation, as cats without murmurs can have significant disease. Screening should be pursued in cats with breed predispositions (e.g. Maine Coon), murmurs, and gallops.

In animals with dyspnea, cough, and/or respiratory distress, the test can offer a good means of differentiating between primary cardiac disease and pulmonary disease. Because NT-proBNP testing provides immediate information, it may become increasingly common once the bedside test becomes available.

**Range of values:**

**Dogs:**



**PATIENT**

Boy Cat Rem

**SPECIES**

Feline

**BREED**

DSH

**SEX**

Neutered Male

**AGE**

13 Years 5 Months

**WEIGHT**

12 Pounds

- 500 pmol/l: Normal. Clinically significant heart disease is not present. If there is dyspnea, it is not due to CHF.
- 500-1100 pmol/l: Elevated. Heart disease may be present. Pursue additional diagnostics, especially if compatible signs are present.
- 1100-1725 pmol/l: Elevated and consistent with heart disease and possibly CHF. Additional workup strongly recommended.
- > 1725 pmol/l: Significantly elevated. CHF is probable and thus likely to be the cause of dyspnea.

**Cats:**

- < 45 pmol/l: Normal. Clinically significant heart disease is not present. If there is dyspnea, it is not due to CHF.
- 45-70 pmol/l: Elevated. Heart disease may be present. Pursue additional diagnostics, especially if compatible signs are present.
- 70-180 pmol/l: Elevated and consistent with heart disease and possibly CHF. Additional workup strongly recommended.
- > 180 pmol/l: Significantly elevated. CHF is probable and thus likely to be the cause of dyspnea.

**INTERPRETED BY**

Eric Lindquist, DMV, DABVP (Canine & Feline), Cert. IVUSS

**IMAGING PERFORMED BY**

Heather

**HOSPITAL NAME**

ACC Flanders

**REFERRING VET**

Dr. Hallihan

**INVOICE**

36768

**DATE**

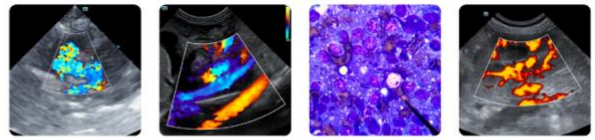
4/24/26

**Sample submission to IDEXX Laboratories:**

A special submission tube from IDEXX is ideally required for the submission of NT-proBNP samples. Blood is collected in an EDTA tube and then immediately centrifuged. The plasma is then transferred into the IDEXX tube (or, if not available, into another EDTA tube) and subsequently frozen. One must submit the sample to IDEXX in a Styrofoam container using specialized cold packs to keep it cold.

**Studies that have evaluated NT-proBNP levels:**

One study showed that serum NT-proBNP levels are higher in dogs with cardiac disease than in healthy dogs. The test demonstrated 83% sensitivity and 90% specificity; the cutoff level was > 445 pmol/l. NT-proBNP was significantly higher in dogs with class II and III heart disease compared to those with class I heart disease. It was also significantly higher in dogs with a grade V murmur (median 2233 pmol/l) compared to those with either grade III or IV murmurs (median 1010 pmol/l) or grade I or II murmurs (median 646 pmol/l). Dogs with CHF had an increased level of NT-proBNP (above 1725 pmol/l), whereas those without CHF had levels below 820 pmol/l (88% sensitivity and 76% specificity; PPV 77.5% and NPV of 87%). NT-proBNP levels also correlated positively with cardiomegaly findings on thoracic radiographs, elevated heart and respiratory rates, a left atrial aortic root ratio (LA:Ao ratio) > 1.5, and azotemia.



**PATIENT**

Boy Cat Rem

In another study, dogs with CHF had a much higher NT-proBNP level than dogs with primary respiratory disease (2554 pmol/l vs. 357 pmol/l); however, interestingly, NT-proBNP levels did not correlate with the vertebral heart score or LA:Ao ratio.

**SPECIES**

Feline

In a study with cats, NT-proBNP was significantly elevated in dyspneic cats with cardiac failure compared to cats with primary respiratory disease. The cutoff level was 180 pmol/L and the test demonstrated 94.1% sensitivity and 86.4% specificity. In a study of asymptomatic cats, NT-proBNP levels were used to differentiate between healthy cats and those with occult cardiac disease using a cutoff of 40 pmol/L; the test demonstrated 100% sensitivity and 87.5% specificity.

**BREED**

DSH

**SEX**

Neutered Male

**References:**

Boswood A, Dukes-McEwen J, Loureiro J, et al. The diagnostic accuracy of different natriuretic peptides in the investigation of canine cardiac disease. *J Smal Anim Prac* 2008;49:26-32.

**AGE**

13 Years 5 Months

Fine DM, Declue AE, Reiner CR. Evaluation of circulating amino terminal-pro-B-type natriuretic peptide concentration in dogs with respiratory distress attributable to congestive heart failure or primary pulmonary disease. *J Am Vet Med Assoc* 2008;232:1674-79.

**WEIGHT**

12 Pounds

Glaus T, Wess G. Left ventricular hypertrophy in the cat: When hypertrophic cardiomyopathy is not hypertrophic cardiomyopathy. *Schweiz Arch Tierheilkd* 2010;152:325-30.

**INTERPRETED BY**

Eric Lindquist, DMV, DABVP (Canine & Feline), Cert. IVUSS

Oyama MA, Fox PR, Rush JE, et al. Clinical utility of serum N-terminal pro-B-type natriuretic peptide concentration for identifying cardiac disease in dogs and assessing disease. *J Am Vet Med Assoc* 2008;232:1496-1503.

**IMAGING PERFORMED BY**

Heather

Oyama MA, Rush JE, Rozanski EA, et al. Assessment of serum N-terminal pro-B-type natriuretic peptide concentration for differentiation of congestive heart failure from primary respiratory tract disease as the cause of respiratory signs in dogs. *J Am Vet Med Assoc* 2009;235:1319-25.

**HOSPITAL NAME**

ACC Flanders

Oyama MA, Sisson DD, Solter PF. Prospective screening for occult cardiomyopathy in dogs by measurement of plasma atrial natriuretic peptide, B-type natriuretic peptide, and cardiac troponin-I concentrations. *Am J Vet Res* 2007;68:42-47.

**REFERRING VET**

Dr. Hallihan

**INVOICE**

36768

**DATE**

4/24/26