



PATIENT PRESENTING CLINICAL SIGNS

Sand Gadalla Increasing liver values. Previous ultrasound on 9/30/22. Non specific hepatopathy., Increase drinking
Abnormal PE/Chem/CBC/UA Results: Blood ALT 389 9/29/22, 1252 now, ALK PHOS 308

SPECIES

Canine

ULTRASONOGRAPHIC EXAMINATION OF THE ABDOMEN

Urinary System

BREED

Chihuahua

The **urinary bladder**, trigone, and pelvic urethra presented normal thicknesses and normal tone. The pelvic urethra was imaged 2.0 cm beyond the cystourethral junction and appeared normal. The ureters were not visible which is normal. No uroliths or sediment were visualized and anechoic urine was present. No evidence of inflammatory or neoplastic changes was noted. Ureteral papillae were normal.

SEX

Intact female

The left uterine horn was dilated to 1.0 cm and was tortuous. This is consistent with mucometra or pyometra. The right uterine horn was also dilated.

AGE

9 years

The **kidneys** revealed normal size and structure, corticomedullary definition and ratio for this age. The cortices presented largely uniform texture with normal echogenic relationship to liver and spleen. Medullary structure differed distinctly from the cortex and no evidence of pelvic dilation was present. The capsules were acceptably uniform without significant irregularities. The right kidney measured 3.67 cm with an idiopathic, hyperechoic medullary rim sign. The left kidney measured 3.77 cm.

WEIGHT

9.6 lbs

Adrenal Glands

Both **adrenal glands** were visualized and recognized as having normal shape, size, position and echogenicity for this breed. The phrenic vasculature, glandular echogenicity and detail were unremarkable. Capsule, cortex, and medullary definition were normal for this age patient. The left adrenal gland measured 0.46 cm at the caudal pole and 0.4 cm at the cranial pole. The right adrenal gland measured 1.8 x 0.52 cm at the cranial pole and 0.5 cm at the caudal pole.

INTERPRETED BY

Eric Lindquist, DMV
DABVP, Cert. IVUSS

Spleen

The **spleen** revealed minor, hypoechoic, heterogenous parenchymal changes. The spleen was normal in size and had a fairly normal contour.

IMAGING PERFORMED BY

JK

HOSPITAL NAME

Hamburg VC

Liver

REFERRING VET

Dr. DenHeyer

The **liver** revealed slight coarse architecture and normal size. The gallbladder and common bile duct were unremarkable.

INVOICE

43943

Gastrointestinal

There was some residual chyme and gas was noted in the **stomach**, yet not pathological. This is consistent with end post prandial presentation. Transit of chyme into the small intestine was normal. Curvilinear patterns were maintained throughout the GI tract. No evidence of pathology. Small and large intestine demonstrated normal luminal chyme and stool consistency respectively. No obstructive or overt infiltrative disease was noted. No associated abnormal lymphatic activity was noted.

DATE

4/24/23



PATIENT

Pancreas

Sand Gadalla

The base and limbs of the **pancreas** were observed to be largely isoechoic to surrounding omental fat. Pancreatic duct and capsular contour were acceptably normal and parenchyma respected normal curvilinear patterns. No overt evidence of active inflammatory or neoplastic disease was noted.

SPECIES

Canine

ULTRASONOGRAPHIC FINDINGS

BREED

Chihuahua

Dilated uterus. This is consistent with mucometra or pyometra. Structurally unremarkable liver, possible reactive the uterine pathology.

SEX

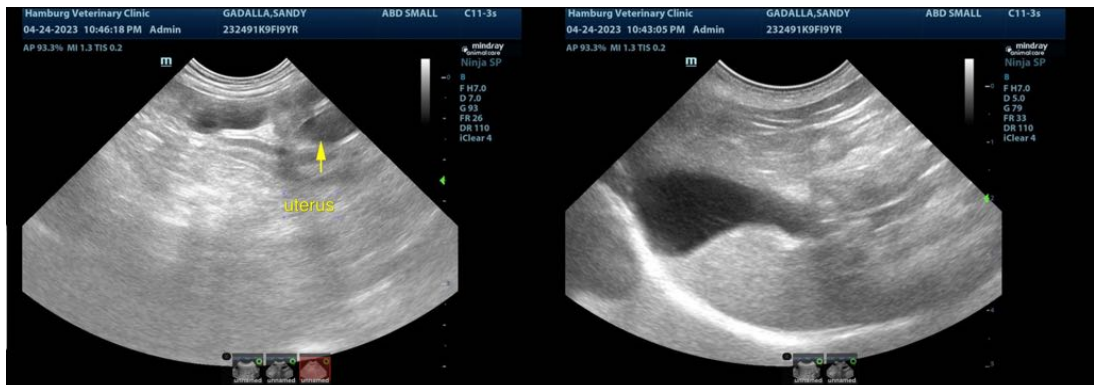
Intact female

INTERPRETATION OF THE FINDINGS & FURTHER RECOMMENDATIONS

I recommend ovariohysterectomy with liver biopsy. There is no evidence of neoplasia.

AGE

9 years



WEIGHT

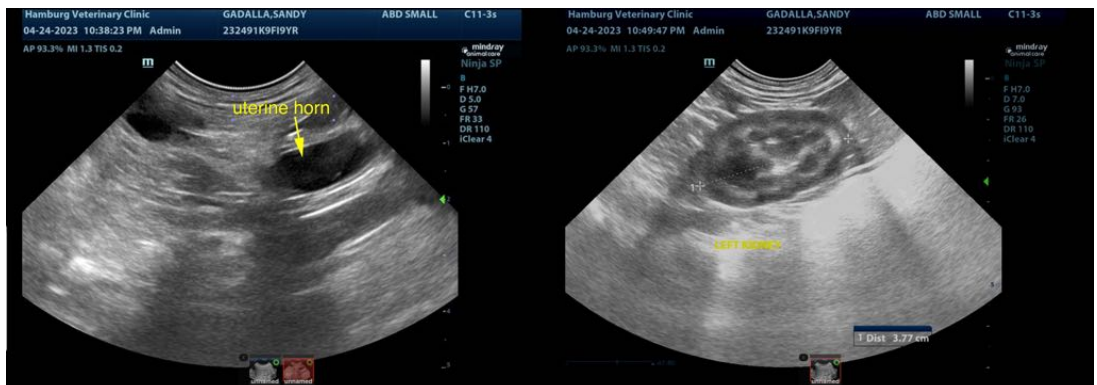
9.6 lbs

INTERPRETED BY

Eric Lindquist, DMV
DABVP, Cert. IVUSS

IMAGING PERFORMED BY

JK



HOSPITAL NAME

Hamburg VC

REFERRING VET

Dr. DenHeyer

INVOICE

43943

DATE

4/24/23



PATIENT

Sand Gadalla

SPECIES

Canine

BREED

Chihuahua

SEX

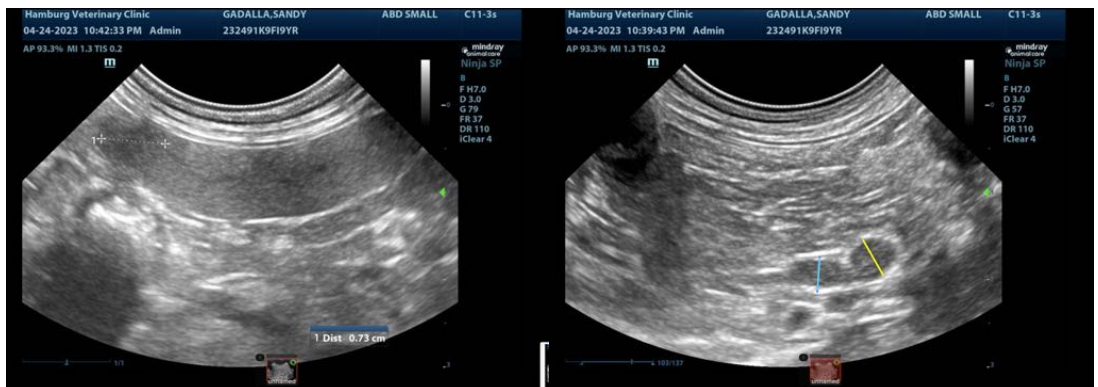
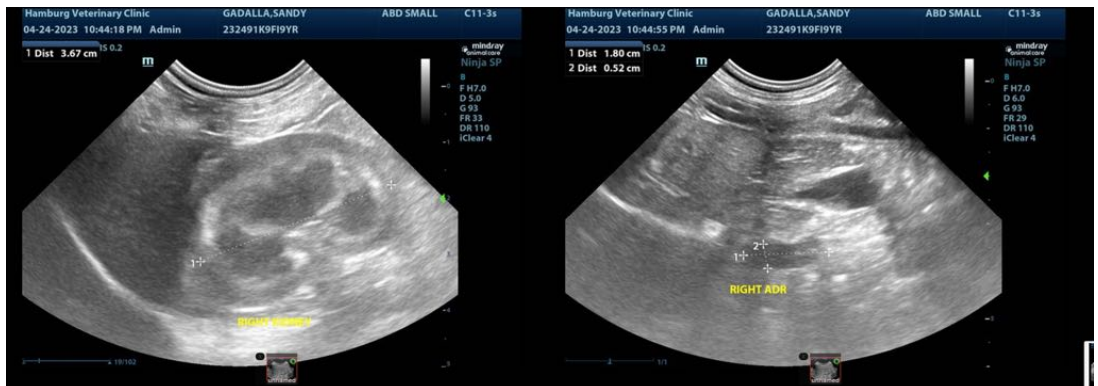Intact female

AGE

9 years

WEIGHT

9.6 lbs



INTERPRETED BY

Eric Lindquist, DMV
DABVP, Cert. IVUSS

IMAGING PERFORMED BY

JK

HOSPITAL NAME

Hamburg VC

REFERRING VET

Dr. DenHeyer

INVOICE

43943

DATE

4/24/23

The information and recommendations provided are based on the images presented by the referring veterinarian/sonographer. No evaluation can be communicated regarding pathology that was not visible in the image/video clips provided.

Thank you for this referral. If the clinical or image interpretation does not parallel your findings or if I can be of any further assistance please contact me.

Eric Lindquist, DMV, DABVP, Cert. IVUSS, CEO of SonoPath.com
info@SonoPath.com