



PATIENT

Laney Johnson

SPECIES

Canine

BREED

Collie

SEX

Spayed Female

AGE

9

WEIGHT

74

INTERPRETED BY

Eric Lindquist, DMV

DABVP, Cert. IVUSS

IMAGING PERFORMED BY

Jenn

HOSPITAL NAME

Rockaway AH

REFERRING VET

Dr. Maniar

INVOICE

46887

DATE

4/24/23

PRESENTING CLINICAL SIGNS

Recheck prev u/s 3/16 owner says dog is PU/PD increased frequency to urinate, softer poop, eating grass, gassy, panting, appetite normal no change in diet

ULTRASONOGRAPHIC EXAMINATION OF THE ABDOMEN

Urinary System

The **urinary bladder**, trigone, and pelvic urethra presented normal thicknesses and normal tone. The ureters were not visible which is normal. No uroliths or sediment were visualized and anechoic urine was present. No evidence of inflammatory or neoplastic changes were noted. Ureteral papillae were normal. The pelvic urethra was imaged 2.0 cm beyond the cystourethral junction.

The **left kidney** was normal in size with slight irregular contour at the cranial pole with corticomodullary mineralizations. The left kidney measured 6.44 cm.

The **right kidney** presented normal size and contour. The right kidney measured 7.0 cm.

Adrenal Glands

The **left adrenal gland** was visualized and recognized as having normal shape, size, position and echogenicity for this breed. The phrenic vasculature, glandular echogenicity and detail were unremarkable. Capsule, cortex, and medullary definition were normal for this age patient. The left adrenal gland measured 1.79 cm x 0.56 cm at the caudal pole and 0.53 cm at the cranial pole.

The region of the **right adrenal gland** was unremarkable.

Spleen

The **spleen** presented a smooth homogeneous parenchyma hyperechoic to liver and renal cortical parenchyma. The capsule was smooth without noticeable expansion or deviation from within the spleen or adjacent pathology. The splenic vasculature demonstrated normal volume without signs of congestion or thrombosis. No sonographic evidence of acute or chronic inflammatory, neoplastic, or infarctual changes were noted.

Liver

The **liver** images from right and left intercostal as well as subcostal views revealed subjectively normal liver size, contour, and structure. Some age-related parenchymal remodeling was noted but likely not clinically significant at this time. Vascular and biliary tracts were of normal volume and no evidence of congestion was noted. The gallbladder presented some dependent debris with essentially normal contour. The cystic and common bile ducts were normal. No overt evidence of active inflammatory, infiltrative or regenerative pathology was noted but should be paired with current or past LE elevations regarding any clinical significance to this presentation. The hepatic lymph nodes were unremarkable.

Gastrointestinal

The **stomach** revealed shadowing material. Given the patient history, this may represent grass accumulation measuring approximately 3.0 cm, non-obstructive. No fluid filled lumen noted. The small intestine and colon were unremarkable.

Pancreas

The base and limbs of the **pancreas** were observed to be largely isoechoic to surrounding omental fat. Pancreatic duct and capsular contour were acceptably normal and parenchyma respected normal curvilinear patterns. No overt evidence of active inflammatory or neoplastic disease was noted.



PATIENT

Laney Johnson

SPECIES

Canine

BREED

Collie

SEX

Spayed Female

AGE

9

WEIGHT

74

INTERPRETED BY

Eric Lindquist, DMV

DABVP, Cert. IVUSS

IMAGING PERFORMED BY

Jenn

HOSPITAL NAME

Rockaway AH

REFERRING VET

Dr. Maniar

INVOICE

46887

DATE

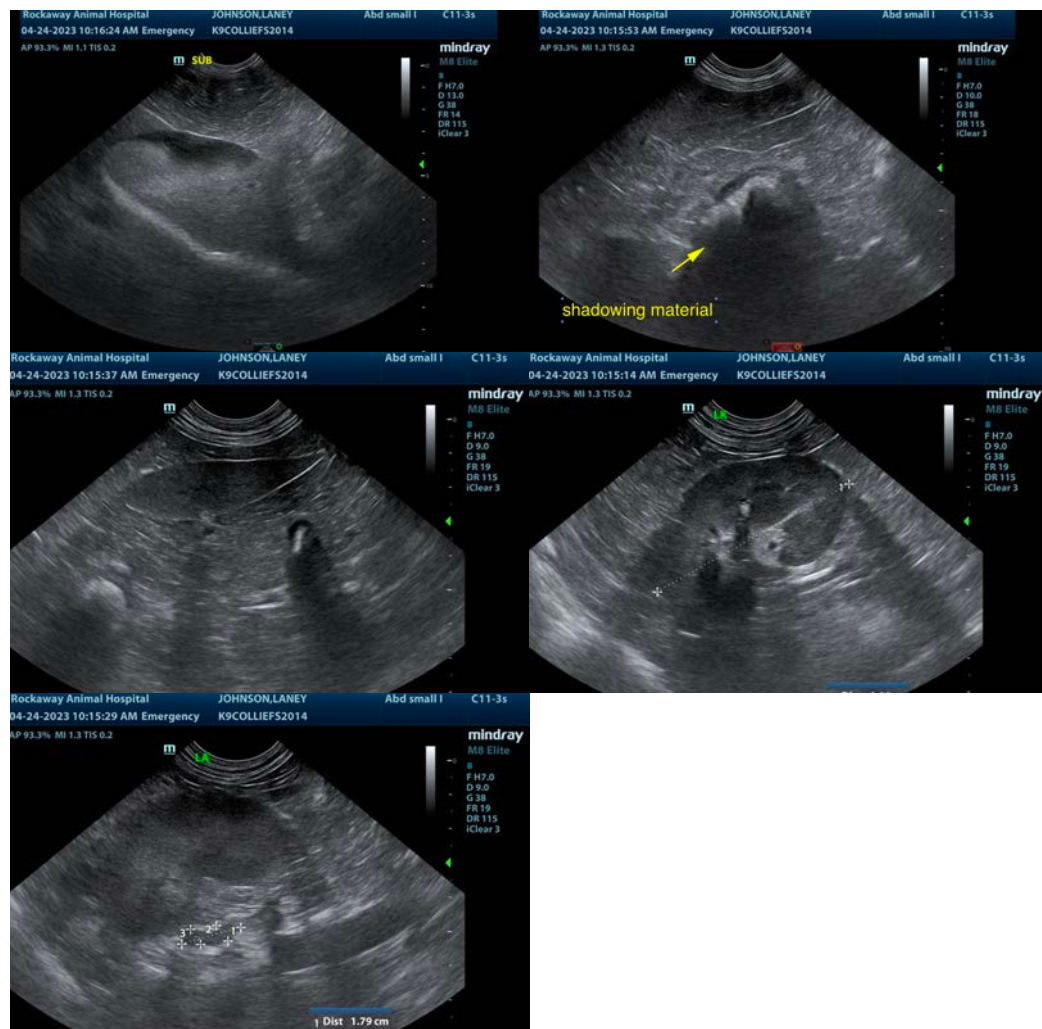
4/24/23

ULTRASONOGRAPHIC FINDINGS

- Minor left renal mineralization
- Luminal grass type density measuring approximately 3.0 cm in the stomach
- Age related hepatic changes

INTERPRETATION OF THE FINDINGS & FURTHER RECOMMENDATIONS

Endoscopy could be considered, especially if the patient was truly NPO prior to the sonogram. However, the remainder of the GI tract was unremarkable.



The information and recommendations provided are based on the images presented by the referring veterinarian/sonographer. No evaluation can be communicated regarding pathology that was not visible in the image/video clips provided.

Thank you for this referral. If the clinical or image interpretation does not parallel your findings or if I can be of any further assistance please contact me.

Eric Lindquist, DMV, DABVP, Cert. IVUSS, CEO of SonoPath.com

info@SonoPath.com