SonoPath
Clinical Sonography & Telecytology
EDUCATIONAL TELECONSULTATION SERVICES™

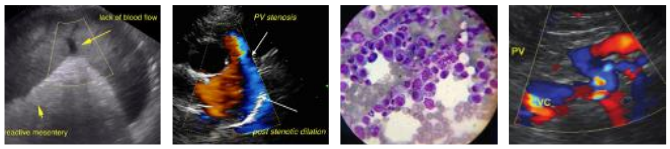

SonoPath.com
1-800-838-4268 info@sonopath.com

PATIENT
Kitty Hernandez

SPECIES
Canine

BREED
Poodle

SEX
Spayed Female

AGE
12

WEIGHT
21.6

INTERPRETED BY
Eric Lindquist, DMV DABVP, Cert. IVUSS

IMAGING PERFORMED BY
Jenn

HOSPITAL NAME
Rockaway AH

REFERRING VET
Dr. Maniar

INVOICE
22166

DATE
4/24/23

PRESENTING CLINICAL SIGNS

History: re check prev u/s on 4/17 showed inflamed gallbladder mucocele owners declined surgery dog is doing ok actually a little brighter

ULTRASONOGRAPHIC EXAMINATION OF THE ABDOMEN

Urinary System

The **urinary bladder**, trigone, and pelvic urethra presented normal thicknesses and normal tone. The ureters were not visible which is normal. No uroliths or sediment were visualized and anechoic urine was present. No evidence of inflammatory or neoplastic changes were noted. Ureteral papillae were normal. The pelvic urethra was imaged 2.0 cm beyond the cystourethral junction.

The **kidneys** revealed largely normal size and structure, corticomedullary definition and ratio (cortex 1/3 of medulla) were essentially maintained with some moderate age-related loss of curvilinear patterns regarding the capsule and C/M junction. The cortices presented largely uniform texture with some increased echogenicity expected for his age patient. Medullary structure differed distinctly from that of the cortex and no evidence of pelvic dilation was present. The right kidney measured 4.72 cm. The left kidney measured 4.12 cm.

Adrenal Glands

The **left adrenal gland** was slightly irregular, similar to the prior sonogram. The left adrenal gland measured 1.64 cm x 0.86 cm at the cranial pole and 0.57 cm at the cranial pole.

The **right adrenal gland** was normal in size and contour, measuring 3.01 cm x 1.07 cm at the cranial pole and 0.7 cm at the caudal pole.

Spleen

The **spleen** presented a smooth homogeneous parenchyma hyperechoic to liver and renal cortical parenchyma. The capsule was smooth without noticeable expansion or deviation from within the spleen or adjacent pathology. The splenic vasculature demonstrated normal volume without signs of congestion or thrombosis. No sonographic evidence of acute or chronic inflammatory, neoplastic, or infarctual changes were noted.

Liver

The **liver** itself revealed an adjacent abscessation that has developed, apical to the gallbladder itself, likely owing to rupture and leakage. The inflamed gallbladder mucocele is persistent and continually inflamed, mildly improved from the prior sonogram. The common bile duct was persistently dilated with inspissated debris, measuring 1.4 cm.

Gastrointestinal

The **stomach** revealed a moderate amount of luminal fluid accumulation with pronounced mucosal hypertrophy. The small intestine and colon were unremarkable.

Pancreas

The base and limbs of the **pancreas** were observed to be largely isoechoic to surrounding omental fat. Pancreatic duct and capsular contour were acceptably normal and parenchyma respected normal curvilinear patterns. No overt evidence of active inflammatory or neoplastic disease was noted.

SonoPath
Clinical Sonography & Telecytology

EDUCATIONAL TELECONSULTATION SERVICES™

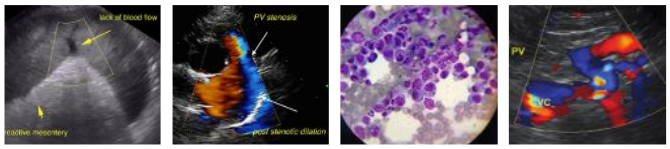

SonoPath.com
1-800-838-4268 info@sonopath.com

PATIENT

Kitty Hernandez

SPECIES

Canine

BREED

Poodle

SEX

Spayed Female

AGE

12

WEIGHT

21.6

INTERPRETED BY

Eric Lindquist, DMV
DABVP, Cert. IVUSS

IMAGING PERFORMED BY

Jenn

HOSPITAL NAME

Rockaway AH

REFERRING VET

Dr. Maniar

INVOICE

22166

DATE

4/24/23

ULTRASONOGRAPHIC FINDINGS

- Gallbladder mucocele, progressive inflammation and localized abscess. Persistently dilated common bile duct (with inspissated debris).
- Concurrent gastritis
- Slightly irregular left adrenal gland, similar to the prior sonogram
- Age-related renal changes

INTERPRETATION OF THE FINDINGS & FURTHER RECOMMENDATIONS

Surgical intervention/cholecystectomy is essential in this patient.

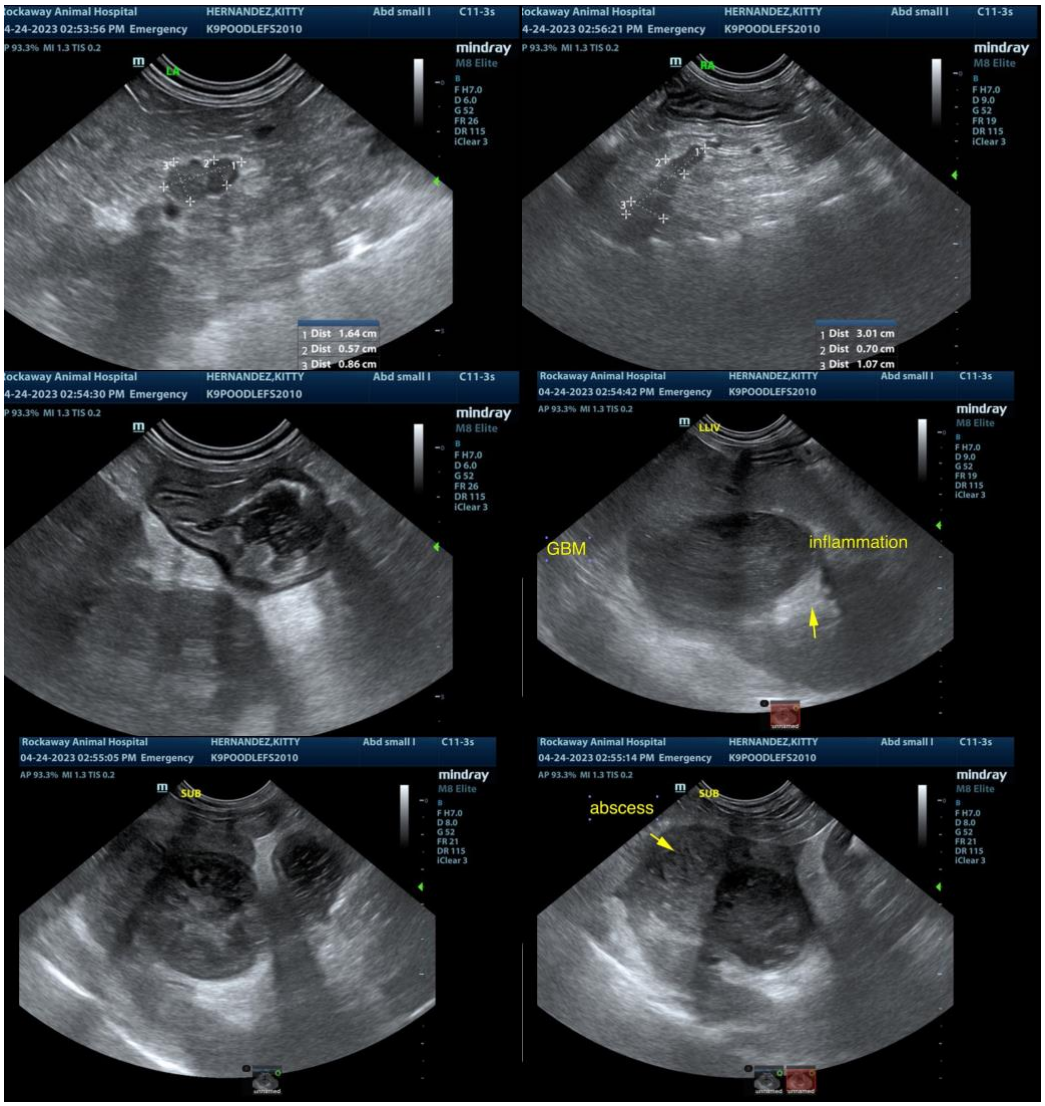

SonoPath

Clinical Sonography & Telecytology

EDUCATIONAL TELECONSULTATION SERVICES™

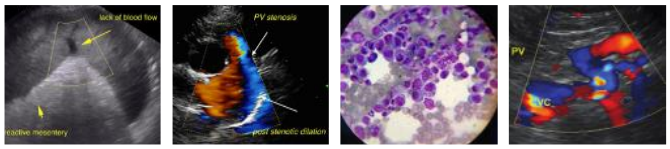

SonoPath.com™
1-800-838-4268 info@sonopath.com

PATIENT

Kitty Hernandez

SPECIES

Canine

BREED

Poodle

SEX

Spayed Female

AGE

12

WEIGHT

21.6

INTERPRETED BY

Eric Lindquist, DMV
DABVP, Cert. IVUSS

IMAGING PERFORMED BY

Jenn

HOSPITAL NAME

Rockaway AH

REFERRING VET

Dr. Maniar

INVOICE

22166

DATE

4/24/23

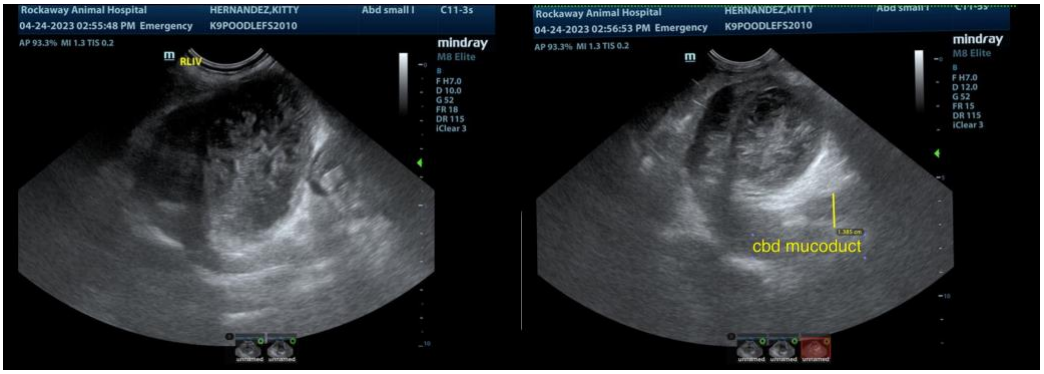

The information and recommendations provided are based on the images presented by the referring veterinarian. No evaluation can be communicated regarding pathology that was not visible in the image/video clips provided.

Thank you for this referral. If the clinical or image interpretation does not parallel your findings or if I can be of any further assistance please contact me.

Eric Lindquist, DMV, DABVP, Cert. IVUSS, CEO of SonoPath.com
info@SonoPath.com