



PATIENT

Walker French

SPECIES

Canine

BREED

Husky

SEX

Neutered Male

AGE

10 Years

WEIGHT

78 pounds

INTERPRETED BY

Eric Lindquist, DMV,
DABVP(CFM), Cert.
IVUSS

IMAGING PERFORMED BY

Dr. Brandon Adkins

HOSPITAL NAME

Royer Veterinary
Services

REFERRING VET

Dr. Brandon Adkins

INVOICE

15407

DATE

04/23/26

PRESENTING CLINICAL SIGNS

Walker French presents for not acting right when eating and no bowel movements for 2 days
Patient History: Diarrhea on Monday with lethargy all day Monday. No bowel movements for 2+ days despite straining to defecate. Appetite normal until this morning when he refused breakfast. No previous episodes of similar signs. No recent diet changes, new treats, table scraps, or trash ingestion. No vomiting. Mild tenderness on abdominal palpation. CBC/Chem10 WNL

ULTRASONOGRAPHIC EXAMINATION OF THE ABDOMEN

Urinary System

The **urinary bladder** presented a relatively uniform thickening of the cranioventral and craniodorsal mucosae with micropolypoid mucosal changes without involvement of the submucosae. The urine presented some echogenicity consistent with suspended debris. No evidence of urethral pathology was present. This presentation is most consistent with chronic cystitis. Technically transitional cell carcinoma cannot be ruled out without histopathological review but is not overtly suspected based on this pattern. Cystocentesis and urine culture +/- pathological review of urine cytology would be warranted. No overt calculi were present at this time. The urethra was visible to a depth of 2.0 cm. Wall thickness measured 0.80 cm.

The residual prostate measured 1.0 cm.

The **kidneys** revealed normal size and structure, corticomedullary definition and ratio for this age. The cortices presented largely uniform texture with normal echogenic relationship to liver and spleen. Medullary structure differed distinctly from the cortex and no evidence of pelvic dilation was present. The capsules were acceptably uniform without significant irregularities. The left kidney measured 7.0 cm in length. The right kidney measured 6.8 cm in length.

Adrenal Glands

Both **adrenal glands** were visualized and recognized as having normal shape, size, position and echogenicity for this breed. The phrenic vasculature, glandular echogenicity and detail were unremarkable. Capsule, cortex, and medullary definition were normal for this age patient. The left adrenal gland measured 0.60 cm width. The right adrenal gland measured 0.60 cm width at the caudal pole and approximately 0.80 cm width at the cranial pole.

Spleen

The **spleen** presented a smooth homogeneous parenchyma hyperechoic to liver and renal cortical parenchyma. The capsule was smooth without noticeable expansion or deviation from within the spleen or adjacent pathology. The splenic vasculature demonstrated normal volume without signs of congestion or thrombosis. No sonographic evidence of acute or chronic inflammatory, neoplastic, or infarctual changes were noted.

Liver

The **liver** images from right and left intercostal as well as subcostal views revealed subjectively normal liver size, contour, and structure. Some mild age-related parenchymal remodeling was noted but likely not clinically significant at this time. Vascular and biliary tracts were of normal volume and no evidence of congestion was noted. The gallbladder presented some dependent debris with essentially normal contour. The cystic and common bile ducts were normal. No overt evidence of active inflammatory,



PATIENT

Walker French

SPECIES

Canine

BREED

Husky

SEX

Neutered Male

AGE

10 Years

WEIGHT

78 pounds

INTERPRETED BY

Eric Lindquist, DMV,
DABVP(CFM), Cert.
IVUSS

IMAGING PERFORMED BY

Dr. Brandon Adkins

HOSPITAL NAME

Royer Veterinary
Services

REFERRING VET

Dr. Brandon Adkins

INVOICE

15407

DATE

04/23/26

infiltrative or regenerative pathology was noted but should be paired with current or past LE elevations regarding any clinical significance to this presentation. The hepatic lymph nodes were unremarkable.

Gastrointestinal

There was some residual chyme and gas was noted in the **stomach**, yet not pathological. This is consistent with end post prandial presentation. Transit of chyme into the small intestine was normal. Curvilinear patterns were maintained throughout the GI tract. No evidence of pathology. Small and large intestine demonstrated normal luminal chyme and stool consistency respectively. No obstructive or overt infiltrative disease was noted. No associated abnormal lymphatic activity was noted.

Pancreas

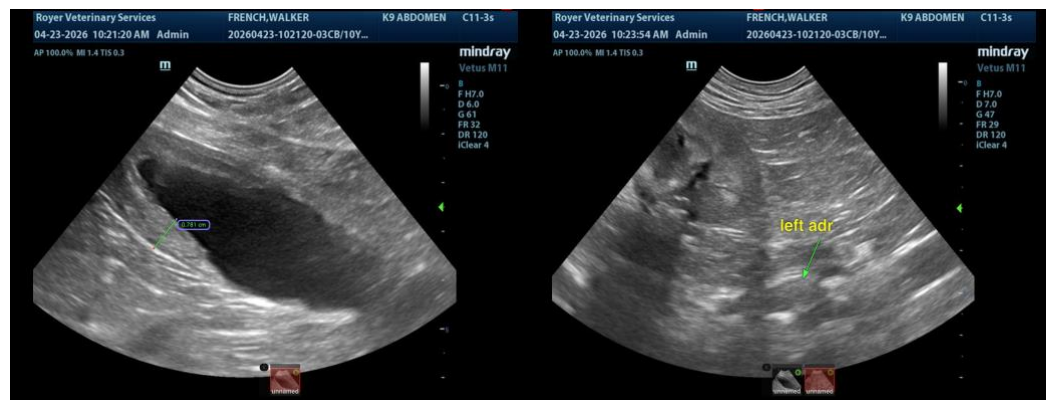The base and limbs of the **pancreas** were observed to be largely isoechoic to surrounding omental fat. Pancreatic duct and capsular contour were acceptably normal and parenchyma respected normal curvilinear patterns. No overt evidence of active inflammatory or neoplastic disease was noted.

ULTRASONOGRAPHIC FINDINGS

- Chronic cystitis bladder pattern.
- Unremarkable geriatric abdomen otherwise.

INTERPRETATION OF THE FINDINGS & FURTHER RECOMMENDATIONS

Full urinary work up is warranted. The cause of the lethargy is unclear in this patient. Orthopedic pain, CNS or thoracic disease should be considered.





PATIENT

Walker French

SPECIES

Canine

BREED

Husky

SEX

Neutered Male

AGE

10 Years

WEIGHT

78 pounds

INTERPRETED BY

Eric Lindquist, DMV,
DABVP(CFM), Cert.
IVUSS

IMAGING PERFORMED BY

Dr. Brandon Adkins

HOSPITAL NAME

Royer Veterinary
Services

REFERRING VET

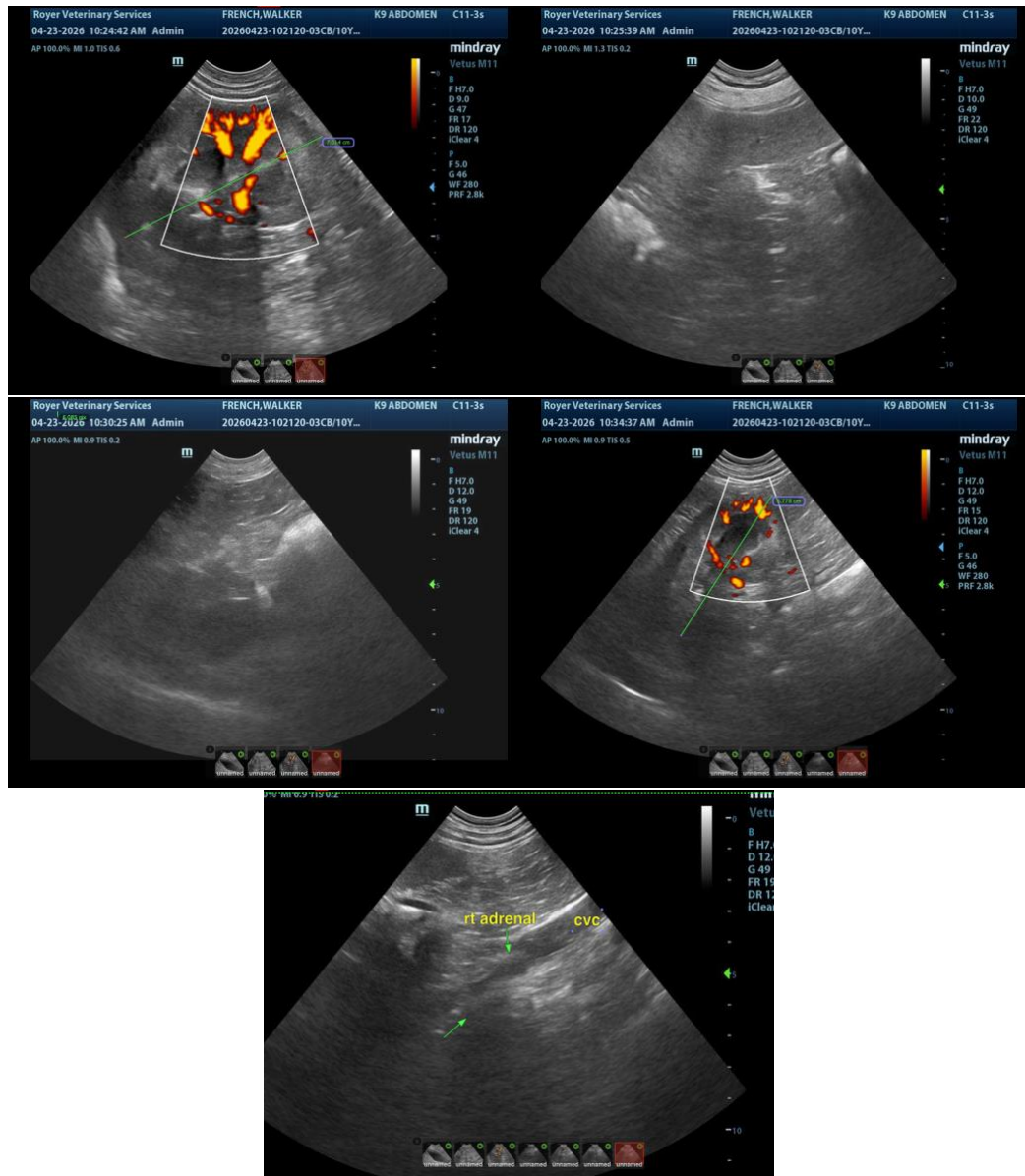
Dr. Brandon Adkins

INVOICE

15407

DATE

04/23/26



The information and recommendations provided are based on the images presented by the referring veterinarian/sonographer. No evaluation can be communicated regarding pathology that was not visible in the image/video clips provided.

Thank you for this referral. If the clinical or image interpretation does not parallel your findings or if I can be of any further assistance, please contact me.

Eric Lindquist, DMV, DABVP(CFM), Cert. IVUSS,

CEO, Owner, Founder -- SonoPath.com

info@SonoPath.com



PATIENT

Walker French

SPECIES

Canine

BREED

Husky

SEX

Neutered Male

AGE

10 Years

WEIGHT

78 pounds

INTERPRETED BY

Eric Lindquist, DMV,
DABVP(CFM), Cert.
IVUSS

IMAGING PERFORMED BY

Dr. Brandon Adkins

HOSPITAL NAME

Royer Veterinary
Services

REFERRING VET

Dr. Brandon Adkins

INVOICE

15407

DATE

04/23/26