



PATIENT

Sharah Oden

SPECIES

Canine

BREED

Rottweiler

SEX

Intact Female

AGE

5 Years

WEIGHT

86 pounds

INTERPRETED BY

Eric Lindquist, DMV,
DABVP(CFM), Cert.
IVUSS

IMAGING PERFORMED BY

Amy Jagger DVM

HOSPITAL NAME

VCA Parkway Animal
Hospital

REFERRING VET

Amy Jagger DVM

INVOICE

15359

DATE

04/23/26

PRESENTING CLINICAL SIGNS

Significant weight loss over the past year (40#, was 125lb dog). Appetite is great, eats the same diet/volume as littermate who is still about 125lb.

Abnormal PE/Chem/CBC/UA Results: Mildly decreased albumin TOTAL PROTEIN 6.6 (5 - 7.4) g/dL ALBUMIN 2.6 (2.7 - 4.4) g/dL GLOBULIN 4.0 (1.6 - 3.6) g/dL A/G RATIO 0.7 (0.8 - 2)

ULTRASONOGRAPHIC EXAMINATION OF THE ABDOMEN

Urinary System

The **urinary bladder**, trigone, and pelvic urethra to a depth of 2.0 cm presented normal thicknesses and normal tone. The ureters were not visible which is normal. No uroliths or sediment were visualized, and anechoic urine was present. No evidence of inflammatory or neoplastic changes were noted. Ureteral papillae were normal.

The **kidneys** revealed normal size and structure, corticomedullary definition and ratio for this age. The cortices presented largely uniform texture with normal echogenic relationship to liver and spleen. Medullary structure differed distinctly from the cortex and no evidence of pelvic dilation was present. The capsules were acceptably uniform without significant irregularities. The left kidney measured 6.9 cm in length. The right kidney measured 7.2 cm in length.

Adrenal Glands

Both **adrenal glands** were visualized and recognized as having normal shape, size, position and echogenicity for this breed. The phrenic vasculature, glandular echogenicity and detail were unremarkable. Capsule, cortex, and medullary definition were normal for this age patient. The left adrenal gland measured 0.74 cm width. The right adrenal gland measured 1.13 cm width at the cranial pole and 0.59 cm width at the caudal pole.

Spleen

The **spleen** revealed a focal hypoechoic nodule measuring 0.97 cm. The spleen also revealed folding of at the cranial body.

Liver

The **liver** images submitted revealed subjectively normal liver size, contour, and structure. Parenchymal echogenicity was naturally coarse and hypoechoic to the spleen. Vascular and biliary tracts were of normal volume with no evidence of congestion. The gallbladder presented acceptably thin walls with primarily anechoic content. The cystic and common bile ducts were normal. No pathological hepatic lymphadenopathy was evident. No overt structural evidence of inflammatory, infiltrative or regenerative pathology was evident.

Gastrointestinal

Examination of the **gastrointestinal tract** revealed a stomach and intestine free of stasis, of normal wall thickness, acceptable curvilinear mural detail, and peristaltic activity. Small and large intestine demonstrated normal luminal chyme and stool consistency respectively. No obstructive or overt infiltrative disease was noted. No associated abnormal lymphatic activity was noted.

Pancreas



PATIENT

Sharah Oden

SPECIES

Canine

BREED

Rottweiler

SEX

Intact Female

AGE

5 Years

WEIGHT

86 pounds

INTERPRETED BY

Eric Lindquist, DMV,
DABVP(CFM), Cert.
IVUSS

IMAGING PERFORMED BY

Amy Jagger DVM

HOSPITAL NAME

VCA Parkway Animal
Hospital

REFERRING VET

Amy Jagger DVM

INVOICE

15359

DATE

04/23/26

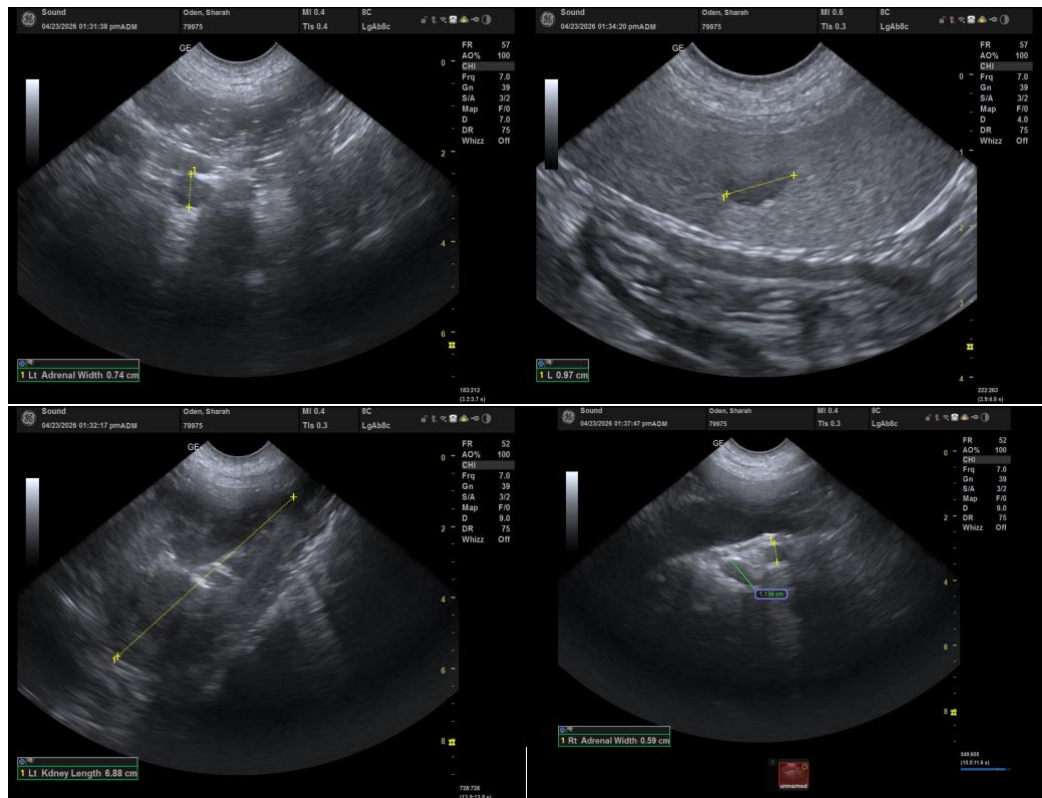
The base and limbs of the **pancreas** were observed to be largely isoechoic to surrounding omental fat. Pancreatic duct and capsular contour were acceptably normal and parenchyma respected normal curvilinear patterns. No overt evidence of active inflammatory or neoplastic disease was noted.

ULTRASONOGRAPHIC FINDINGS

- Focal splenic nodule.
- Unremarkable abdomen otherwise.

INTERPRETATION OF THE FINDINGS & FURTHER RECOMMENDATIONS

FNA of the splenic nodule is indicated, however, I am concerned for either maldigestion or occult neoplasia in other cavities such as CNS or thorax. Yet the small splenic nodule may be a focal manifestation of a more diffuse process. Differentials include round cell neoplasia, hyperplasia, emerging hemangiosarcoma.





PATIENT

Sharah Oden

SPECIES

Canine

BREED

Rottweiler

SEX

Intact Female

AGE

5 Years

WEIGHT

86 pounds

INTERPRETED BY

Eric Lindquist, DMV,
DABVP(CFM), Cert.
IVUSS

IMAGING PERFORMED BY

Amy Jagger DVM

HOSPITAL NAME

VCA Parkway Animal
Hospital

REFERRING VET

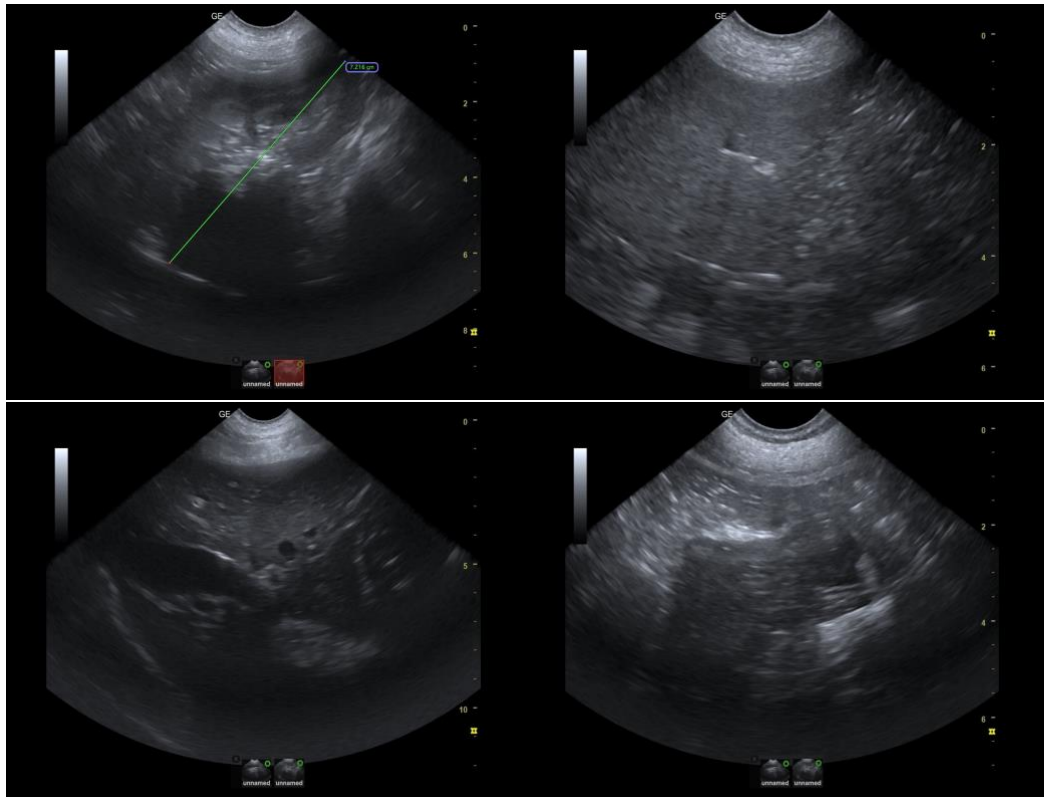
Amy Jagger DVM

INVOICE

15359

DATE

04/23/26



The information and recommendations provided are based on the images presented by the referring veterinarian/sonographer. No evaluation can be communicated regarding pathology that was not visible in the image/video clips provided.

Thank you for this referral. If the clinical or image interpretation does not parallel your findings or if I can be of any further assistance, please contact me.

Eric Lindquist, DMV, DABVP(CFM), Cert. IVUSS,

CEO, Owner, Founder -- SonoPath.com

info@SonoPath.com