



PATIENT

Oreo Jaszkowski

SPECIES

Canine

BREED

Chihuahua Mix

SEX

Intact Male

AGE

10 Years

WEIGHT

15.4 Pounds

INTERPRETED BY

Eric Lindquist, DMV,
DABVP (Canine &
Feline), Cert. IVUSS

IMAGING PERFORMED BY

Dr. Megan Bray

HOSPITAL NAME

Taylorsville VC

REFERRING VET

Dr. Ashleigh Bisset

INVOICE

36727

DATE

4/23/26

PRESENTING CLINICAL SIGNS

History: Oreo is a 10-year-old intact female Chihuahua mix presenting for recheck echo. Patient previously had an echo performed in 10/2025 due to a grade IV/VI murmur on exam - echo revealed chronic mitral valve disease (ACVIM probable B2 - B2+, possible emerging C) and minor TR - no evidence of clinical pulmonary hypertension. Patient was started on Vetmedin and Cardalis at this time.

Abnormal PE/Chem/CBC/UA Results: Starting in April of 2026, patient has had intermittent episodes of heavy and fast breathing within increase in coughing. Chest rads on 4/17 showed a mildly enlarged heart but no evidence of pulmonary edema.

ULTRASONOGRAPHIC EXAMINATION OF THE HEART

CANINE CARDIAC PARAMETERS	MR VMAX (m/s)	TR VMAX (m/s)	LA/AO (M-Mode)	LA/AO (Heart Base; Swe)	FS (%)	EF (%)	EPSS (cm)
NORMAL PARAMETER	4.5-5.5	<2.7	1.3	Up to 1.6	28-40	40-100	<0.6
PATIENT	6.2	3.0	1.4	1.5	45	--	0.1
CANINE CARDIAC PARAMETERS	HR (BPM)	AV VMAX (m/s)	PV MAX (m/s)	BODY WEIGHT (lbs)	LAD LA MAX 4 Chamber	LVIDd Avg; 2D and m-mode short axis (cm)	LVIDs Avg; 2D and m-mode short axis (cm)
NORMAL PARAMETER	50-100	0.7-1.7	0.7-1.6				
PATIENT	79	2.0	.70	15.4	3.1	3.0	--

Cardiac Presentation

The cardiac presentation revealed slight volume overload in the left atrium and left ventricle. Slight left atrial enlargement was noted. Moderate centralized mitral insufficiency was noted. Contractility was adequately compensatory. Pulmonic and aortic outflows were unremarkable. Trivial tricuspid insufficiency was noted.

ULTRASONOGRAPHIC FINDINGS

- Stable B-2 valvular disease
- Mitral and tricuspid insufficiency
- Slight left atrial enlargement, fairly stable



PATIENT

Oreo Jaskowski

SPECIES

Canine

BREED

Chihuahua Mix

SEX

Intact Male

AGE

10 Years

WEIGHT

15.4 Pounds

INTERPRETED BY

Eric Lindquist, DMV,
DABVP (Canine &
Feline), Cert. IVUSS

IMAGING PERFORMED BY

Dr. Megan Bray

HOSPITAL NAME

Taylorville VC

REFERRING VET

Dr. Ashleigh Bisset

INVOICE

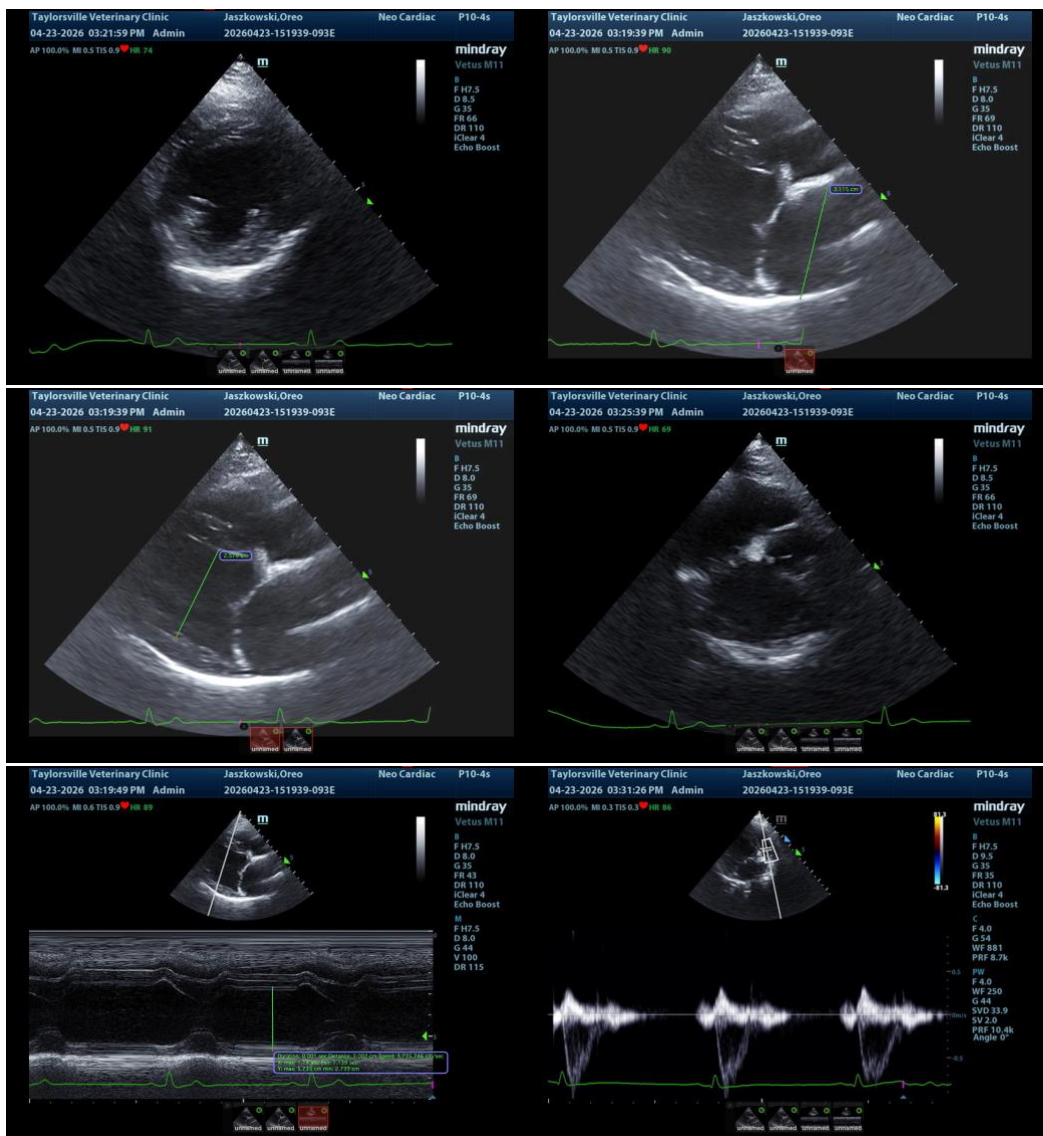
36727

DATE

4/23/26

INTERPRETATION OF THE FINDINGS & FURTHER RECOMMENDATIONS

Recommend continuation of Vetmedin and Cardalis at this time. I do not believe the volume overload is adequate to cause coughing in this patient. Holter monitor may be appropriate if clinical signs persist. Recheck echo is recommended in 6 months.





PATIENT

Oreo Jazzkowski

SPECIES

Canine

BREED

Chihuahua Mix

SEX

Intact Male

AGE

10 Years

WEIGHT

15.4 Pounds

INTERPRETED BY

Eric Lindquist, DMV,
DABVP (Canine &
Feline), Cert. IVUSS

**IMAGING
PERFORMED BY**

Dr. Megan Bray

HOSPITAL NAME

Taylorsville VC

REFERRING VET

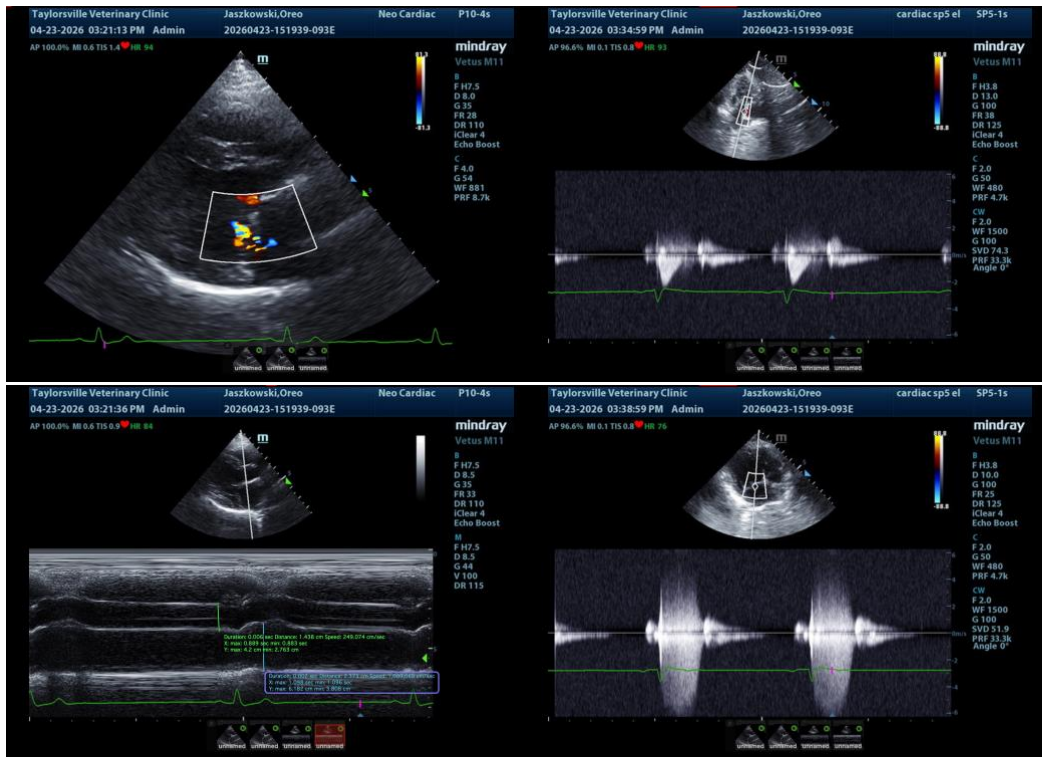
Dr. Ashleigh Bisset

INVOICE

36727

DATE

4/23/26



The information and recommendations provided are based on the images presented by the referring veterinarian/sonographer. No evaluation can be communicated regarding pathology that was not visible in the image/video clips provided.

Thank you for this referral. If the clinical or image interpretation does not parallel your findings or if I can be of any further assistance please contact me.

Eric Lindquist, DMV, DABVP(CFM), Cert. IVUSS,
CEO, Owner, Founder -- SonoPath.com
info@SonoPath.com