

PATIENT

Marlee Welch

SPECIES

Canine

BREED

Australian Shepherd

SEX

Spayed Female

AGE

12 Years

WEIGHT

53 Pounds

INTERPRETED BY

Eric Lindquist, DMV,
 DABVP (Canine &
 Feline), Cert. IVUSS

IMAGING PERFORMED BY

Crystal Hill

HOSPITAL NAME

The Maples AH

REFERRING VET

Dr. Kazienko

INVOICE

36714

DATE

4/23/26

PRESENTING CLINICAL SIGNS

History: Seen April 17 for two week history of hacking/horking after eating. Choked on a piece of an apple, had a hard time swallowing it. Trembling, shaking over last few weeks, not herself. No V/D, happy to eat but much slower, normally a frantic fast eater. Panting more even at rest. No other breathing issues seen. No exercise intolerance noted but seems more lethargic overall. PE - no nasal discharge, airway sounds normal, firm palpable swelling around the trachea distal to the larynx which is the size of an apple. Most prominent on the left. Trachea palpates normally. April 22 for US mass has grown, appetite worsening, energy further decreased, not wanting to go for walks. Has been on Clavaseptin.

Abnormal PE/Chem/CBC/UA Results: ALKP 180(5-131U/L) Glucose 3.1 (3.9-7.7) T4 9.0(10-45nmol/L).

ULTRASONOGRAPHIC EXAMINATION OF THE ABDOMEN

Urinary System

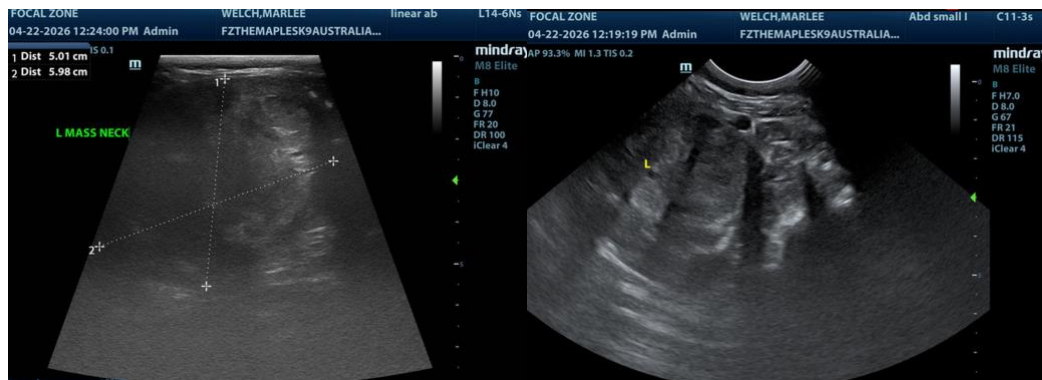The left cervical region revealed an undifferentiated 6.0 cm nodular mass. This appears encapsulated, deviating the carotid artery. The mass appears to impinge upon the trachea and esophagus. The exact origin of the left-sided mass is unclear. It appears to be outside the carotid artery. This, along with a minimal vascularity noted, would suggest this is not thyroid in origin. Esophageal origin, or other regional tissues is possible. The region of the right thyroid lobe was unremarkable.

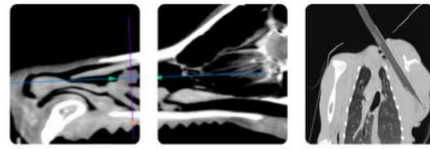
ULTRASONOGRAPHIC FINDINGS

- Undifferentiated, largely encapsulated mass, potentially deriving from the esophagus or regional tissues with tracheal impingement and/or envelopment. Possibly thyroid origin but unlikely.

INTERPRETATION OF THE FINDINGS & FURTHER RECOMMENDATIONS

Ultrasound guided 22-gauge FNA of the mass is indicated. CT evaluation for potential surgical assessment is indicated.





PATIENT

Marlee Welch

SPECIES

Canine

BREED

Australian Shepherd

SEX

Spayed Female

AGE

12 Years

WEIGHT

53 Pounds

INTERPRETED BY

Eric Lindquist, DMV,
DABVP (Canine &
Feline), Cert. IVUSS

**IMAGING
PERFORMED BY**

Crystal Hill

HOSPITAL NAME

The Maples AH

REFERRING VET

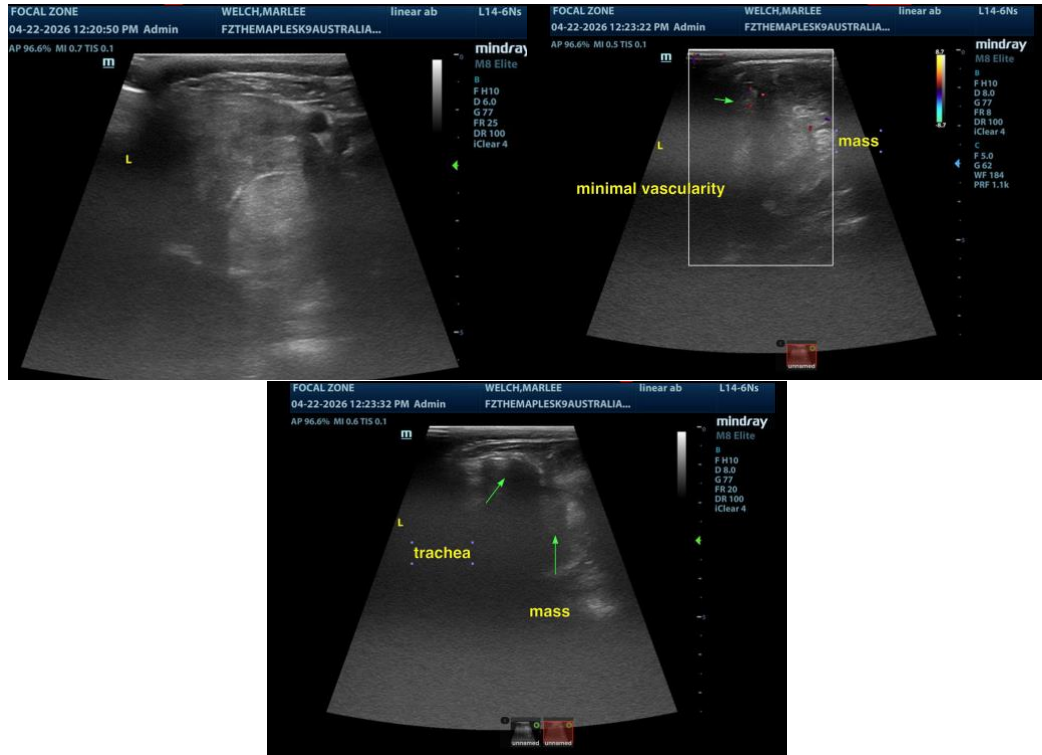
Dr. Kazienko

INVOICE

36714

DATE

4/23/26



The information and recommendations provided are based on the images presented by the referring veterinarian/sonographer. No evaluation can be communicated regarding pathology that was not visible in the image/video clips provided.

Thank you for this referral. If the clinical or image interpretation does not parallel your findings or if I can be of any further assistance please contact me.

Eric Lindquist, DMV, DABVP, Cert. IVUSS, CEO of SonoPath.com

info@SonoPath.com