



PATIENT

Malibu Kelly

SPECIES

Canine

BREED

Chihuahua

SEX

Spayed Female

AGE

2 Years 2 Months

WEIGHT

7.4 pounds

INTERPRETED BY

Eric Lindquist, DMV,
DABVP(CFM), Cert.
IVUSS

IMAGING PERFORMED BY

Chloe Lowe CVT

HOSPITAL NAME

Denville Animal
Hospital

REFERRING VET

Dr. Reddy

INVOICE

15354

DATE

04/23/26

PRESENTING CLINICAL SIGNS

Elevated ALT enzyme. No symptoms. Denamarin 1/4 chew SID

Abnormal PE/Chem/CBC/UA Results: ALT: 3/11/26 159, 3/23 216, 4/20 289. ALP 4/20 18

ULTRASONOGRAPHIC EXAMINATION OF THE ABDOMEN

Urinary System

The **urinary bladder**, trigone, and pelvic urethra to a depth of 2.0 cm presented normal thicknesses and normal tone. The ureters were not visible which is normal. No uroliths or sediment were visualized, and anechoic urine was present. No evidence of inflammatory or neoplastic changes were noted. Ureteral papillae were normal.

The **kidneys** revealed normal size and structure, corticomedullary definition and ratio for this age. The cortices presented largely uniform texture with normal echogenic relationship to liver and spleen. Medullary structure differed distinctly from the cortex and no evidence of pelvic dilation was present. The capsules were acceptably uniform without significant irregularities. The left kidney measured 3.04 cm in length. The right kidney measured 2.7 cm in length.

Adrenal Glands

Both **adrenal glands** were visualized and recognized as having normal shape, size, position and echogenicity for this breed. The phrenic vasculature, glandular echogenicity and detail were unremarkable. Capsule, cortex, and medullary definition were normal for this age patient. The left adrenal gland measured 0.30 cm width. The right adrenal gland measured 1.12 cm x 0.33 cm width at the caudal pole and 0.61 cm width at the cranial pole.

Spleen

The **spleen** presented a smooth homogeneous parenchyma hyperechoic to liver and renal cortical parenchyma. The capsule was smooth without noticeable expansion or deviation from within the spleen or adjacent pathology. The splenic vasculature demonstrated normal volume without signs of congestion or thrombosis. No sonographic evidence of acute or chronic inflammatory, neoplastic, or infarctual changes were noted. The spleen was folded upon itself cranially.

Liver

The **liver** images submitted revealed subjectively normal liver size, contour, and structure. Parenchymal echogenicity was naturally coarse and hypoechoic to the spleen. Vascular and biliary tracts were of normal volume with no evidence of congestion. The gallbladder presented acceptably thin walls with primarily anechoic content. The cystic and common bile ducts were normal. No pathological hepatic lymphadenopathy was evident. No overt structural evidence of inflammatory, infiltrative or regenerative pathology was evident. The portal vein / vena cava ratio was 1:1. No evidence of portosystemic shunting.

Gastrointestinal

There was some residual chyme and gas was noted in the **stomach**, yet not pathological. This is consistent with end post prandial presentation. Transit of chyme into the small intestine was normal. Curvilinear patterns were maintained throughout the GI tract. No evidence of pathology. Small and



PATIENT

Malibu Kelly

SPECIES

Canine

BREED

Chihuahua

SEX

Spayed Female

AGE

2 Years 2 Months

WEIGHT

7.4 pounds

INTERPRETED BY

Eric Lindquist, DMV,
DABVP(CFM), Cert.
IVUSS

IMAGING PERFORMED BY

Chloe Lowe CVT

HOSPITAL NAME

Denville Animal
Hospital

REFERRING VET

Dr. Reddy

INVOICE

15354

DATE

04/23/26

large intestine demonstrated normal luminal chyme and stool consistency respectively. No obstructive or overt infiltrative disease was noted. No associated abnormal lymphatic activity was noted.

Pancreas

The right **pancreas** base presented slightly heterogenous with hypoechoic parenchyma.

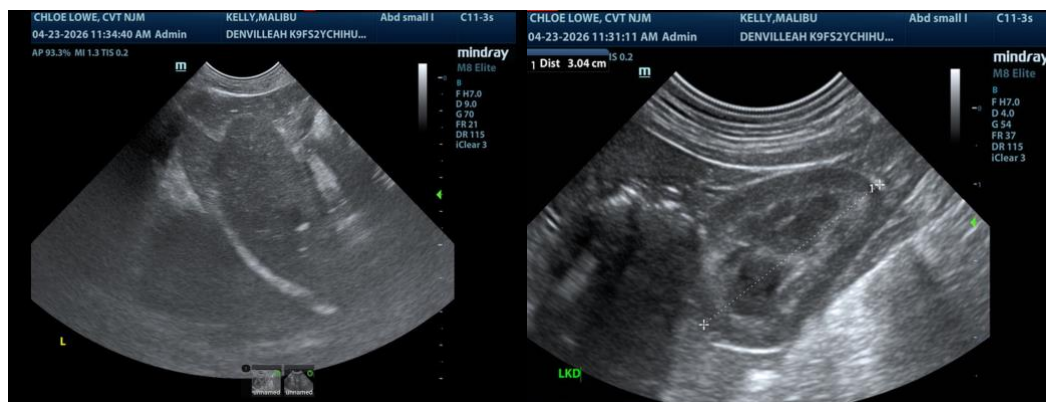
ULTRASONOGRAPHIC FINDINGS

- Minor heterogenous right pancreatic base.
- Structurally normal liver- likely reactive hepatopathy or low-grade inflammatory hepatopathy.
- Folded spleen.

INTERPRETATION OF THE FINDINGS & FURTHER RECOMMENDATIONS

Some level of low-grade pancreatitis is possible. Subxiphoid palpation is recommended to assess if there is any pain or discomfort.

The hepatic clinical sonographic presentation is most consistent with Reactive Hepatopathy which is the most common cause of liver enzyme elevation in dogs and cats. The presumption is that gut and other organ antigen stimuli may be causing a low-grade immune response through portal system with which the liver is reacting to causing low-grade enzyme elevations. US-guided FNA could be performed to assess if low grade lymphoplasmacytic inflammation is present that would support this theory. If FNA is performed, please ask the cytologist to emphasize the primary inflammatory cell type. Empirical treatment measures to address this issue can include diet change to hydrolyzed diet, probiotics, deworming, nutraceuticals (SAME, Actigall...), dental exam and cleaning, and potentially antibiotics such as Clavamox. Metronidazole and Tylosin have traditionally been utilized for this purpose but new studies show that both these antibiotics can disrupt the normal intestinal bacterial flora (intestinal dysbiosis) for weeks and up to 4-6 months. Therefore, Metronidazole and Tylosin should be utilized as a last resort if other efforts have not been effective and sonographic organ appearance remains benign.





PATIENT

Malibu Kelly

SPECIES

Canine

BREED

Chihuahua

SEX

Spayed Female

AGE

2 Years 2 Months

WEIGHT

7.4 pounds

INTERPRETED BY

Eric Lindquist, DMV,
 DABVP(CFM), Cert.
 IVUSS

IMAGING PERFORMED BY

Chloe Lowe CVT

HOSPITAL NAME

Denville Animal
 Hospital

REFERRING VET

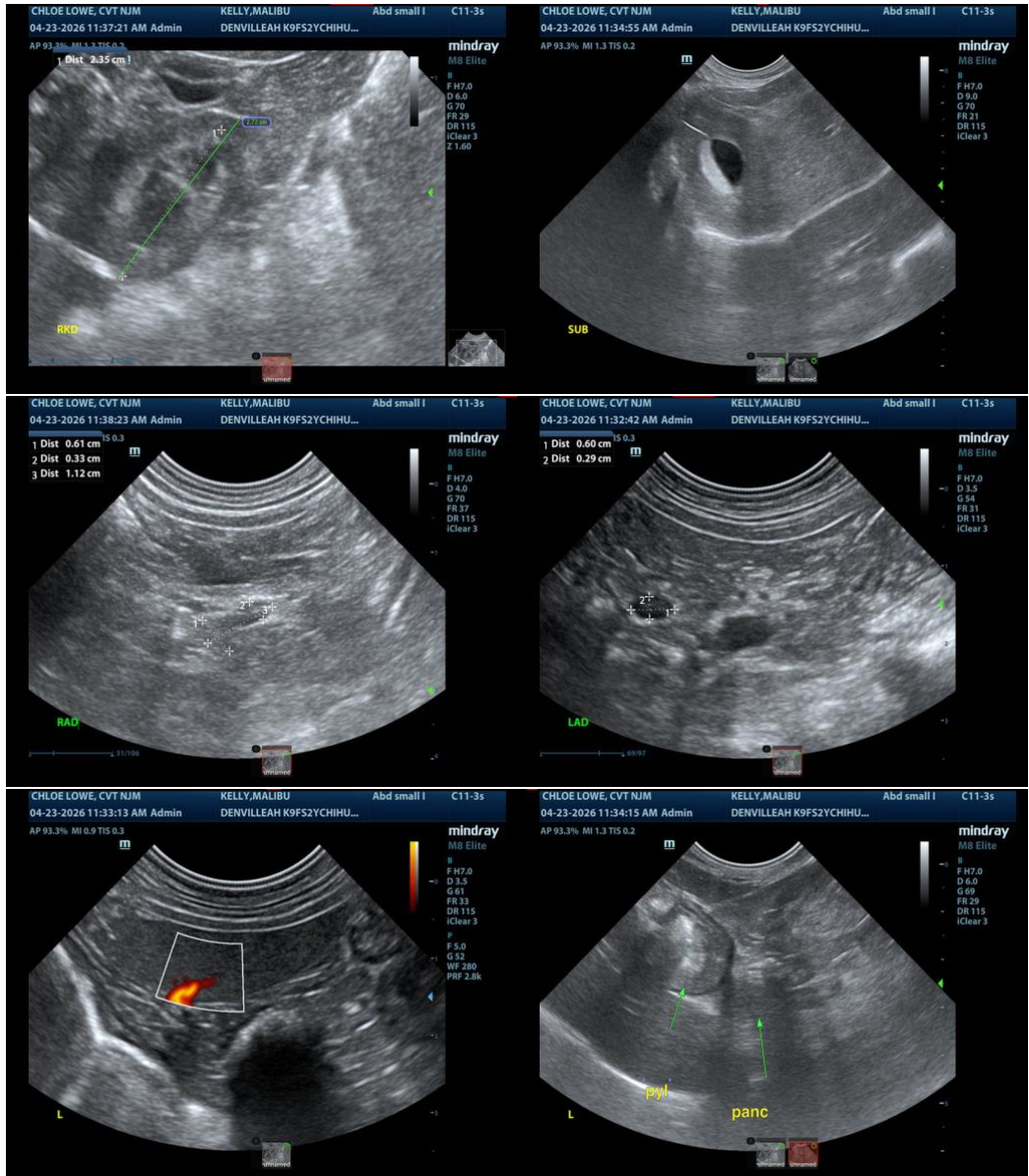
Dr. Reddy

INVOICE

15354

DATE

04/23/26



The information and recommendations provided are based on the images presented by the referring veterinarian/sonographer. No evaluation can be communicated regarding pathology that was not visible in the image/video clips provided.

Thank you for this referral. If the clinical or image interpretation does not parallel your findings or if I can be of any further assistance, please contact me.

Eric Lindquist, DMV, DABVP(CFM), Cert. IVUSS,

CEO, Owner, Founder -- SonoPath.com

info@SonoPath.com



PATIENT

Malibu Kelly

SPECIES

Canine

BREED

Chihuahua

SEX

Spayed Female

AGE

2 Years 2 Months

WEIGHT

7.4 pounds

INTERPRETED BY

Eric Lindquist, DMV,
DABVP(CFM), Cert.
IVUSS

**IMAGING
PERFORMED BY**

Chloe Lowe CVT

HOSPITAL NAME

Denville Animal
Hospital

REFERRING VET

Dr. Reddy

INVOICE

15354

DATE

04/23/26