



## PATIENT

Loki Raymond

## SPECIES

Canine

## BREED

Yorkshire Terrier

## SEX

Neutered Male

## AGE

5 Years

## WEIGHT

14.9 Pounds

## INTERPRETED BY

Eric Lindquist, DMV,  
DABVP(CFM), Cert.  
IVUSS

## IMAGING PERFORMED BY

Kathleen Laux

## HOSPITAL NAME

Rondout Valley VA

## REFERRING VET

Dr. Eric Hartelius

## INVOICE

35709

## DATE

4/23/26

## PRESENTING CLINICAL SIGNS

History: one organ US follow up on pancreas, was doing better for a couple days and now back to fever and vomiting

## LIMITED ULTRASONOGRAPHIC EXAMINATION

The pancreas in this patient revealed persistent hypoechoic areas in the right base, measuring approximately 2.0 cm with hyperechoic surrounding fat.

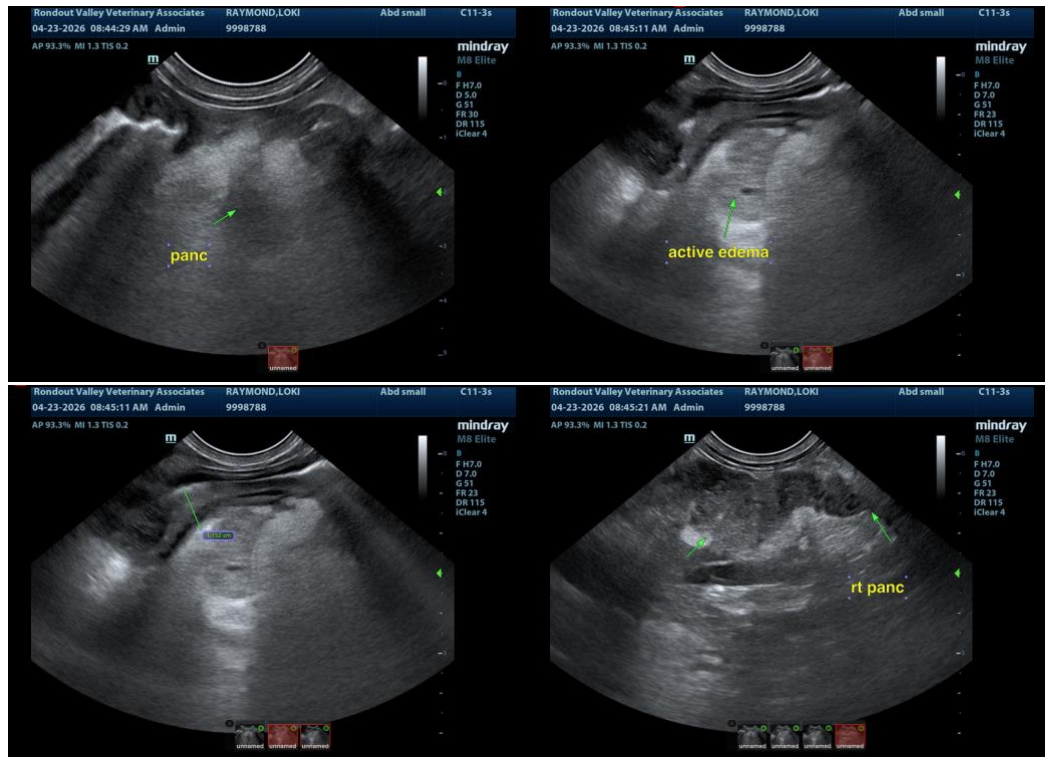
The stomach itself was unremarkable. Some duodenal thickening and spasming was noted. Duodenal wall thickness measured 1.1 cm. Variable areas of swollen irregular parenchyma with tissue organization were noted. No evidence of abscessation or free fluid. The colon was unremarkable.

## ULTRASONOGRAPHIC FINDINGS

- Persistent extensive pancreatitis with duodenal spasming

## INTERPRETATION OF THE FINDINGS & FURTHER RECOMMENDATIONS

Recommend continuation of intensive care with slurry feeding. Plasma expanders, pain management, broad-spectrum antibiotics, and GI protectants are all indicated. Recheck sonogram in 3 days. I recommend at least another 2-3 days of hospitalization and recheck sonogram at that time, as there is still potential for development of post-hepatic obstruction, necrosis and abscessation.





## PATIENT

Loki Raymond

## SPECIES

Canine

## BREED

Yorkshire Terrier

## SEX

Neutered Male

## AGE

5 Years

## WEIGHT

14.9 Pounds

## INTERPRETED BY

Eric Lindquist, DMV,  
DABVP(CFM), Cert.  
IVUSS

## IMAGING PERFORMED BY

Kathleen Laux

## HOSPITAL NAME

Rondout Valley VA

## REFERRING VET

Dr. Eric Hartelius

## INVOICE

35709

## DATE

4/23/26

The information and recommendations provided are based on the images presented by the referring veterinarian/sonographer. No evaluation can be communicated regarding pathology that was not visible in the image/video clips provided.

Thank you for this referral. If the clinical or image interpretation does not parallel your findings or if I can be of any further assistance please contact me.

**Eric Lindquist**, DMV, DABVP(CFM), Cert. IVUSS,  
CEO, Owner, Founder -- SonoPath.com  
[info@SonoPath.com](mailto:info@SonoPath.com)