



PATIENT

Lily Martin

SPECIES

Canine

BREED

Shih Tzu

SEX

Spayed Female

AGE

3 Years

WEIGHT

12.5 pounds

INTERPRETED BY

Eric Lindquist, DMV,
DABVP(CFM), Cert.
IVUSS

IMAGING PERFORMED BY

Dr. Gudrun Gunther

HOSPITAL NAME

New Frontier Animal
Medical Center

REFERRING VET

Dr. Gudrun Gunther

INVOICE

15351

DATE

04/23/26

PRESENTING CLINICAL SIGNS

Came in for AUS due to concern about GI f.b. O thought she swallowed a bottle cap about 24 hours ago.

Patient has vomited once and is mildly hyporexic otherwise acting normally

ULTRASONOGRAPHIC EXAMINATION OF THE ABDOMEN

Urinary System

The **urinary bladder**, trigone, and pelvic urethra to a depth of 2.0 cm presented normal thicknesses and normal tone. The ureters were not visible which is normal. No uroliths or sediment were visualized, and anechoic urine was present. No evidence of inflammatory or neoplastic changes were noted. Ureteral papillae were normal.

The **left kidney** revealed normal size and structure, corticomedullary definition and ratio for this age. The cortices presented largely uniform texture with normal echogenic relationship to liver and spleen. Medullary structure differed distinctly from the cortex and no evidence of pelvic dilation was present. The capsules were acceptably uniform without significant irregularities. The left kidney measured 3.88 cm in length.

The **right kidney** appears slightly subnormal in size with loss of corticomedullary definition. The right kidney measured 3.28 cm in length. Some level of right renal dysplasia may be present.

Adrenal Glands

Both **adrenal glands** were visualized and recognized as having normal shape, size, position and echogenicity for this breed. The phrenic vasculature, glandular echogenicity and detail were unremarkable. Capsule, cortex, and medullary definition were normal for this age patient. The left adrenal gland measured 1.4 cm x 0.33 cm width at the caudal pole and 0.29 cm width at the cranial pole. The right adrenal gland measured 1.53 cm x 1.07 cm width at the cranial pole and 0.35 cm width at the caudal pole.

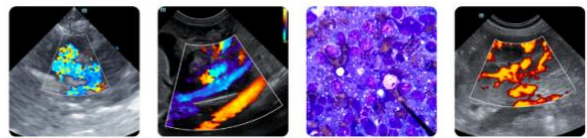
Spleen

The **spleen** presented a smooth homogeneous parenchyma hyperechoic to liver and renal cortical parenchyma. The capsule was smooth without noticeable expansion or deviation from within the spleen or adjacent pathology. The splenic vasculature demonstrated normal volume without signs of congestion or thrombosis. No sonographic evidence of acute or chronic inflammatory, neoplastic, or infarctual changes were noted.

Liver

The **liver** images submitted revealed subjectively normal liver size, contour, and structure. Parenchymal echogenicity was naturally coarse and hypoechoic to the spleen. Vascular and biliary tracts were of normal volume with no evidence of congestion. The gallbladder presented acceptably thin walls with primarily anechoic content. The cystic and common bile ducts were normal. No pathological hepatic lymphadenopathy was evident. No overt structural evidence of inflammatory, infiltrative or regenerative pathology was evident.

Gastrointestinal



PATIENT

Lily Martin

SPECIES

Canine

BREED

Shih Tzu

SEX

Spayed Female

AGE

3 Years

WEIGHT

12.5 pounds

INTERPRETED BY

Eric Lindquist, DMV,
DABVP(CFM), Cert.
IVUSS

IMAGING PERFORMED BY

Dr. Gudrun Gunther

HOSPITAL NAME

New Frontier Animal
Medical Center

REFERRING VET

Dr. Gudrun Gunther

INVOICE

15351

DATE

04/23/26

The **stomach** revealed a fluid-filled lumen and echogenic mucosal changes in one view. The small intestine and colon were unremarkable.

Pancreas

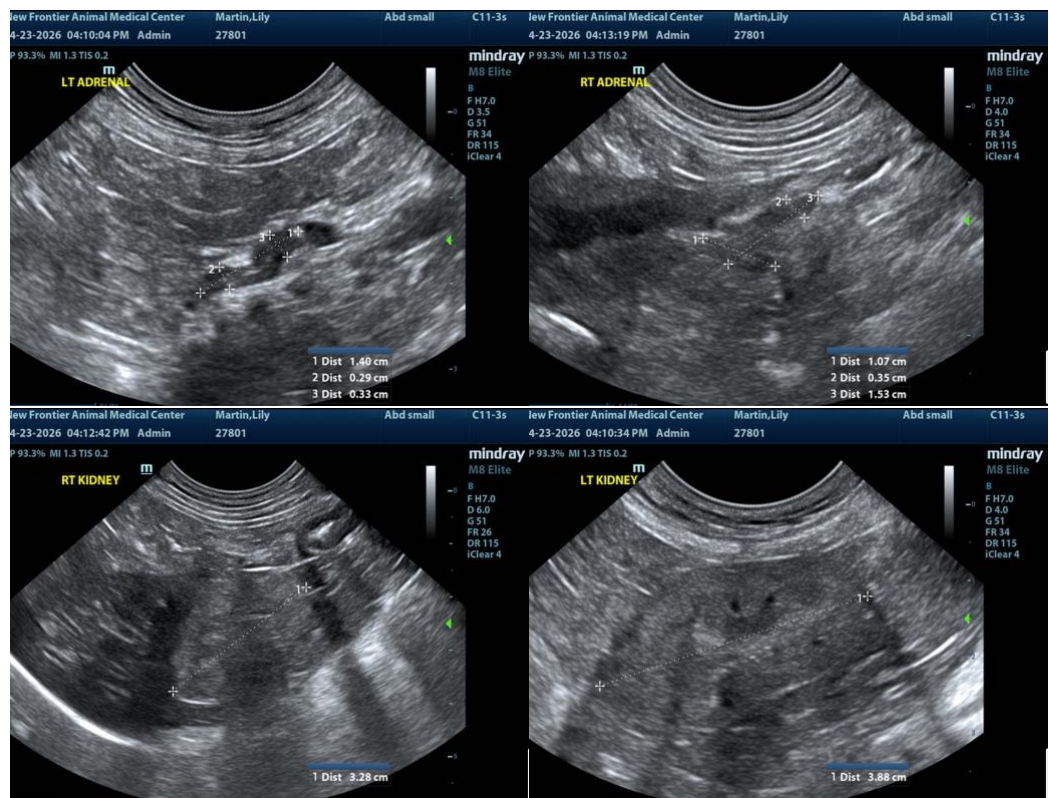
The base and limbs of the **pancreas** were observed to be largely isoechoic to surrounding omental fat. Pancreatic duct and capsular contour were acceptably normal and parenchyma respected normal curvilinear patterns. No overt evidence of active inflammatory or neoplastic disease was noted.

ULTRASONOGRAPHIC FINDINGS

- Mildly dysplastic right kidney, normal left kidney.
- Mild gastritis pattern.

INTERPRETATION OF THE FINDINGS & FURTHER RECOMMENDATIONS

Cannot rule out ulcerative disease, yet changes were minor. No evidence of foreign bodies. GI protective protocol should prove effective.





PATIENT

Lily Martin

SPECIES

Canine

BREED

Shih Tzu

SEX

Spayed Female

AGE

3 Years

WEIGHT

12.5 pounds

INTERPRETED BY

Eric Lindquist, DMV,
DABVP(CFM), Cert.
IVUSS

IMAGING PERFORMED BY

Dr. Gudrun Gunther

HOSPITAL NAME

New Frontier Animal
Medical Center

REFERRING VET

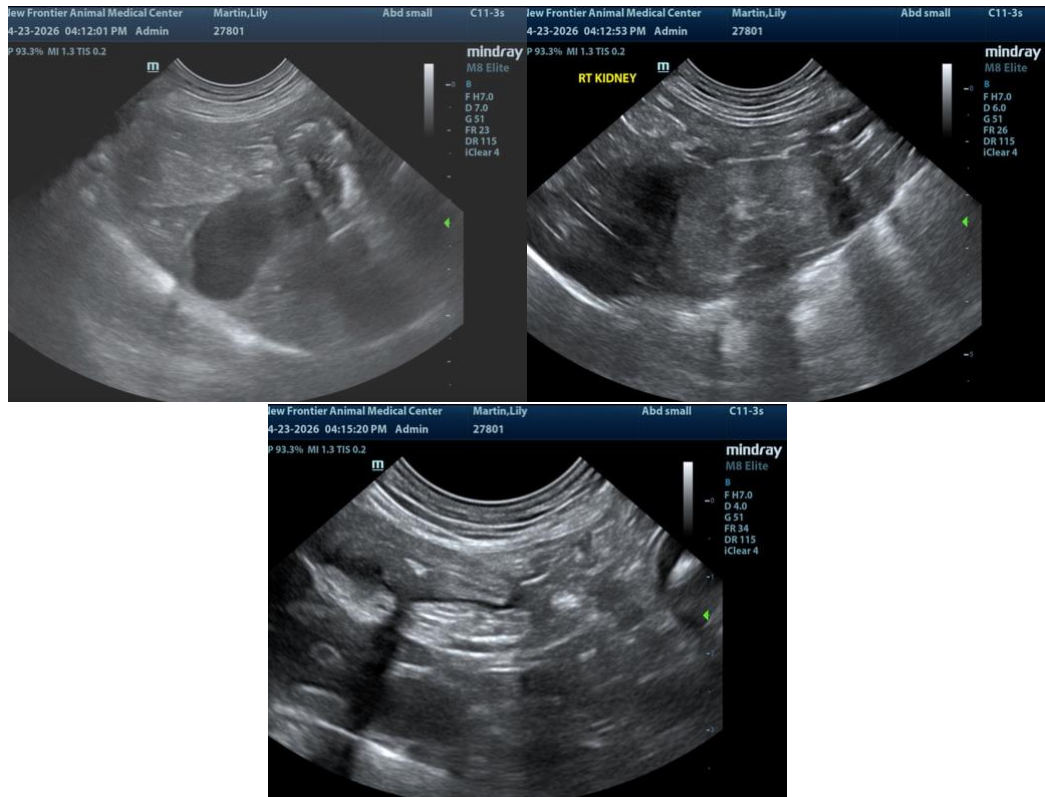
Dr. Gudrun Gunther

INVOICE

15351

DATE

04/23/26



The information and recommendations provided are based on the images presented by the referring veterinarian/sonographer. No evaluation can be communicated regarding pathology that was not visible in the image/video clips provided.

Thank you for this referral. If the clinical or image interpretation does not parallel your findings or if I can be of any further assistance, please contact me.

Eric Lindquist, DMV, DABVP(CFM), Cert. IVUSS,

CEO, Owner, Founder -- SonoPath.com

info@SonoPath.com