

PATIENT

Doki Garzia

SPECIES

Canine

BREED

Shih Tzu

SEX

Male

AGE

14 Years

WEIGHT

4.9 kg

INTERPRETED BY

Eric Lindquist, DMV,
DABVP (Canine &
Feline), Cert. IVUSS

IMAGING PERFORMED BY

Dr. Samad Khan

HOSPITAL NAME

The Veterinary Sugery-
Street 805

REFERRING VET

Dr. Samad Khan

INVOICE

36711

DATE

4/23/26

PRESENTING CLINICAL SIGNS

History: Heart murmur need anesth safety

ULTRASONOGRAPHIC EXAMINATION OF THE HEART

CANINE CARDIAC PARAMETERS	MR VMAX (m/s)	TR VMAX (m/s)	LA/AO (M-Mode)	LA/AO (Heart Base; Swe)	FS (%)	EF (%)	EPSS (cm)
NORMAL PARAMETER	4.5-5.5	<2.7	1.3	Up to 1.6	28-40	40-100	<0.6
PATIENT	--	--	1.0	~0.9	~40	--	0.1
CANINE CARDIAC PARAMETERS	HR (BPM)	AV VMAX (m/s)	PV MAX (m/s)	BODY WEIGHT (kg)	LAD LA MAX 4 Chamber	LVIDd Avg; 2D and m-mode short axis (cm)	LVIDs Avg; 2D and m-mode short axis (cm)
NORMAL PARAMETER	50-100	0.7-1.7	0.7-1.6				
PATIENT	Vari/80	--	--	4.9	2.1	2.2	--

Cardiac Presentation

Multiple video clips were submitted of the heart did not reveal any volume overload. Mild left ventricular hypertrophy was noted. Mitral valve was thickened; this is presumed to be the source of the murmur. Left atrial size was normal to subnormal. Hydration status and blood pressure should be monitored in this patient. Mitral insufficiency was demonstrated on colorflow doppler. Right atrium and right ventricle were unremarkable. No pericardial effusion was noted. Arrhythmogenic activity was noted in this patient.

ULTRASONOGRAPHIC FINDINGS

- Compensated valvular disease, stage B-1

INTERPRETATION OF THE FINDINGS & FURTHER RECOMMENDATIONS

EKG is indicated. Serial blood pressures are recommended to ensure hypertension is not an issue, however, structurally and functionally there is no overt contraindication anesthetic procedure in this patient, as there is no evidence of volume overload, nor pressure overload.

The heart is stable without clinical disease. No overt contraindication for anesthesia of brief to moderate duration. I suggest Torbutrol premed, Propofol induction, Isoflo maintenance or similar protocol if anesthesia is desired. Blood pressure recommended if not already performed and target



PATIENT

Doki Garzia

SPECIES

Canine

BREED

Shih Tzu

SEX

Male

AGE

14 Years

WEIGHT

4.9 kg

INTERPRETED BY

Eric Lindquist, DMV,
DABVP (Canine &
Feline), Cert. IVUSS

IMAGING PERFORMED BY

Dr. Samad Khan

HOSPITAL NAME

The Veterinary Sugery-
Street 805

REFERRING VET

Dr. Samad Khan

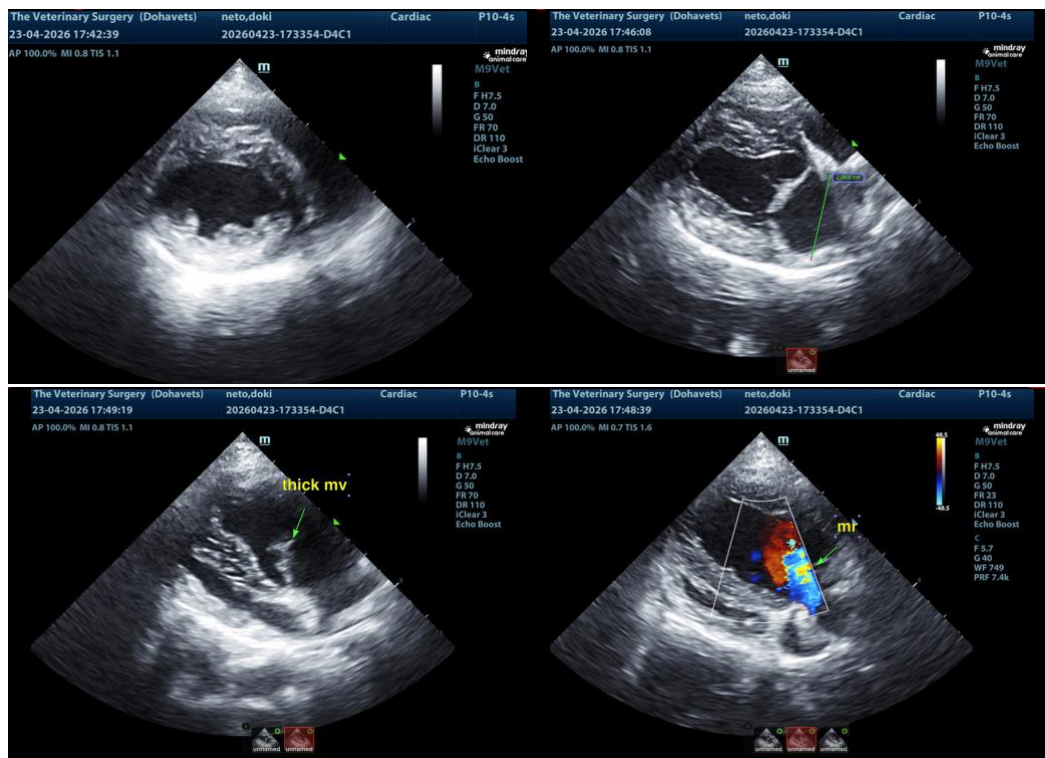
INVOICE

36711

DATE

4/23/26

white coat negative systolic pressure of < 160 mmHg. If higher than this ACE-inhibitor is suggested to reach this level. Recheck echocardiogram is recommended in 6 months, earlier if murmur grade increases or clinical signs initiate.



The information and recommendations provided are based on the images presented by the referring veterinarian/sonographer. No evaluation can be communicated regarding pathology that was not visible in the image/video clips provided.

Thank you for this referral. If the clinical or image interpretation does not parallel your findings or if I can be of any further assistance please contact me.

Eric Lindquist, DMV, DABVP(CFM), Cert. IVUSS,
CEO, Owner, Founder -- SonoPath.com
info@SonoPath.com