



DATE

4/23/23

PATIENT

Sandy Matos

SPECIES

Canine

BREED

Dachshund

SEX

Spayed Female

AGE

2013

WEIGHT

9.6 Pounds

INTERPRETED BY

Eric Lindquist, DMV
DABVP, Cert. IVUSS

HOSPITAL NAME

Animal Emergency
Hospital

REFERRING VET

Dr. King

INVOICE

46884

PRESENTING CLINICAL SIGNS

Presenting Complaint: Fell down stairs. Vomiting. Lethargic.
History: Date: 04-23-2023 Notes: Acute onset of falling down a couple stairs. Shifting leg lameness in hind legs, but seemed lethargic. Vomited some fluid tonight - remains lethargic. No changes in diet or abnormal ingestions.

Assessment: AFAST/TFAST - no ff seen.

Lab Results: Attached.

Radiographs: Xray Abdomen 2 View: splenomegaly. Ingesta-- moderate amount ingesta in the stomach

Date of Previous IntraPet Ultrasound: No previous.

Sedation: Not required to complete full diagnostic ultrasound.

Stat Report: Not requested.

Imaging Performed By: Rachel Brillhart, RDMS.

ULTRASONOGRAPHIC EXAMINATION OF THE ABDOMEN

Urinary System

The **urinary bladder**, trigone, and pelvic urethra presented normal thicknesses and normal tone. The ureters were not visible which is normal. No uroliths or sediment were visualized and anechoic urine was present. No evidence of inflammatory or neoplastic changes were noted. Ureteral papillae were normal.

The **kidneys** revealed normal size and structure, corticomedullary definition and ratio for this age. The cortices presented largely uniform texture with normal echogenic relationship to liver and spleen. Medullary structure differed distinctly from the cortex and no evidence of pelvic dilation was present. The capsules were acceptably uniform without significant irregularities. The left kidney measured 4.17 cm. An expansive hypoechoic nodule was noted in the cranial pole measuring 1.55 cm x 0.77 cm. The right kidney measured 3.87 cm.

Adrenal Glands

Both **adrenal glands** were visualized and recognized as having normal shape, size, position and echogenicity for this breed. The phrenic vasculature, glandular echogenicity and detail were unremarkable. Capsule, cortex, and medullary definition were normal for this age patient. The left adrenal gland measured 1.95 cm x 0.70 cm at the caudal pole and 0.59 cm at the cranial pole. The right adrenal gland measured 1.73 cm x 0.74 cm at the caudal pole and 0.67 cm at the cranial pole.

Spleen

The **spleen** presented a smooth homogeneous parenchyma hyperechoic to liver and renal cortical parenchyma. The spleen was folded upon itself caudally. The capsule was smooth without noticeable expansion or deviation from within the spleen or adjacent pathology. The splenic vasculature demonstrated normal volume without signs of congestion or thrombosis. No sonographic evidence of acute or chronic inflammatory, neoplastic, or infarctual changes were noted. No evidence of splenic torsion.

Liver

The **liver** images submitted revealed subjectively normal liver size, contour, and structure. Parenchymal echogenicity was naturally coarse and hypoechoic to the spleen. Vascular and biliary tracts were of normal

volume with no evidence of congestion. The gallbladder presented acceptably thin walls with primarily anechoic content. The cystic and common bile ducts were normal. No pathological hepatic lymphadenopathy was evident. No overt structural evidence of inflammatory, infiltrative or regenerative pathology was evident.

Gastrointestinal

The **stomach** was overdistended with echogenic chyme. The pylorus was patent. The small intestine and colon were unremarkable. Some minor transit of chyme appeared to be occurring. |

Pancreas

The base and limbs of the **pancreas** were observed to be largely isoechoic to surrounding omental fat. Pancreatic duct and capsular contour were acceptably normal and parenchyma respected normal curvilinear patterns. No overt evidence of active inflammatory or neoplastic disease was noted.

Free Abdomen

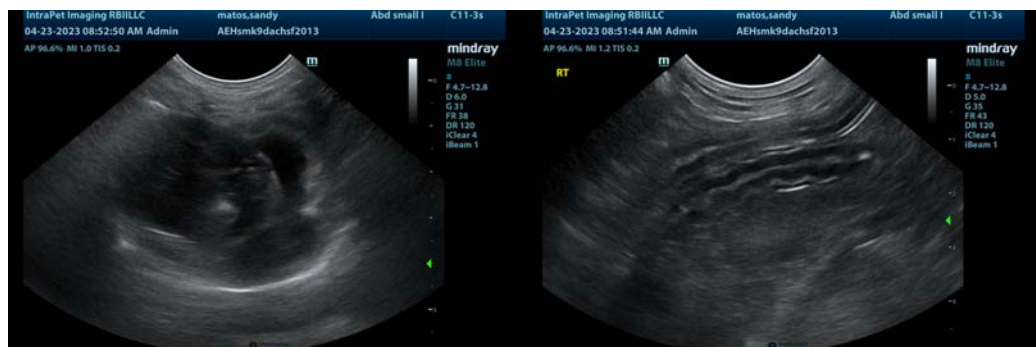
Rapid view of the heart revealed no evident pathology. Right auricle, pericardium, and contractility appeared adequate.

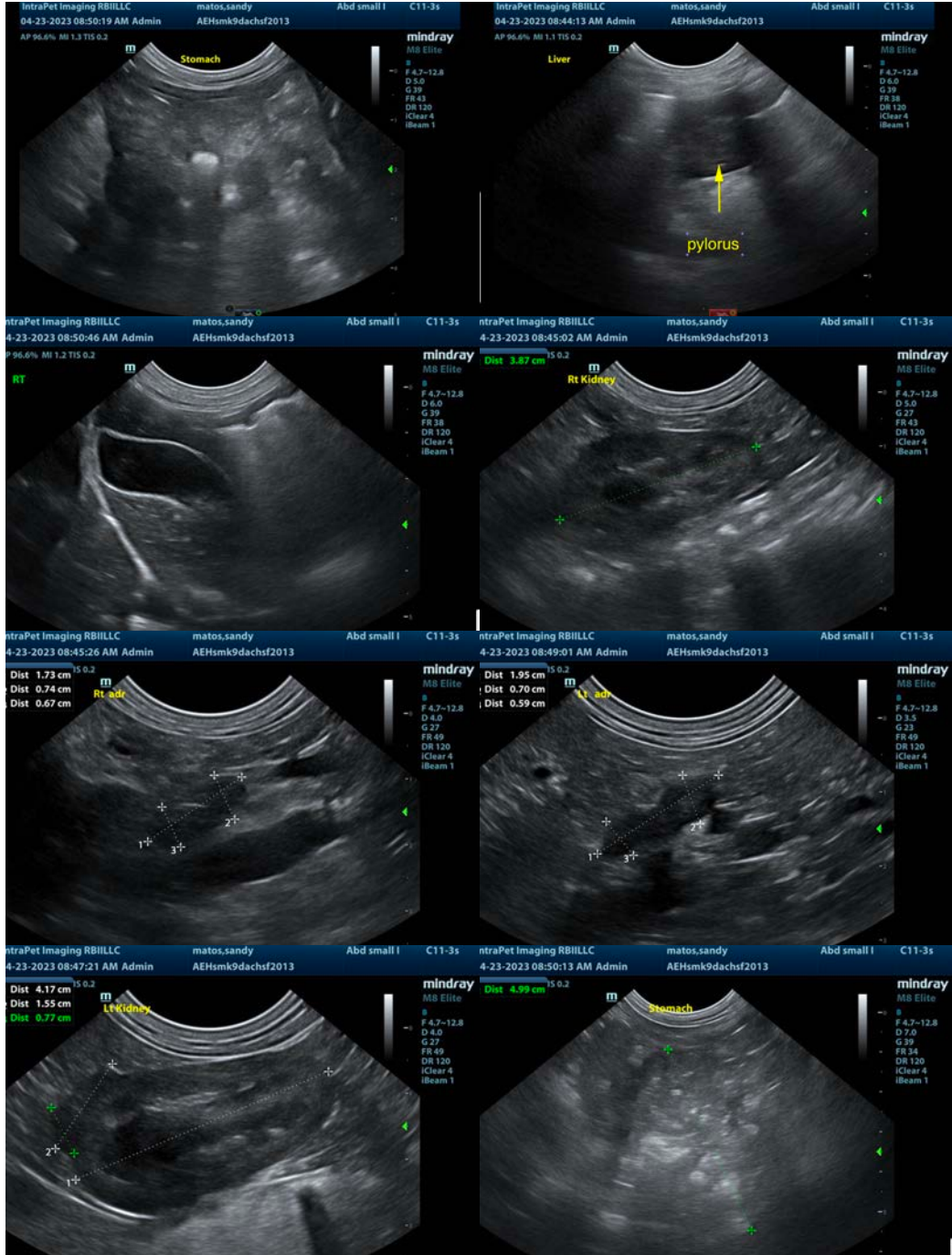
ULTRASONOGRAPHIC FINDINGS

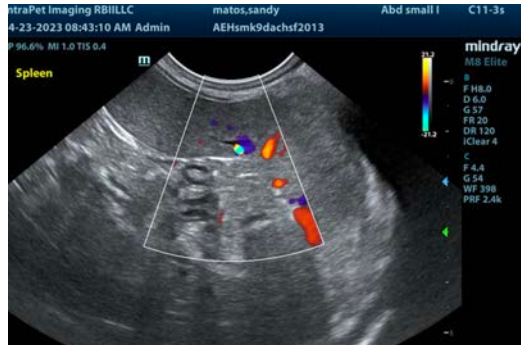
- Slightly irregular cranial pole of the left kidney – possible normal variant versus emerging neoplasia.
- Gastric stasis/bloat pattern, no overt evidence of foreign body. Delayed outflow pattern.
- Folded spleen, yet likely owing to gastric overdistention.

INTERPRETATION OF THE FINDINGS & FURTHER RECOMMENDATIONS

Recommend 24-hour NPO, GI protectants, IV fluid support, and reassessment of the sonogram, primarily the upper GI tract. Full CNS examination as well as orthopedic examination warranted to assess for other causes of the clinical history. The vomiting may be secondary owing to post-prandial presentation combined with a neurological or orthopedic incident.







The information and recommendations provided are based on the images presented by the referring veterinarian/sonographer. No evaluation can be communicated regarding pathology that was not visible in the image/video clips provided.

Thank you for this referral. If the clinical or image interpretation does not parallel your findings or if I can be of any further assistance please contact me.

Eric Lindquist, DMV, DABVP, Cert. IVUSS, CEO of SonoPath.com
info@SonoPath.com