

**PATIENT**

Nipsey Taylor

**SPECIES**

Canine

**BREED**

French Bulldog

**SEX**

Intact Male

**AGE**

3 Years

**WEIGHT**

31.4 Pounds

**INTERPRETED BY**

Eric Lindquist, DMV  
DABVP, Cert. IVUSS

**IMAGING  
PERFORMED BY**

Destiney Dinsman, LVT

**HOSPITAL NAME**

Animage Mobile VU

**REFERRING VET**

Amy R. Bossung, DVM  
Cert IVUSS

**INVOICE**

14863

**DATE**

4/23/22

**PRESENTING CLINICAL SIGNS**

History: P has chronic hx of ALT elevation. P has been e/d/u/d all wnl and had no c/s/v/d. O states that P has been taking the Denamarin as directed however didn't like the liquid formulation at all and would just spit it back out each time, so O had to break up the chewable tablets everyday for P to actually receive the medication. (Had GG Pharmacy compound Denamarin in liquid form for Nipsey). P has one episode of D+ noted historically (but after receiving pain meds for poss IVDD). Denamarin Advanced Small-Medium Canine Bottle (1 tab daily)

Abnormal PE/Chem/CBC/UA Results: 9/12/2020: ALT: 364 9/17/2021: Bile Acids: Pre: <1.0; Post: 6.5 9/16/2021: ALT: >2000 11/19/2021: ALT: >1000 3/4/2022: ALT: 1867 (diluted 1:2) 4/8/2022: ALT: 1858 (diluted 1:2)

**ULTRASONOGRAPHIC EXAMINATION OF THE ABDOMEN**

**Urinary System**

The **urinary bladder**, trigone, and pelvic urethra presented normal thicknesses and normal tone. The ureters were not visible which is normal. No uroliths or sediment were visualized, and anechoic urine was present. No evidence of inflammatory or neoplastic changes were noted. Ureteral papillae were normal.

The **kidneys** revealed normal size and structure, corticomedullary definition and ratio for this age. The cortices presented largely uniform texture with normal echogenic relationship to liver and spleen. Medullary structure differed distinctly from the cortex and no evidence of pelvic dilation was present. The capsules were acceptably uniform without significant irregularities. The left kidney measured 6.23 cm. The right kidney measured 5.56 cm.

**Adrenal Glands**

The **left adrenal gland** was visualized and recognized as having normal shape, size, position and echogenicity for this breed. The phrenic vasculature, glandular echogenicity and detail were unremarkable. Capsule, cortex, and medullary definition were normal for this age patient. The left adrenal gland measured 0.44 cm at the caudal pole and 0.53 cm at the cranial pole.

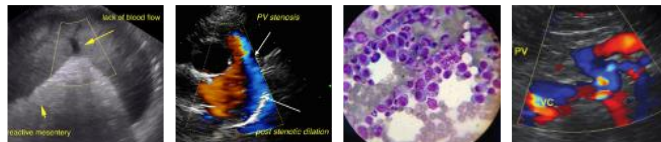
The **right adrenal gland** was not visualized.

**Spleen**

The **spleen** presented a smooth homogeneous parenchyma hyperechoic to liver and renal cortical parenchyma. The capsule was smooth without noticeable expansion or deviation from within the spleen or adjacent pathology. The splenic vasculature demonstrated normal volume without signs of congestion or thrombosis. No sonographic evidence of acute or chronic inflammatory, neoplastic, or infarctual changes were noted.

**Liver**

The **liver** images submitted revealed subjectively normal liver size, contour, and structure. Parenchymal echogenicity was naturally coarse and hypoechoic to the spleen. Vascular and biliary tracts were of normal volume with no evidence of congestion. The gallbladder presented acceptably thin walls with primarily anechoic content. The cystic and common bile ducts were normal. No pathological hepatic lymphadenopathy was evident. No overt structural evidence of inflammatory, infiltrative or regenerative pathology was evident.



**PATIENT**

**Gastrointestinal**

Nipsey Taylor

Examination of the **gastrointestinal tract** revealed a stomach and intestine free of stasis, of normal wall thickness, acceptable curvilinear mural detail, and peristaltic activity. Small and large intestine demonstrated normal luminal chyme and stool consistency respectively. No obstructive or overt infiltrative disease was noted. No associated abnormal lymphatic activity was noted.

**SPECIES**

Canine

**Pancreas**

**BREED**

French Bulldog

The base and limbs of the **pancreas** were observed to be largely isoechoic to surrounding omental fat. Pancreatic duct and capsular contour were acceptably normal and parenchyma respected normal curvilinear patterns. No overt evidence of active inflammatory or neoplastic disease was noted.

**SEX**

Intact Male

**ULTRASONOGRAPHIC FINDINGS**

- Structurally unremarkable abdomen

**AGE**

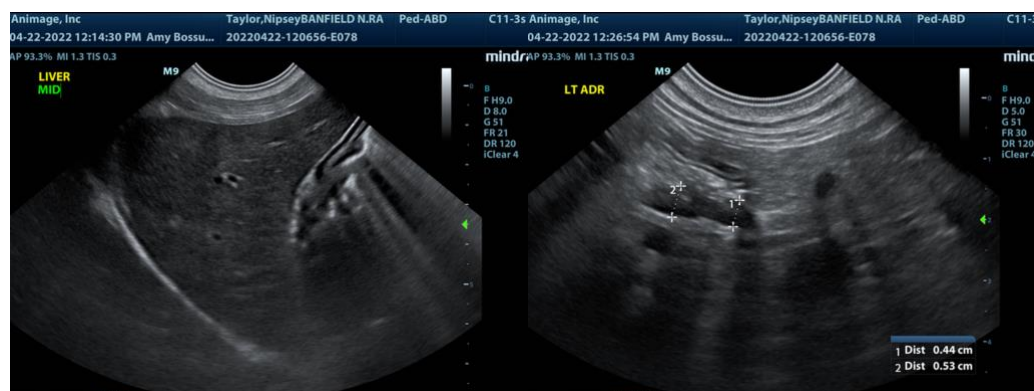
3 Years

**INTERPRETATION OF THE FINDINGS & FURTHER RECOMMENDATIONS**

Acute inflammatory hepatopathy, leptospirosis and other causes of acute insult should be considered, as structurally the liver appears unremarkable. FNA, coagulation panel, leptospirosis titers, ampicillin, metronidazole and nutraceuticals all indicated.

**WEIGHT**

31.4 Pounds



**INTERPRETED BY**

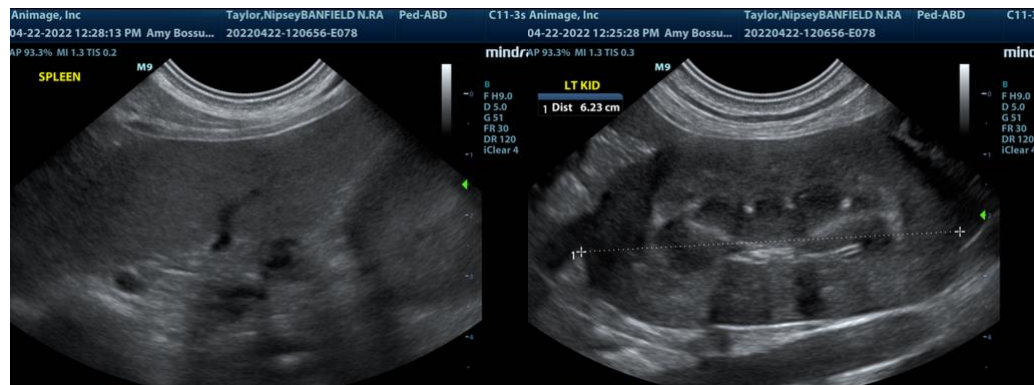
Eric Lindquist, DMV  
DABVP, Cert. IVUSS

**IMAGING PERFORMED BY**

Destiney Dinsman, LVT

**HOSPITAL NAME**

Animage Mobile VU



**REFERRING VET**

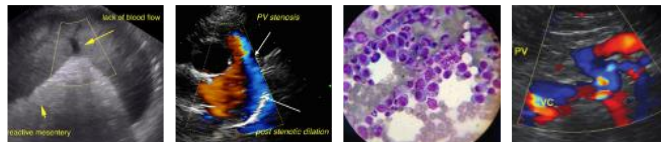
Amy R. Bossung, DVM  
Cert IVUSS

**INVOICE**

14863

**DATE**

4/23/22



**PATIENT**

Nipsey Taylor

**SPECIES**

Canine

**BREED**

French Bulldog

**SEX**

Intact Male

**AGE**

3 Years

**WEIGHT**

31.4 Pounds

**INTERPRETED BY**

Eric Lindquist, DMV  
DABVP, Cert. IVUSS

**IMAGING PERFORMED BY**

Destiney Dinsman, LVT

**HOSPITAL NAME**

Animage Mobile VU

**REFERRING VET**

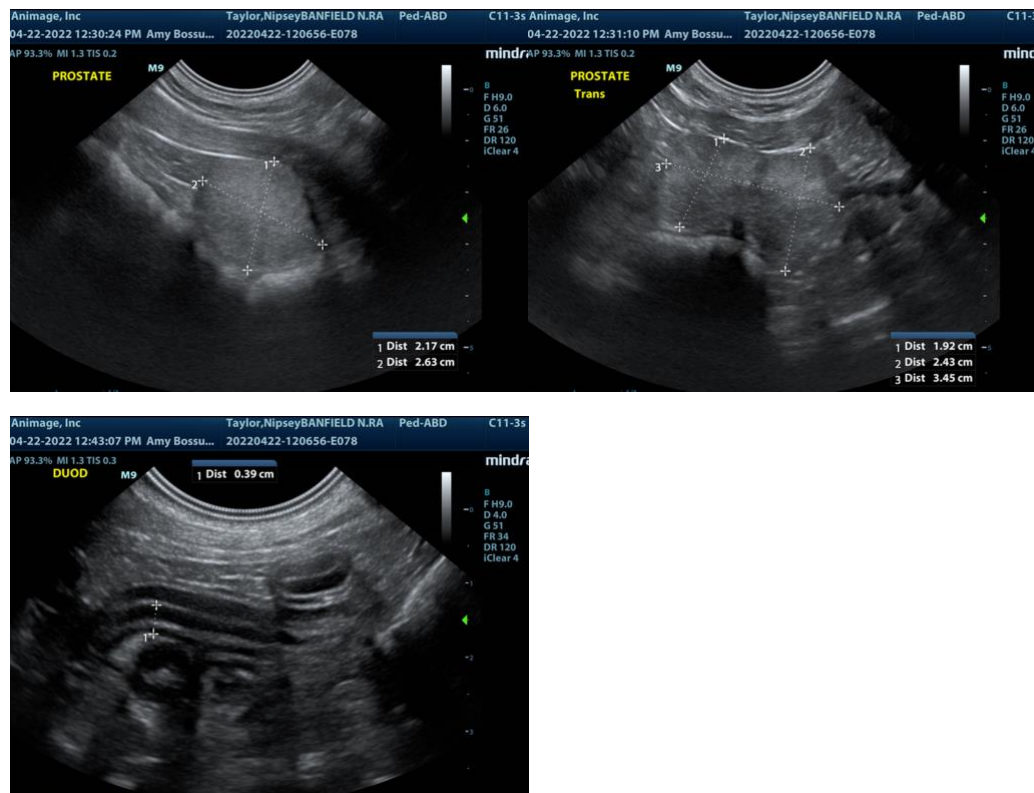
Amy R. Bossung, DVM  
Cert IVUSS

**INVOICE**

14863

**DATE**

4/23/22



The information and recommendations provided are based on the images presented by the referring veterinarian. No evaluation can be communicated regarding pathology that was not visible in the image/video clips provided.

Thank you for this referral. If the clinical or image interpretation does not parallel your findings or if I can be of any further assistance please contact me.

**Eric Lindquist**, DMV, DABVP, Cert. IVUSS, CEO of SonoPath.com  
info@SonoPath.com