



PATIENT

Sadie Feltz

SPECIES

Canine

BREED

King Charles Cavalier

SEX

Female

AGE

9 weeks

WEIGHT

6.06

INTERPRETED BY

Eric Lindquist, DMV,
DABVP(CFM), Cert.
IVUSS

IMAGING PERFORMED BY

Dr. Kendra Sims

HOSPITAL NAME

Perry Veterinary Clinic
PLLC

REFERRING VET

Dr. Kendra Sims

INVOICE

15359

DATE

04/22/26

PRESENTING CLINICAL SIGNS

rDVM heard murmur on puppy - dog has an elevated SRR and coughs after playing with other puppies. this puppy was brought in by the breeder, and they will be keeping the puppy - unsure if will pursue surgery/correction if PDA.

Abnormal PE/Chem/CBC/UA Results: grade IV loudest in left apical but not so much caudal on the left. grade II on right apical. butorphanol was given IM prior to exam - BP was 104/73.

ULTRASONOGRAPHIC EXAMINATION OF THE HEART

CANINE CARDIAC PARAMETERS	MR VMAX (m/s)	TR VMAX (m/s)	LA/AO (M-Mode)	LA/AO (Heart Base; Swe)	FS (%)	EF (%)	EPSS (cm)
NORMAL PARAMETER	4.5-5.5	<2.7	1.3	Up to 1.6	28-40	40-100	<0.6
PATIENT	--	--	1.4	2/0	45	--	0.2
CANINE CARDIAC PARAMETERS	HR (BPM)	AV VMAX (m/s)	PV MAX (m/s)	BODY WEIGHT	LAD LA MAX 4 Chamber	LVIDd Avg; 2D and m-mode short axis (cm)	LVIDs Avg; 2D and m-mode short axis (cm)
NORMAL PARAMETER	50-100	0.7-1.7	0.7-1.6				
PATIENT	120	--	--	6.06	2.7	2.5	--

Cardiac Presentation

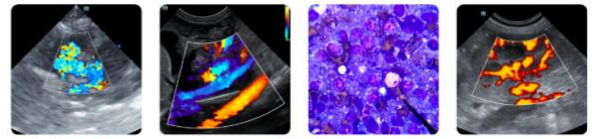
The left ventricle and left atrium presented with mild volume overload and adequate contractility. Mitral valve insufficiency was noted on color flow assessment. The right atrium, right ventricle and tricuspid valve were all unremarkable, however, the deep pulmonary artery revealed a holosystolic flow at the bifurcation. This is strongly consistent with Patent ductus Arteriosus (PDA).

ULTRASONOGRAPHIC FINDINGS

- Mild volume overload of the left atrium/left ventricle.
- Mitral valve insufficiency.

INTERPRETATION OF THE FINDINGS & FURTHER RECOMMENDATIONS

Strong suspicion for Patent ductus Arteriosus given the color flow pattern in the deep pulmonary artery. Cardiologist referral for Occluder treatment or surgical intervention is recommended.



PATIENT

Sadie Feltz

SPECIES

Canine

BREED

King Charles Cavalier

SEX

Female

AGE

9 weeks

WEIGHT

6.06

INTERPRETED BY

Eric Lindquist, DMV,
DABVP(CFM), Cert.
IVUSS

IMAGING PERFORMED BY

Dr. Kendra Sims

HOSPITAL NAME

Perry Veterinary Clinic
PLLC

REFERRING VET

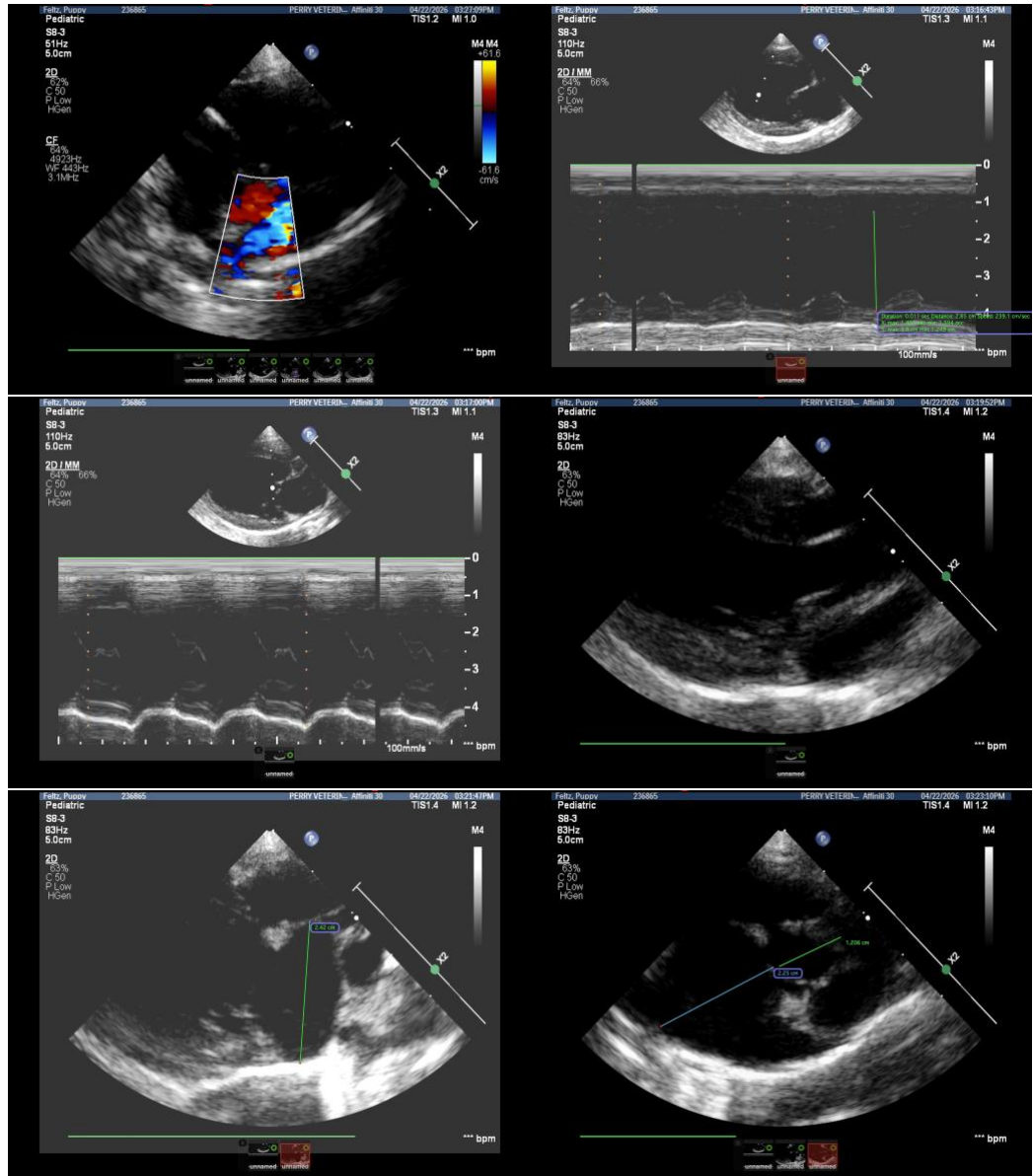
Dr. Kendra Sims

INVOICE

15359

DATE

04/22/26





PATIENT

Sadie Feltz

SPECIES

Canine

BREED

King Charles Cavalier

SEX

Female

AGE

9 weeks

WEIGHT

6.06

INTERPRETED BY

Eric Lindquist, DMV,
DABVP(CFM), Cert.
IVUSS

IMAGING PERFORMED BY

Dr. Kendra Sims

HOSPITAL NAME

Perry Veterinary Clinic
PLLC

REFERRING VET

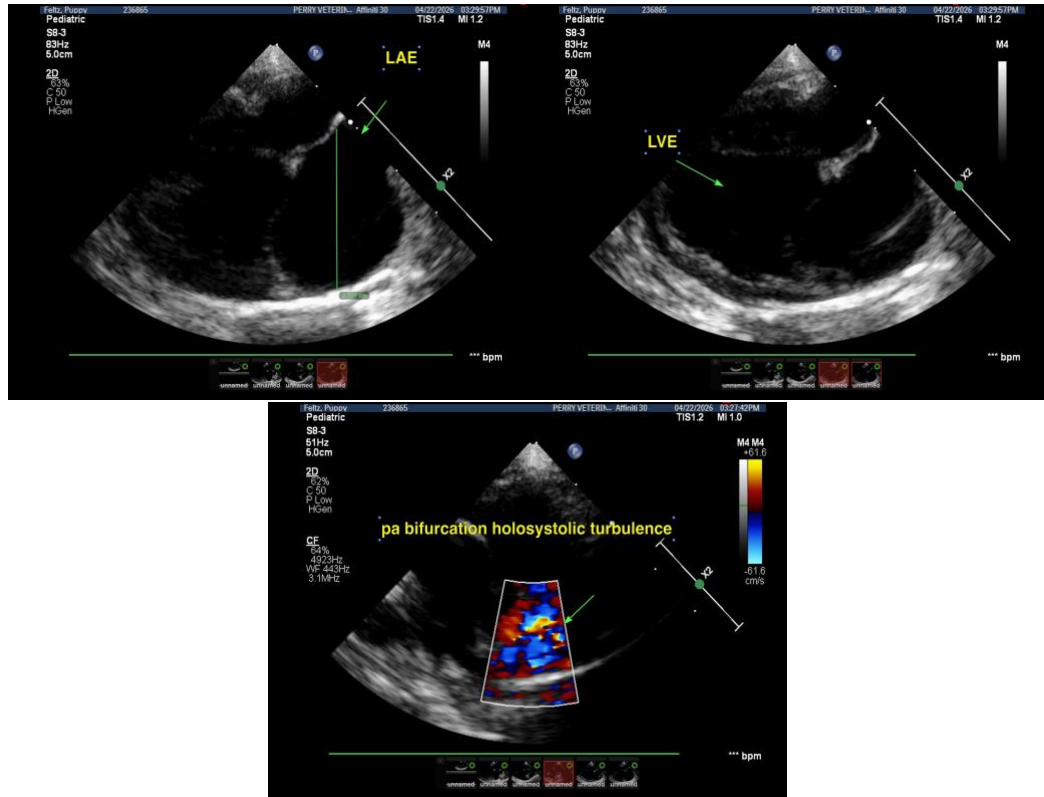
Dr. Kendra Sims

INVOICE

15359

DATE

04/22/26



The information and recommendations provided are based on the images presented by the referring veterinarian/sonographer. No evaluation can be communicated regarding pathology that was not visible in the image/video clips provided.

Thank you for this referral. If the clinical or image interpretation does not parallel your findings or if I can be of any further assistance, please contact me.

Eric Lindquist, DMV, DABVP(CFM), Cert. IVUSS,

CEO, Owner, Founder -- SonoPath.com

info@SonoPath.com