



**PATIENT**

Robbie Fusco

**SPECIES**

Feline

**BREED**

DSH

**SEX**

Neutered Male

**AGE**

10 Years

**WEIGHT**

Not Provided

**INTERPRETED BY**

Eric Lindquist, DMV,  
DABVP (CFM), Cert.  
IVUSS

**IMAGING PERFORMED BY**

Kerri Becker

**HOSPITAL NAME**

Vetco Total Care  
(Kinnelon)

**REFERRING VET**

Dr. Griffin

**INVOICE**

74686

**DATE**

4/22/26

**PRESENTING CLINICAL SIGNS**

HM on annual exam grade 2/6 parasternal  
Abnormal PE/Chem/CBC/UA Results: NSF

**ULTRASONOGRAPHIC EXAMINATION OF THE HEART**

| FELINE CARDIAC PARAMETERS | BODY WEIGHT (kg) | HR (BPM)                  | IVSd (cm)            | LVIDd (cm)      | LVWd (cm)       | FS (%)   | EF (%) |
|---------------------------|------------------|---------------------------|----------------------|-----------------|-----------------|----------|--------|
| NORMAL PARAMETER          | -----            | 150-240                   | 0.3-0.6              | 1.0-2.1         | 0.25-0.6        | 35-67    | 80-100 |
| PATIENT                   | NP               | 208                       | 0.36                 | 1.7             | 0.36            | 32       | 63     |
| FELINE CARDIAC PARAMETERS | LA/AO (M-mode)   | LA/AO HEART BASE (Sisson) | LAD LA MAX 4 Chamber | LVOT VEL. (m/s) | RVOT VEL. (m/s) | IVRT (m) |        |
| NORMAL PARAMETER          | <1.5             | 1.6                       | 0.7-1.7              | <1.6            | <1.3            | 40-60    |        |
| PATIENT                   | 1.1              | 1.2                       | 1.2                  | 1.5             | 0.9             | NM       |        |

Adapted from June Boon, Veterinary Echocardiography, 1998  
Sisson D et al. JVIM 1991; 5: 232, Jacobs et al. Am J Vet Res 1985; 46:1705

EPSS = 0.1

**Cardiac Presentation**

The echocardiogram in this patient demonstrated normal **left atrial** size based on 3 separate LA measurements. **Mitral** insufficiency noted at 5.5 m/sec without volume overload. The **left ventricle** presented normal thicknesses with linear contour and was not dilated nor restricted. The **myocardium** presented normal echogenicity without subjective evidence of significant fibrotic or ischemic disease. **Contractility** of the ventricular walls was adequate and in normal range for this patient evidenced by the fractional shortening measurement and subjective evaluation of the different regions and angles of the myocardium. The **left ventricular outflow** tract demonstrated normal laminar flow and subjective structural integrity. The **right atrium** and auricle revealed normal size, structure and content. No evidence of masses was noted or chamber overload. **Tricuspid** valvular assessment demonstrated adequate linear morphology and kinetics. The **right ventricle** was of normal size (1/3 diameter of LV), chordae structure, myocardial echogenicity and thickness. **Pulmonic** tract assessment revealed normal valve structure, laminar flow, and diameter (approx. 1:1 pa/ao ratio). No visible **pericardial** or free pleura fluid was noted or extra cardiac pathology in the visible planes. The cranial **mediastinum** and **pericardial regions** were free of masses in the visible window.

**ULTRASONOGRAPHIC FINDINGS**

- Normal echocardiogram with mitral insufficiency, compensated. No volume overload.

**INTERPRETATION OF THE FINDINGS & FURTHER RECOMMENDATIONS**

No treatment recommended at this time. Recheck echo in one year.



**PATIENT**

Robbie Fusco

**SPECIES**

Feline

**BREED**

DSH

**SEX**

Neutered Male

**AGE**

10 Years

**WEIGHT**

Not Provided

**INTERPRETED BY**

Eric Lindquist, DMV,  
 DABVP (CFM), Cert. IVUSS

**IMAGING PERFORMED BY**

Kerri Becker

**HOSPITAL NAME**

Vetco Total Care  
 (Kinnelon)

**REFERRING VET**

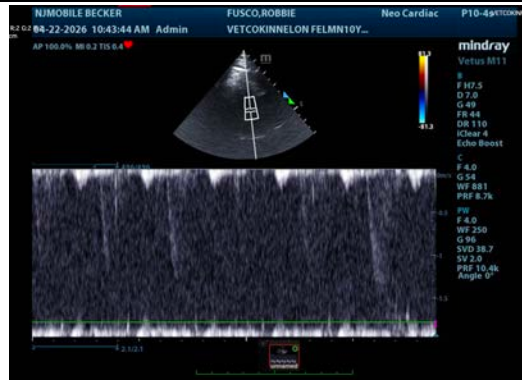
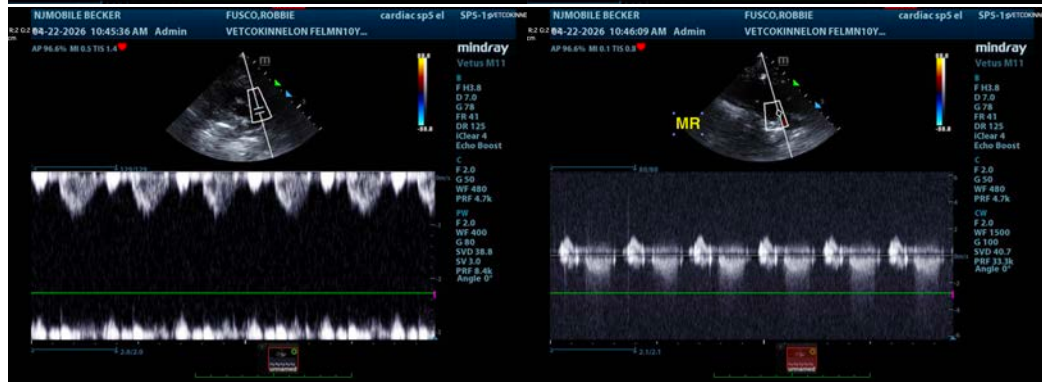
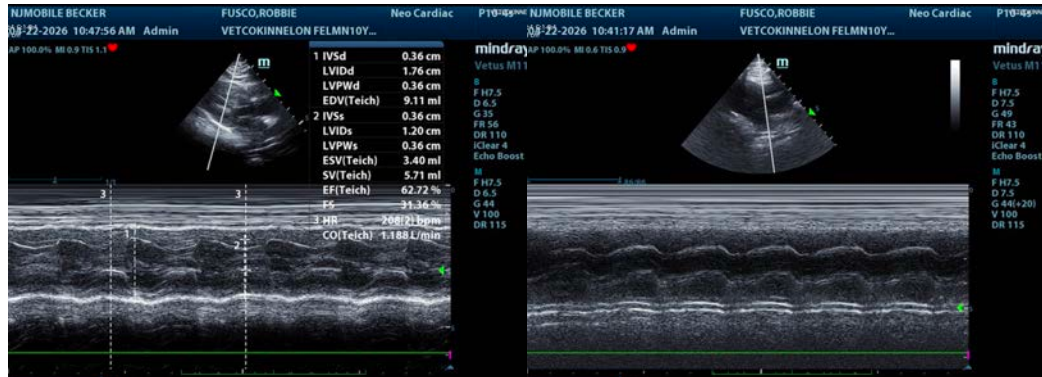
Dr. Griffin

**INVOICE**

74686

**DATE**

4/22/26



The information and recommendations provided are based on the images presented by the referring veterinarian/sonographer. No evaluation can be communicated regarding pathology that was not visible in the image/video clips provided.

Thank you for this referral. If the clinical or image interpretation does not parallel your findings or if I can be of any further assistance please contact me.

**Eric Lindquist**, DMV, DABVP(CFM), Cert. IVUSS,  
 CEO, Owner, Founder -- SonoPath.com  
[info@SonoPath.com](mailto:info@SonoPath.com)